



## EFFECT OF *HYGROPHILA SPINOSA* T. ANDERS ON ETHYLENE GLYCOL INDUCED UROLITHIASIS IN RATS

R.SATHISH\*<sup>1</sup>, K.NATARAJAN<sup>2</sup> AND MUKESH MADHAVRAO NIKHAD

Department of Pharmacology, Department of Pharmaceutical biotechnology, Ultra College of Pharmacy, Madurai  
Email: rvsathish2000@yahoo.co.in

### ABSTRACT

The antilithiatic effect of *Hygrophila spinosa* (Acanthaceae) was determined on ethylene glycol induced lithiasis in male albino rats. The lithiasis was induced to rats by oral consumption of ethylene glycolated water (0.75v/v) for 28 days. Aqueous extract of *Hygrophila spinosa* (200mg/kg) was administered orally from 1<sup>st</sup> day for preventive regimen and from 15<sup>th</sup> day for curative regimen. The urinary ionic parameters were altered by ethylene glycol, which elevated the calcium, oxalate, inorganic phosphate, protein concentration in urine. The *Hygrophila spinosa* significantly (P<0.01) reduced the elevated levels of these ions and protein in urine. Also the extract significantly (P<0.01) elevated the urinary concentration of magnesium. The elevated serum creatinine levels of lithiatic rats were reduced by prophylactic and curative regimen of extract treatment. The histological findings also showed improvement after treatment with the extract. These observations enable to conclude that the curative and preventive properties of *Hygrophila spinosa* against ethylene glycol induced urolithiasis.

**Key words:** Urolithiatic, Ethylene glycol, *Hygrophila spinosa*, Hyperoxaluria, Antilithiatic.

### INTRODUCTION

Kidney stone formation or urolithiasis is a complex process that is a consequence of an imbalance between promoters and inhibitors in the kidneys<sup>1</sup>. Even though the technological developments in the present medical practice the formation and growth of renal calculi continues to afflict humankind. Though various kinds of stone have been identified, calcium stones are the most common in human as well as rats<sup>2</sup>. Urinary stone disease is a common disorder estimated to occur in approximately 12% of the world population, with a recurrence rate of 70-81% in males and 47-60% in females<sup>3</sup>.

The recurrence of urolithiasis represents a major problem as patients who have formed one stone are more likely to form another. The standard drugs used to prevent urolithiasis are not effective in all patients, and many of them have adverse effects that compromise their long term use. The present day management of nephrolithiasis with open renal surgery is unusual and rarely used only since the introduction of Extracorporeal Shock Wave Lithotripsy (ESWL) which has almost become the standard procedure for eliminating kidney stones.

However, in addition to the traumatic effect of shockwaves, persistent residue stone fragments and the possibility of infection suggests that ESWL may cause acute renal injury, a decrease in renal function and an increase in stone recurrence<sup>4,5</sup>. Hence the search for antilithiatic drugs to be effective without side effects from natural sources has gained great potential. *Hygrophila spinosa* is an erect and woody plant from the family Acanthaceae, common throughout India, Srilanka, Burma, Malaysia and Nepal. The plant is used as demulcent, aphrodisiac, diuretic, urinary tonic and hepatoprotective substance. The aerial parts and the roots are used in herbal preparations<sup>6</sup>. A literature survey revealed that *H.spinosa* is endowed with various chemical components such as alkaloids, phytosterols, mucilage and fixed oil etc. which possibly contribute to its vast uses in folklore medicine<sup>7,8</sup>. The present study was planned to evaluate the antilithiatic activity of aqueous extract of *H. spinosa* whole plant on ethylene glycol induced calcium oxalate urolithiasis in male rats.

### MATERIALS AND METHODS

#### Plant material

The plant *Hygrophila spinosa* was collected from tanks and ponds around Madurai, Tamilnadu in September 2008. The botanical

identity was confirmed by Dr.D.Stephen, Department of Botany, American college, Madurai. A voucher specimen of the plant was deposited in Ultra college of Pharmacy, Madurai.

#### Preparation of aqueous extract

The whole plants were cleaned and chopped in to small pieces and dried under shade. The dried plant material was powdered and passed through the coarse sieve (No 10/44). This powder was macerated using distilled water for 24hrs with occasional shaking. The extract was filtered through muslin cloth then the filtrate was evaporated under reduced pressure and vacuum dried. The percentage yield of extract were found to be 9.2% and brownish in colour. The preliminary Phytochemical screening of the extract was carried out.

#### Experimental animals

Male albino rats of wistar strain weighing between 150-200gm were used, the animals were fed with commercial rat feed pellets (Amrut laboratory animal feed Ltd, Bangalore) and were given water *ad libitum*. Animals were housed in plastic cages with filter tops under controlled conditions of 12:12 light dark cycle, 50% humidity and 28 c. All animal experiments and maintenance were carried out according to the ethical guidelines suggested by the IAEC of Ultra college of pharmacy, Madurai. (Approval no. 890/ac/05/CPCSEA)

#### Pharmacological screening for anti urolithiatic activity

Animals were divided in to five groups containing six animals in each group. Group I served as normal control and received regular rat food and drinking water *ad libitum*. Ethylene glycol (0.75%) in drinking water was fed to Group II-V for induction of renal calculi till 28<sup>th</sup> day. Group II served as lithiatic control and received vehicle 1% tween 80, Group III received standard antiurolithiatic drug, cystone (750mg/kg) from 15<sup>th</sup> day till 28<sup>th</sup> day<sup>9,10</sup>. Group IV received aqueous extract *H. spinosa* (200mg/kg) from 15<sup>th</sup> day till 28<sup>th</sup> day and served as curative regimen. Group V received aqueous extract *H. spinosa* (200mg/kg) from 1<sup>st</sup> day till 28<sup>th</sup> day and served as preventive regimen. All drugs were given once daily by oral route using gastric tube. On day 28 animals of all the groups were kept in metabolic cages and urine samples were collected for 24h and analyzed for calcium, magnesium, oxalate, inorganic phosphate, protein and creatinine using standard methods<sup>2,11-14</sup>. The serum creatinine levels and urinary output volumes of all groups were also noted.

**Table1: Effect of aqueous extract of *Hygrophila spinosa* on Urinary biochemical parameters of urolithiatic rats**

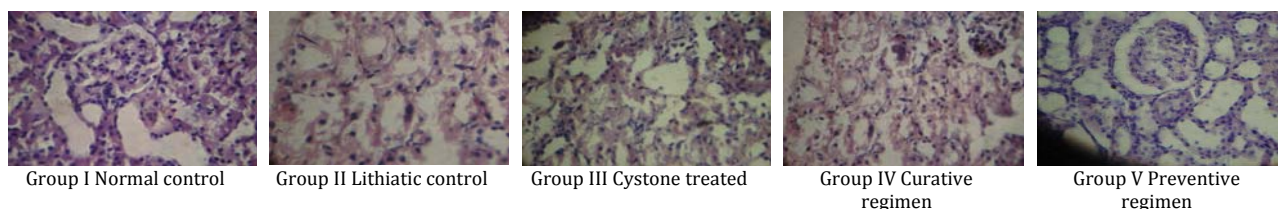
| Urinary excretion level (mg/24h)) | Treatment Groups       |                            |                           |                           |                            |
|-----------------------------------|------------------------|----------------------------|---------------------------|---------------------------|----------------------------|
|                                   | Group I Normal control | Group II Lithiatic control | Group III Cystone treated | Group IV Curative regimen | Group V Preventive regimen |
| Calcium                           | 4.9±0.37               | 10.98±0.28 <sup>a</sup>    | 5.9±0.21 <sup>**</sup>    | 6.38±0.11 <sup>**</sup>   | 5.83±0.17 <sup>**</sup>    |
| Oxalate                           | 0.46±0.05              | 2.22±0.33 <sup>a</sup>     | 0.76±0.03 <sup>**</sup>   | 0.78±0.08 <sup>**</sup>   | 0.67±0.02 <sup>**</sup>    |
| Phosphate                         | 5.9±0.13               | 11.25±0.24 <sup>a</sup>    | 7.05±0.18 <sup>**</sup>   | 7.75±0.13 <sup>**</sup>   | 7.3±0.26 <sup>**</sup>     |
| Magnesium                         | 0.96±0.01              | 0.47±0.02 <sup>a</sup>     | 0.9±0.02 <sup>**</sup>    | 0.87±0.06 <sup>**</sup>   | 0.89±0.07 <sup>**</sup>    |
| Protein                           | 3.05±0.12              | 6.84±0.15 <sup>a</sup>     | 3.65±0.21 <sup>**</sup>   | 3.87±0.06 <sup>**</sup>   | 3.29±0.25 <sup>**</sup>    |

Values are expressed as Mean±SD for six animals in each group, One way ANOVA followed by Dennett's test. <sup>\*\*</sup>- p<0.01, Values are significantly different from Lithiatic control group. <sup>a</sup>- p<0.01, Values are significantly different from Normal control group.

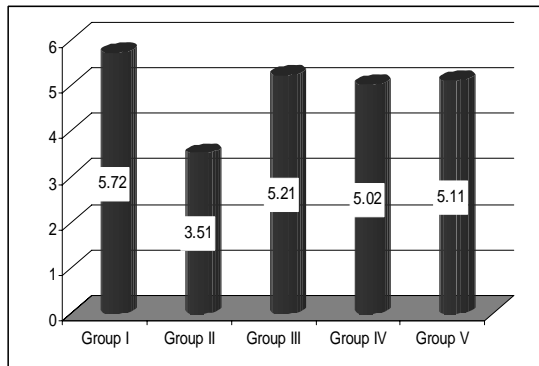
**Table 2: Effect of *Hygrophila spinosa* on urinary and serum Creatinine levels of urolithiatic rats**

| Treatment groups | Serum Creatinine (mg/dl) | Creatinine clearance (ml/min) |
|------------------|--------------------------|-------------------------------|
| Group I          | 0.57±0.01                | 0.66±0.03                     |
| Group II         | 1.94±0.2 <sup>a</sup>    | 0.04±0.001 <sup>a</sup>       |
| Group III        | 0.59±0.21 <sup>**</sup>  | 0.57±0.01 <sup>**</sup>       |
| Group IV         | 0.65±0.12 <sup>**</sup>  | 0.52±0.13 <sup>**</sup>       |
| Group V          | 0.60±0.03 <sup>**</sup>  | 0.58±0.05 <sup>**</sup>       |

Values are expressed as Mean±SD for six animals in each group, One way ANOVA followed by Dennett's test. <sup>\*\*</sup>- p<0.01, Values are significantly different from Lithiatic control group. <sup>a</sup>- p<0.01, Values are significantly different from Normal control group.



**Fig. 1: Effect of *Hygrophila spinosa* on urinary outputs of urolithiatic rats. Values are expressed as ml/24h.**



**Fig. 2: Histopathology of urolithiatic rats Kidney**

### Histopathological studies

To confirm the incidence of lithiasis, the animals were sacrificed and their kidneys were isolated and subjected to histopathological studies. The kidneys were washed, weighed and fixed rapidly with 10% neutralized formalin (pH7.4), and soaked in paraffin, cut at 5µm intervals and the slices were stained with hematoxylin and eosin. Tissue slices were photographed using optical microscopy and observed the pathological changes <sup>15</sup>.

### Statistical analysis

The results were expressed as mean±SD. Statistical analysis was performed by ANOVA test for multiple comparisons followed by Dunnett's test and P<0.05 was considered as significant.

### RESULTS

The preliminary phytochemical screening of the *H. spinosa* drug showed the presence of Alkaloids, phytosterols, mucilage and fixed

oil. The urinary output of the control and experimental rats on day 28 are shown in Fig1. The urinary volume of normal rats was 5.72±0.13 ml/day/rat whereas in the ethylene glycol alone treated rats it was statistically reduced (P<0.01) 3.51±0.11ml/day/rat. However in the extract treated curative and preventive regimen groups, the urinary outputs increased significantly (P<0.01) to 5.02±0.17 and 5.11±0.03ml/day/rat respectively. The chronic administration of 0.75%v/v ethylene glycol aqueous solution to male rats resulted in hyperoxaluria. And the calcium, Oxalate, phosphate and protein excretion were grossly increased. However, supplementation with *H.spinosa* significantly (P<0.01) lowered the elevated levels of calcium, oxalate, phosphate and protein excretion in urine of curative and preventive regimen groups.

Contrary to this, in lithiatic control group the magnesium excretion was gradually decreased following ethylene glycol treatment. Subsequent administration of the extract enhanced the magnesium

excretion significantly ( $P < 0.01$ ) in both regimens (Table 1). The creatinine clearance of lithiatic control rats were decreased, but it was improved significantly ( $P < 0.01$ ) in standard and extract treated groups. The data on serum analysis showed significant increase ( $P < 0.01$ ) in creatinine levels in lithiatic control rats when compared to normal rats. After treated with *H. spinosa*, serum creatinine levels were restored to normal limits (Table 2). Histopathological studies of kidneys clearly revealed that the tissue samples from the control group shows tubules with single epithelial lining along the margin and were of normal size. In lithiatic control, all the tubules showed the presence of crystals, there was marked dilation of the tubules and total degeneration of epithelial lining with infiltration of inflammatory cells in to the interstitial space. But kidney specimen from standard and extract treated groups showed characters similar to the normal control group (Figure2).

## DISCUSSION

It has been well documented that calculi disease affects 12% of the world population. The disease is frequently rising in the western countries, attributed to their life style and dietary habits [16]. Herbal drugs claim many promising remedies in urolithiasis. Systematic and scientific evaluation has been done only few. An attempt is made in this direction using *H. spinosa*. In the present study, male rats were selected to induce urolithiasis because the urinary system of male rats resembles that of humans [17] and also earlier studies have shown that the amount of stone deposition in female rats was significantly less [18].

Urinary super saturation with respect to stone-forming constituents is generally considered to be one of the causative factors in calculogenesis. Administration of ethylene glycol (0.75%, v/v) to young male albino rats for 14 day period forms renal calculi composed mainly of calcium oxalate. The biochemical mechanisms for this process are related to an increase in the urinary concentration of oxalate. Stone formation in ethylene glycol fed animals is caused by hyperoxaluria, which causes increased renal retention and excretion of oxalate [19].

It has been reported that the kidneys are the principle target organ for ethylene glycol toxicity and administration of ethylene glycol for more than 4 weeks resulted in insignificant urinary oxalate excretion and deposition of crystals in kidney [20], hence in our study ethylene glycol was chosen to induce lithiasis. Following the induction of lithiasis the urinary volume and composition were found to be altered. In our study also the urinary output was markedly decreased in lithiatic control rats on day 28, however in plant extract and standard treated rats the urinary volumes were increased when compared to that lithiatic Group. This suggested that extract might have mild diuretic effect. Following ethylene glycol administration the excretion of calcium, oxalate, phosphate and protein were found to be increased in lithiatic group while in standard, curative and preventive groups these levels were significantly decreased ( $P < 0.01$ ).

On contrary to this the magnesium level was decreased in lithiatic group while in standard and extract treated groups those levels were increased significantly ( $P < 0.01$ ). The serum creatinine levels of extract treated rats restored to normal limits and the creatinine clearance was also found to be improved.

The findings of the histopathological studies suggested that no microcrystalline deposition and kidney damage in the *H. spinosa* extract treated groups. All these observations enabled us to confirm the inhibitory and curative potential of *H. spinosa* on ethylene glycol-induced lithiasis. The alkaloids, phytosterols, mucilage and fixed oil in aqueous extract may be the reason for antilithiatic activity against ethylene glycol induced lithiasis. In conclusion, the plant *H. spinosa* has both prophylactic as well as curative property in urolithiasis of rats. These finding , thus prompt the necessity for further study to carry out the antilithiatic effect of *H. Spinosa* by isolation of constituents and find out the actual constituent that active against stone formation. By which more effective treatment for lithiasis with *Hygrophila spinosa* can be achieved.

## REFERENCES

- Mohammed Touhami, Amine Laroubi, Khadija Elhabazi, Farouk Loubna, Ibtissam Zrara, younes Eljahiri *et al.* Lemon juice has protective activity in a rat urolithiasis model. BMC Urol 2007; 7: 18.
- Christina AJM, Ashok K, Packialakshmi M, Tobin GC, Preethi J, Muruges N. Antilithiatic effect of *Asparagus racemosus* willd on Ethylene Glycol-Indued Lithiasis in Male Albino Wistar Rats. Methods find Experimental clinical pharmacology 2005; 27 suppl 9: 633-638
- Aroujo Viel T, Domingos CD, Da Silvamonteiro AP, Riggo Lima-Landman MT, Lapa AJ, Souccar C. Evaluation of the antiurolithiatic activity of the extract of *Costus spiralis* Roscoe in rats. Journal of Ethnopharmacology 1999; 66 suppl 2: 193-198.
- Kishimoto T, Yamamoto K, Sugimoto T, Yoshihara H, Maekawa M. Side effects of extracorporeal shock-wave exposure in patients treated by extracorporeal shock-wave lithotripsy for upper urinary tract stone. European Urology 1986; 12:308-313.
- Begun FP, Knoll CE, Gottlieb M, Lawson RK. Chronic effects of focused electrohydraulic shock-waves on renal function and hypertension. The Journal of Urology 1991; 145:635-639.
- Kurian JC. Plants that heal. Orient long man publication; 1995. p 42-60.
- Nadkarni KM. Indian Materia Medica. Popular Prakashan, Bombay, India; 1978. p 667-669.
- Kirtikar, Basu BD. Indian Medicinal plants, 2<sup>nd</sup> ed, 3: Bishen Singh Mahindra Pal Singh Publications; 1933. p 1864-1865.
- Mitra SK, Gopumadhavan G, Venkataranganna MV and Sundaram R. Effect of cystone, a herbal formulation on glycolic acid induced urolithiasis. Phytotherapy research 1998; 12: 372-374.
- Ravindra V Karadi, Navneet B Gadge, Alagawadi KR, Rudraprabhu V Savadi. Ethylene glycol induced urolithiasis in effect of *Moringa oleifera* Lam. Root -wood on rats. Journal of Ethnopharmacology 2006; 105 suppl 1: 306-311.
- Mustafa MA, Medeiros Dm. Proximate composition, mineral content and fattyacids of cat fish for different seasons and cooking methods. J Food Sci 1985; 50:585-588.
- Hodgkinson A, Williams A. An improved colorimetric procedure for urine oxalate. Clin Chim Acta 1972; 36:127-132.
- Fiske CH, Subbarow Y. The colorimetric determination of phosphorus. J Biol Chem 1925; 66:375-381.
- Lowry OH, Rosebrough NJ, Farr AL, Randall RJ. Protein measurement using Folia-cioalteau reagent. J Biol Chem 1951; 193:265-275.
- Onyenmechi Johnson Afonne, Orish Ebere orisakwe, chudi Emma Dioka, Ejeatuluchukwu OBI, Tobias Ezejiofor, Lasbery Asomugha and Ukoha. Effects of *Rinbacin* Extract on Rat Kidney. Biol Pharm. Bull 2002; 25 suppl 8: 1022-1025.
- Swathi D, Sujatha D, Bharathi K, Prasad KVSRRG, Antilithiatic activity of the aqueous extract of the roots of *Tephrosia purpurea* Linn. Pharmacognosy Magazine 2008; 4 suppl 16:206-211.
- Vermeulen CW. Experiments on causation of urinary calculi. In: Essays in Experimental Biology. University of Chicago Press, Chicago; 1962. p. 253-269.
- Prasad KVSRRG, Bharathi K, Srinivasan KK. Evaluation of *Musa paradisiaca* Linn -"Puttubale" stem juice for antilithiatic activity in albino rats. Indian Journal of Physiology and Pharmacology 1993; 37:337-341.
- Selvam P, Kalaiselvi P, Govindaraj A, Murugan VB, Sathishkumar AS. Effect of *A. lanata* leaf extract and vedippu chunnam on the urinary risk factors of calcium oxalate urolithiasis during experimental hyperoxaluria. Pharmacological Research 2001; 43:89-93.
- Schaltd L, Ivens, Karbe E, Ruhl-fehlert c, Bomhard E. subacute Oral toxicity of tetraethylene glycol and ethylene glycol administration in wistar rats. journal of experimental toxicological pathology 1998; 50:257- 65.