

## THERAPEUTIC AND CHEMOPREVENTIVE EFFECTS OF NANO CURCUMIN AGAINST DIETHYLNITROSAMINE INDUCED HEPATOCELLULAR CARCINOMA IN RATS

SHERIEN K HASSAN<sup>1</sup>, AMRIA M MOUSA<sup>1</sup>, MARIAM G ESHAK<sup>2</sup>, ABD EL RAZIK H FARRAG<sup>3</sup>,  
ABD EL FATTAH M BADAWI<sup>4</sup>

<sup>1</sup>Biochemistry Department, National Research Centre, Giza, Egypt, <sup>2</sup>Cell biology Department, National Research Centre, Giza, Egypt,

<sup>3</sup>Pathology Department, National Research Centre, Giza, Egypt, <sup>4</sup>Petrochemicals Department, Egyptian Petroleum Research Institute, Cairo, Egypt. Email: maramattia58@yahoo.com

Received: 04 Dec 2013, Revised and Accepted: 18 Apr 2014

### ABSTRACT

**Objective:** The present study is designed to investigate the preventive and therapeutic effects of nano curcumin (Nano Cur) against diethylnitrosamine (DEN) induced hepatocellular carcinoma (HCC) in rats.

**Methods:** Thirty rats were divided into five groups. Group I served as control. Group II were induced with HCC by I.P injection of DEN (200 mg/kg bw), 2 weeks later rats received (2 ml/kg bw) CCl<sub>4</sub> orally. Group III rats received Nano Cur (20 mg/kg bw) 3 days a week by gavage for 32 weeks. Group IV and V rats were received DEN and CCl<sub>4</sub> and treated with Nano Cur either simultaneously or post-treated after 16 weeks from DEN and CCl<sub>4</sub> administration.

**Results:** Administration of DEN to rats in group II significantly increased relative liver weight, serum liver function enzymes, serum sialic acid, vascular endothelial growth factor and hepatic thiobarbituric acid reactive substances this was accompanied by significant decrease in serum albumin and tissue antioxidants (GPx, GST, SOD, CAT and GSH). Nano Cur treatment significantly improved such biochemical changes especially in group IV. Also, RFLP-PCR analysis using p53 primers showed high percentage (50%) of polymorphic DNA bands in group II. Rats in group V expressed only 25% polymorphic DNA bands this percentage decreased to 20% in group IV. These biochemical and genetic observations were supported by histopathological study of liver sections.

**Conclusion:** These findings suggested that Nano Cur could be a potential compound in combating the oxidative damage of hepatic cells and eliminating DEN induced HCC with more protective rather than therapeutic action.

**Keywords:** Hepatocellular carcinoma, Therapeutic effect, Chemoprevention, Nano curcumin, Diethylnitrosamine, Antioxidant enzymes, p53 gene.

### INTRODUCTION

Hepatocellular carcinoma (HCC) is the sixth most common cancer and the third leading cause of cancer mortality worldwide [1]. Since over 80% of deaths are in developing countries, liver cancer has been a major public health problem in these parts of the world. The rate of HCC has been increasing in Egypt with a doubling in the incidence rate in the past few years [2]. The majority of HCC cases are attributable to underlying infections caused by hepatitis B and C viruses [3]. However, several other risk factors, including alcohol consumption, obesity, iron overload, environmental pollutants, as well as several dietary carcinogens, such as aflatoxins and nitrosamines, have been shown to be involved in its etiology [4]. Currently, there is no proven effective systemic chemotherapy for HCC. Considering the limited treatment and grave prognosis of liver cancer, chemoprevention has been considered to be the best strategy in lowering the current morbidity and mortality associated with this disease [5]. Diethylnitrosamine (DEN) is a well known hepatocarcinogenic agent present in tobacco smoke, ground water, cured and fried meals, cheddar cheese, alcoholic beverages, occupational settings, cosmetics, agriculture chemicals and pharmaceutical products [6, 7]. The rat model of DEN-induced HCC is considered as one of the most accepted and widely used experimental models to study hepatocarcinogenesis [8]. Human livers metabolize nitrosamines similar to that of rat liver and also exhibit considerable similarities with regard to morphology, genomic alterations and gene expression, despite their different disease etiologies [9]. DEN metabolism in the liver by cytochrome isoform 2E1 (CYP 2E1) generates reactive oxygen species (ROS) causing oxidative stress [10]. DEN, being a genotoxic carcinogen, forms alkyl DNA adducts, induces chromosomal aberrations, micronuclei and sister chromatid exchanges in the rat liver [11]. These mutations induced by DEN are responsible for the development of hepatocarcinogenesis [10].

The conventional therapy of hepatocarcinoma including chemotherapy, radiation, surgical resection and ablation gives little hope for restoration of health because of poor diagnosis and serious side effects. Therefore, developing more effective and less toxic anti-cancer agents, including natural products, is necessary to prevent or retard the process of hepatocarcinogenesis [12]. Administration of herbal antioxidants has been shown to be preventive agents against DEN induced hepatocarcinoma [10].

Curcumin (1, 7-bis (4-hydroxy-3-methoxy-phenyl)-1, 6-heptadiene-3, 5-dione; diferuloylmethane) is a hydrophobic polyphenol, yellow, natural, lipid-soluble compound extracted from the plant *Curcuma Longa* with no discernible toxicity [13]. Curcumin has been used as a dietary supplement as well as a therapeutic agent in Chinese medicine and other Asian medicines for centuries [13, 14]. Curcumin possesses diverse pharmacologic effects including anti-inflammatory, anti-oxidant, anti-proliferative, anti-carcinogenic, and anti-angiogenic activities. Accumulated experimental evidence suggests that curcumin interferes with a variety of molecular targets and processes involved in cancer [15].

Recent studies have shown that curcumin, either alone or in combination with other anticancer agents, has potent anticancer effects [16]. Curcumin exhibits anticarcinogenic effects on leukemias, lymphomas, multiple myeloma, brain cancer and melanoma as well as skin, cervix, lung, prostate, breast, ovarian, bladder, liver, gastrointestinal tract, pancreatic and colorectal epithelial cancers [17]. It is also a potent tumor-inhibitory agent with chemopreventive properties against intestinal and colon cancers [16, 18]. However, the therapeutic applications of curcumin in human are limited by its high metabolic instability as well as poor absorption and bioavailability [14]. Synthetic analogs and formulations of curcumin have been developed,

including its combination with polymeric micelles or nanoparticle-based encapsulation that exhibit greater chemical stability, systemic bioavailability and antitumoral activities than naturally occurring curcumin [19-20]. Therefore, the purpose of this study was to develop nano curcumin (Nano Cur) particles, to increase curcumin bioavailability and to investigate its therapeutic and preventive effects on DEN induced HCC in Sprague Dawley rats.

## MATERIALS AND METHODS

### Chemicals

Diethylnitrosamine (DEN), N-acetyl neuraminic acid (NANA), malonaldehyde bis (dimethyl acetal) (MDA), reduced glutathione, 5' 5' dithio-bis (2-nitrobenzoic acid) (DTNB), 1-cholro 2, 4-dinitrobenzene (CDNB), and curcumin were purchased from Sigma-Aldrich (St. Louis, USA). Nitroblue tetrazolium were obtained from Fluka (Switzerland), pyrogallol were obtained from Merck (Germany), proteinase K, RNase A, and ethidium bromide, were obtained from Roche Applied Science, (Germany). DNA marker: A 100-bp DNA ladder obtained from Invitrogen (USA). Other chemicals used were of analytical reagent grade.

### Experimental design

After 1 week on based diet the experimental animals were randomly divided into five groups, with 6 animals in each group for a study period of 32 weeks.

Group I	Control normal healthy rats.
Group II	HCC was induced in rats by I.P injection of DEN in normal saline (200 mg/kg bw), 2 weeks later rats received (2 ml/kg bw) CCl <sub>4</sub> orally at 1:1 dilution in corn oil as a promoter of carcinogenic effect. DEN and CCl <sub>4</sub> injections were repeated once again after 1 month from first DEN injection.
Group III	Rats were received Nano Cur (20 mg/kg bw) 3 days a week by gavage.
Group IV	Rats were received DEN and CCl <sub>4</sub> injections as group II and simultaneously treated with Nano Cur as group III.
Group V	Rats were post-treated with Nano Cur as group III after 16 weeks from the administration of DEN and CCl <sub>4</sub> as group II and continued untill the end of the experiment

### Blood and tissue sampling

At the termination of the experiment, rats were weighed and complete autopsies were performed after the rats had been sacrificed by decapitation under ether anesthesia. Blood was collected and centrifuged at 3000 rpm for 15 min. The resulting serum were collected and used for biochemical determinations. Liver was removed, washed in ice-cold saline then final liver weight was recorded and relative liver weight (RLW) was calculated for each rat. The liver then divided into three portions, a portion of the liver was immediately fixed in 10% formalin for histopathological analysis. Another portion was snap-frozen at -80 °C for gene expression. The remaining portion of the liver was homogenized in 0.1 M potassium phosphate buffer (pH 7.4) using Omni tissue master homogenizer in the ratio of 1:10 w/v to be used for biochemical assays.

### Biochemical analysis

Serum aspartate transaminase (AST) and alanine transaminase (ALT), were assayed using kits provided by Biorexfars, UK. Serum alkaline phosphatase (ALP) was estimated using kits supplied by Stanbio, USA, whereas serum glutamyltranspeptidase (GGT) and albumin (Alb) were measured using kits supplied by Reactivos GPL, Spain. Also serum vascular endothelial growth factor (VEGF) concentration was estimated using the enzyme-linked immunosorbent assay (ELISA) kits supplied from Koma biotech Inc, Korea. According to the instructions supplied with the commercial assay kits. Serum total sialic acid (TSA) was also estimated by periodate-resorcinol microassay as described by Surangkul *et al.* [21]. The degree of lipid peroxidation in liver was determined by measuring thiobarbituric acid reactive substances (TBARS) according to Lefèvre *et al.* method [22]. Reduced glutathione (GSH) was estimated according to the method of Beutler *et al.* [23] in part of liver homogenate, after precipitating proteins with 10% MPA. Superoxide dismutase (SOD) activity was also estimated in another

### Preparation of highly basic nano curcumin salt

To prepare curcumin nanoparticles, 1M curcumin with low solubility in water was mixed with 4M sodium bicarbonate buffer, then grinded using mechanical ball mill (350 round/Sec) for 8 hrs. The colour of curcumin changed from yellow to red as a result of the curcumin sodium salt formation. Curcumin nanoparticles were then dispersed into 50 ml of distilled water making aqueous solution which was filled in a reactor that was immersed in a water bath adjusted at 11°C. Afterwards, this reactor was placed in an ultrasound apparatus (VCX-750 commercial sonicator) and sonication was applied in continuous mode at 100 Watt in a glass reaction vessel with thin and indented bottom for uniform and more efficient energy transmission.

### Animals

Male Sprague-Dawley rats each weighing about 150–180 g, were obtained from the animal house of the National Research Center, Egypt. The animals were housed in cages at a temperature of 26-28 °C, relative humidity of 60% and 12-hr. light/dark cycle. The animals were fed with a commercial pellet diet and had access to water *ad libitum*. All the rats used in this study received proper care and handling in compliance with the institutional animal ethics committee of the National Research Centre, Egypt, registration No. 13/105.

part of the homogenate centrifuged at 10,000 rpm for 20 min at 4°C according to the method of Minami and Yoshikawa [24]. The rest of the homogenate was centrifuged at 2000 rpm for 10 min and the obtained supernatant was used to estimate glutathione peroxidase (GPx), glutathione-s-transferase (GST), and catalase according to the methods of Necheles *et al.* [25], Habis *et al.* [26] and Sinha [27] respectively.

### DNA extraction

Rats genomic DNA was extracted using phenol-chloroform according to Sambrook *et al.* [28], with some modification. Briefly, 0.2 g of liver sample was homogenized with 500 µl of extraction buffer containing 50 µL of proteinase K (10 mg/µl). The samples were incubated overnight at 55 °C with continuous shaking. After incubation, the samples were treated with 30 µl of RNase A (10 mg/µl). The mixture was left at room temperature for 15-20 min, centrifuged at 13,000 rpm for 5 min then the supernatant was transferred to a clean tube. DNA was extracted twice with phenol-chloroform-isoamyl alcohol (PCI; 25:24:1), once with chloroform-isoamyl alcohol (CI; 24:1), and then precipitated twice with ethanol at -20 °C. The dried pellet was re-suspended in 50-100 µl of Tris-EDTA and stored at -20 °C for further use. DNA concentration and purity were determined by measuring the absorbance of the diluted DNA solution at 260 nm and 280 nm. The quality of the DNA was determined using 0.8% agarose gel electrophoresis stained with ethidium bromide.

### PCR-RFLP analysis and Enzyme digestion

PCR amplification was carried out using primers of the p53 exon 8 for rats [29]. PCR amplifications were performed using an Applied Biosystems Thermal Cycler (USA) with 31 cycles of the following steps: 94 °C for 40 s, 60 °C for 1 min; preceded by initial denaturation at 95 °C for 5 min and followed by a final extension for 7 min at 72 °C. PCR reactions contained a final volume of 25 µl consisting of 18.0 µl of autoclaved distilled water, 2.5 µl of 10× PCR

buffer (10 mM Tris-HCl, pH 9.1, 50mM KCl, 0.01% Triton TM X-100, 1.5 mM MgCl<sub>2</sub>), 0.08 mM dNTP mix, 0.1 μM of forward primer and corresponding reverse primer, 1.25 U of Taq polymerase and 2 μl of cDNA template. PCR products were visualized on 2% agarose gels stained with ethidium bromide as described by Jenkins *et al.* [29]. DNA samples (5-10 mg) were digested to completion overnight at 37 °C using 100 units of MspI restriction enzyme. DNA was then electrophoresed on 2% TAE agarose gels. Details of the restriction enzyme employed in this study to detect p53 mutation, the PCR primer sequences and the amplification conditions are summarized in Table (1)

#### Histopathological investigation

Fragments of liver tissue previously fixed in 10% formalin were dehydrated in graded ethanol and embedded in paraffin. Microtome

section of 5 μm thickness were prepared from each liver sample then mounted onto glass slides and stained with hematoxylin and eosin (H&E) [30]. The slides were observed under a Leica photomicroscope.

#### Statistical analysis

All the grouped data were evaluated with SPSS/19 software. Hypothesis testing methods included one way analysis of variance (ANOVA) followed by least significant difference (LSD) test which was used to identify differences between group means. *P* values of < 0.05 were considered as the minimum level of significant.

The data were expressed as mean ± S.E with six animals in each group.

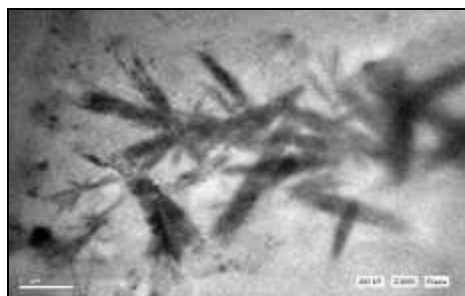
**Table 1: It Shows details of the restriction enzyme employed to detect p53 mutations, the PCR primer sequences and the amplification conditions**

p53 exon	Exon 8
Restriction enzymes	Msp I CCGG
Digestion temp. (°C)	37
Forward primer	CCTCTTGCTTCTCTTT TCCTATCC
Reverse primer	CTTGGTCTCCTCCAC CGCTTCTTG
PCR product size (bp)	262
Anneal temp. (°C)	60
Cycle number	31

## RESULTS

### Characterization of Nano Cur

Transcendental electron microscopy (TEM) of the formed nanocurcumin sodium salt revealed average particle size of 20-70 nanometer (fig.1). Basicity showed high pH = 9.5 due to the formed Nano cur sodium salt and excess of sodium bicarbonate. This high basicity has been characterized by quick solubility in water and its high penetration through cell wall.



**Fig. 1: It shows TEM image of nanocurcumin showing particles size 20-70 nanometer.**

### Effect of Nano Cur on relative liver weight

DEN treatment caused a significant increase in RLW. In DEN/CCl<sub>4</sub> treated animals, as compared to control animals. Nano Cur administration, in simultaneously or post-treated groups, led to a significant reduction in RLW in comparison to DEN/CCl<sub>4</sub> group. No obvious changes were observed between control animals and Nano Cur group (Table 2).

### Effect of Nano Cur on serum liver function

Serum liver function tests (Alb, ALP, AST, ALT and GGT) were significantly changed in all groups received DEN/CCl<sub>4</sub> as compared to control animals. Nano Cur treatment simultaneously with DEN/CCl<sub>4</sub> caused a significant decrease in the activities of ALP, AST, ALT and GGT enzymes by 37, 55, 55 and 27 % respectively, while Nano Cur post treatment caused

20,14, 7 and 23 % increase in the activities of these enzymes as compared with DEN/CCl<sub>4</sub> group. Also, Alb level significantly increased by 48 and 60 % in the liver of groups received Nano Cur simultaneously and post treated, respectively as compared to DEN/CCl<sub>4</sub> group. Nano Cur supplementation alone showed no significant changes from control group (Table 3).

### Effect of Nano Cur on GGT/ALT, TSA and VEGF as tumor indicators

DEN/CCl<sub>4</sub> group had a significant decrease in GGT/ALT by 52% and significant increase in VEGF and TSA by 50 and 26 % respectively as compared to the control animals. On the other hand Nano Cur treatment simultaneously with DEN/CCl<sub>4</sub> resulted in a complete reversal in GGT/ALT, VEGF and TSA to control levels. Nano Cur post-treatment led to significant decrease in VEGF and TSA by 30 and 13%, respectively but no significant change in GGT/ALT was observed as compared to DEN/CCl<sub>4</sub> group.

Nano Cur supplementation alone showed non-significant change from the control group (Table 4).

### Effect of Nano Cur on lipid peroxidation and antioxidant status in liver

All groups treated with DEN/CCl<sub>4</sub> had significant increase in the levels of TBARS as compared with control animals, which could be a tumor burden. Administration of Nano Cur, in simultaneously or post-treated groups, caused a significant decrease in TBARS levels by 52 and 22 % respectively, compared with DEN/CCl<sub>4</sub> group. Besides, animals treated with Nano Cur alone did not show any significant changes as compared to control animals (Table 5). DEN/CCl<sub>4</sub> treated groups exhibited a significant decrease in the activities of the antioxidant enzymes (GPx, GST, SOD and CAT) as well as reduction in GSH level as compared with control animals. Nano Cur treatment simultaneously with DEN/CCl<sub>4</sub> caused a significant increase in the activities of GPx, GST, SOD and CAT enzymes by 95, 37, 82 and 92 % respectively, while Nano Cur post treatment caused 92, 19, 64 and 75 % increase in the activities of these enzymes as compared with DEN/CCl<sub>4</sub> group. Also, GSH level significantly increased by 36 and 26 % in the liver of groups received Nano Cur simultaneously and post treated, respectively as compared to DEN/CCl<sub>4</sub> group. No adverse effect was observed in Nano Cur group (Table 5).

Table 2: It shows effect of Nano Cur on relative liver weight (RLW).

Groups	% change in RLW	RLW	Liver weight (g)
I. Control	-	2.38 ± 0.05	6.54 ± 0.22
II. DEN/CCl <sub>4</sub>	27.31	3.03 ± 0.19 <sup>a</sup>	9.17 ± 0.15
III. Nano Cur	2.00	2.31 ± 0.03 <sup>b</sup>	7.45 ± 0.27
IV. DEN + Nano Cur (simultaneously)	4.20	2.48 ± 0.03 <sup>b</sup>	7.57 ± 0.46
V. DEN+Nano Cur (post-treated)	5.88	2.52 ± 0.05 <sup>b</sup>	7.17 ± 0.21

RLW = liver weight/final body weight x100, Results are expressed as mean ± S.E. six rats in each group, <sup>a</sup> Statistical significance at  $P < 0.001$  as compared with group I, <sup>b</sup> Statistical significance at  $P < 0.001$  as compared with group II

Table 3: It shows effect of Nano Cur on serum Alb, ALP, AST, ALT, and GGT in HCC rats.

Groups	Alb (g/dl)	ALP (U/L)	AST (U/L)	ALT (U/L)	GGT (U/L)
I. Control	3.49 ± 0.23	157.02 ± 14.38	20.00 ± 1.31	25.66 ± 0.98	15.9 ± 1.03
II. DEN/CCl <sub>4</sub>	1.17 ± 0.60 <sup>a</sup>	285.68 ± 25.39 <sup>a</sup>	78.83 ± 3.50 <sup>a</sup>	77.33 ± 2.01 <sup>a</sup>	29.29 ± 1.34 <sup>a</sup>
III. Nano Cur	3.03 ± 0.09 <sup>b</sup>	170.30 ± 8.83 <sup>b</sup>	21.5 ± 1.25 <sup>b</sup>	24.50 ± 1.02 <sup>b</sup>	15.6 ± 0.94 <sup>b</sup>
IV. DEN+Nano Cur (simultaneously)	2.45 ± 0.05 <sup>a b</sup>	179.88 ± 7.36 <sup>b</sup>	35.13 ± 2.85 <sup>a b</sup>	34.83 ± 1.53 <sup>a b</sup>	21.32 ± 0.88 <sup>c b</sup>
V. DEN+Nano Cur (post-treated)	1.96 ± 0.17 <sup>a b</sup>	229.48 ± 7.70 <sup>c e</sup>	67.33 ± 3.10 <sup>a d</sup>	72.00 ± 1.82 <sup>a e</sup>	22.56 ± 1.50 <sup>a b</sup>

Results are expressed as mean ± S.E. six rats in each group, <sup>a</sup> Statistical significance at  $P < 0.001$  as compared with group I, <sup>b</sup> Statistical significance at  $P < 0.001$  as compared with group II, <sup>c</sup> Statistical significance at  $P < 0.01$  as compared with group I, <sup>d</sup> Statistical significance at  $P < 0.01$  as compared with group II, <sup>e</sup> Statistical significance at  $P < 0.05$  as compared with group II

Table 4: It shows effect of Nano Cur on serum GGT/ ALT, VEGF and TSA

Groups	GGT/ALT	VEGF (pg/ml)	TSA (µg/ml)
I. Control	0.64 ± 0.03	77.50 ± 2.14	32.28 ± 1.92
II. DEN/CCl <sub>4</sub>	0.31 ± 0.02 <sup>a</sup>	156.66 ± 13.33 <sup>a</sup>	43.83 ± 2.08 <sup>a</sup>
III. Nano Cur	0.63 ± 0.05 <sup>b</sup>	78.33 ± 2.10 <sup>b</sup>	31.6 ± 2.26 <sup>b</sup>
IV. DEN+Nano Cur (simultaneously)	0.61 ± 0.03 <sup>b</sup>	85.00 ± 4.83 <sup>b</sup>	35.87 ± 1.69 <sup>d</sup>
V. DEN+Nano Cur (post-treated)	0.37 ± 0.01 <sup>a</sup>	110.00 ± 3.65 <sup>c b</sup>	38.14 ± 1.77 <sup>e</sup>

Results are expressed as mean ± S.E. six rats in each group, <sup>a</sup> Statistical significance at  $P < 0.001$  as compared with group I, <sup>b</sup> Statistical significance at  $P < 0.001$  as compared with group II, <sup>c</sup> Statistical significance at  $P < 0.01$  as compared with group I, <sup>d</sup> Statistical significance at  $P < 0.01$  as compared with group II, <sup>e</sup> Statistical significance at  $P < 0.05$  as compared with group II

Table 5: It shows effect of Nano Cur on liver TBARS, GPx, GST, SOD, CAT and GSH.

Groups	TBARS (mole/g tissue)	GPx (µM /min/g tissue)	GST (nM/min/ml)	SOD (µg/ml)	CAT (µM /min/g tissue)	GSH (mg/g tissue)
I. Control	283.82 ± 27.55	78.37 ± 0.16	183.31 ± 13.45	156.43 ± 8.26	323.83 ± 11.99	0.30 ± 0.01
II. DEN/CCl <sub>4</sub>	712.9 ± 1.65 <sup>a</sup>	70.9 ± 0.58 <sup>a</sup>	23.00 ± 1.94 <sup>a</sup>	86.58 ± 7.77 <sup>a</sup>	203.16 ± 4.71 <sup>a</sup>	0.03 ± 0.009 <sup>a</sup>
III. Nano Cur	285.43 ± 14.00 <sup>b</sup>	77.93 ± 0.26 <sup>b</sup>	157.91 ± 10.36 <sup>b</sup>	160.00 ± 7.05 <sup>b</sup>	301.66 ± 17.96 <sup>b</sup>	0.26 ± 0.01 <sup>b</sup>
IV. DEN+Nano Cur (simultaneously)	341.9 ± 12.61 <sup>e b</sup>	75.83 ± 0.50 <sup>a b</sup>	68.88 ± 5.90 <sup>b c</sup>	128.56 ± 6.70 <sup>b c</sup>	299.66 ± 11.85 <sup>b</sup>	0.11 ± 0.004 <sup>a b</sup>
V. DEN+Nano Cur (post-treated)	555.9 ± 3.60 <sup>a b</sup>	72.62 ± 0.17 <sup>a d</sup>	35.57 ± 7.08 <sup>a</sup>	101.47 ± 2.89 <sup>a</sup>	244.33 ± 1.38 <sup>a f</sup>	0.08 ± 0.007 <sup>a d</sup>

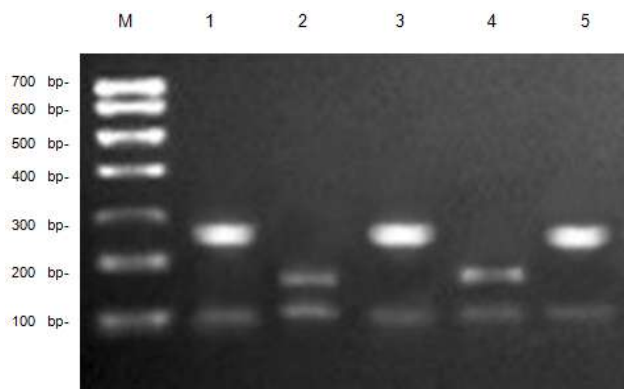
Results are expressed as mean ± S.E. six rats in each group, <sup>a</sup> Statistical significance at  $P < 0.001$  as compared with group I, <sup>b</sup> Statistical significance at  $P < 0.001$  as compared with group II, <sup>c</sup> Statistical significance at  $P < 0.01$  as compared with group I, <sup>d</sup> Statistical significance at  $P < 0.01$  as compared with group II, <sup>e</sup> Statistical significance at  $P < 0.05$  as compared with group I, <sup>f</sup> Statistical significance at  $P < 0.05$  as compared with group II

Table 6: It shows detected polymorphism using restriction marker for PCR-RFLP

Groups	Polymorphism detected at Msp I marker system			Total	Polymorphism %
	Monomorphic	Unique	Polymorphic		
I. Control	8	-	-	8	-
II. DEN/CCl <sub>4</sub>	4	3	7	14	50
III. Nano Cur	8	-	-	8	-
IV. DEN+Nano Cur (simultaneously)	7	1	2	10	20
V. DEN+Nano Cur (post-treated)	7	2	3	12	25

### Effect of Nano Cur on genotoxicity

The results revealed that the administration of DEN/CCl<sub>4</sub> group resulted in a total of 7 DNA polymorphic bands out of a total of 14 DNA bands (50%). Also there were only 4 monomorphic bands and 3 unique bands. The control and Nano Cur groups had no polymorphic bands with 8 monomorphic bands (Table 6). On the other hand, rats treated with Nano Cur simultaneously with DEN/CCl<sub>4</sub> had a total number of 10 DNA bands; two of these bands were polymorphic presenting 20% polymorphism and 1 unique band. Furthermore, Nano Cur post treated group had 12 DNA bands; three of them were polymorphic presenting 25% polymorphism and 2 unique bands (Table 6). Figure 2 indicates high polymorphic DNA bands in DEN/CCl<sub>4</sub> group. Rats treated with DEN/CCl<sub>4</sub> simultaneously with Nano Cur expressed lower polymorphic DNA bands in which this rate of polymorphism decreased further when rats post-treated with Nano Cur.



**Fig. 2:** It shows PCR-RFLP analysis of p53 gene digested by Msp I restriction enzyme. M: marker; Lane 1: control rats; lane 2: DEN group; lane 3: Nano Cur group; lane 4: DEN/CCl<sub>4</sub>+ Nano Cur (simultaneously); lane 5: DEN/CCl<sub>4</sub> + Nano Cur (post-treated).

### Effect of Nano Cur on histopathological investigation of liver sections

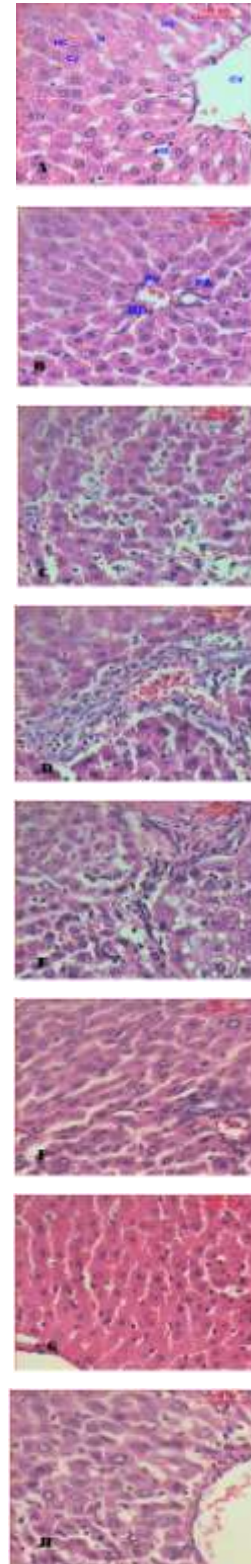
The hepatic lobules are the structural units of the liver; each is formed of cords of hepatocytes and blood sinusoids in-between. The hepatocytes are polyhedral cells with one or rarely two spherical nuclei and abundant cytoplasm. The cytoplasm of such cells is granular and strongly eosinophilic. The nuclei of the hepatocytes are large with peripherally dispersed chromatin and prominent nucleoli (Fig. 3A). The portal lobule is considered the functional units of the liver tissue. Each portal lobule is a triangular mass of liver tissue which has the portal area at its centre and is outlined by lines that connect the central veins of the three hepatic lobules which surround this portal area (Fig. 3B). In rats treated with DEN/CCl<sub>4</sub>, sections of liver showed areas of aberrant hepatocellular phenotype with variation in nuclear size, hyperchromatism, and irregular sinusoids (Fig. 3C).

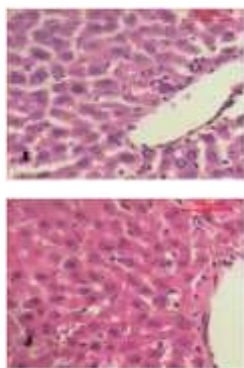
On the other hand, abnormal hepatocellular histology with prominent hyperbasophilic preneoplastic focal lesions and the presence of eosinophilic and clear cell foci were seen (Fig. 3D). Also, examination of liver of rat treated with DEN/CCl<sub>4</sub> indicated trabeculae of hepatocellular carcinoma that were consisted of highly pleomorphic tumor cells and degenerated tumor cells. These cells are characterized by eosinophilic cytoplasm, large or binucleated nuclei and prominent nucleoli. Intercellular bile canaliculi were present (Fig. 3E).

Histopathological investigation of the liver of rats treated Nano Cur simultaneously with DEN/CCl<sub>4</sub> showed the portal areas that appear more or less like the control one. The activated Kuppfer cells were noticed (Fig. 3F). On the other hand, the hepatic lobule appeared more or less like the control one (Fig. 3G). Microscopic examination of liver sections of rats post-treated with Nano Cur showed many of

the hepatocytes that appear more or less like normal and the other showed necrosis.

The dilated hepatic sinusoids that are associated with the activated Kuppfer cells were noticed (Fig. 3H). In some rats, liver appeared more or less like the control one (Fig. 3I). While, rats administered Nano Cur only, sections of their liver showed that the hepatic lobules appeared more or less like the control one (Fig. 3J).





**Fig. 3:** It shows photomicrographs (H&E stain, Scale bar: 100  $\mu\text{m}$ ) of various liver tissues from control and experimental animals. A) shows the architecture of a hepatic lobule of control rats. The central vein (CV) lies at the centre of the lobule surrounded by the hepatocytes (HC) with strongly eosinophilic granulated cytoplasm (CY), and distinct nuclei (N). Between the strands of hepatocytes the hepatic sinusoids are shown (HS), B) shows the portal tract control rats that includes portal vein (PV), portal artery (PA) and bile duct (BD), C) shows area of aberrant hepatocellular phenotype of DEN/ $\text{CCl}_4$  group with variation in nuclear size, hyperchromatism, and irregular sinusoids, D) shows abnormal hepatocellular histology of DEN/ $\text{CCl}_4$  group with prominent hyperbasophilic preneoplastic focal lesions and eosinophilic clear cell foci, E) shows trabeculae of hepatocellular carcinoma in DEN/ $\text{CCl}_4$  group consists of highly pleomorphic tumor cells and degenerated tumor cells, F) shows the portal lobules of DEN/ $\text{CCl}_4$  + simultaneous Nano Cur group that appear more or less like the control one. Notice the activated Kuppfer cells, G) shows hepatic lobule of DEN/ $\text{CCl}_4$  + simultaneous Nano Cur group resembling control one, H) shows many of the hepatocytes in DEN/ $\text{CCl}_4$  + post treated Nano Cur group appear more or less like normal and the other show necrosis, I) shows dilated hepatic sinusoids in DEN/ $\text{CCl}_4$  + post treated Nano Cur group that associated with the activated Kuppfer cells, J) shows the hepatic lobule of Nano Cur group that appear like the control one (H & E stain, Scale bar: 100  $\mu\text{m}$ ).

## DISCUSSION

Liver cancer is one of the major health problems, which have a high mortality rate for human, and its occurrence varies with respect to age, sex, invasiveness, metastatic potential, and response to prognosis of treatment [31, 32]. The limited progress achieved by cancer therapy in the last three decades has increased the interest of researchers in cancer chemoprevention [33], especially using nutraceuticals derived from nutritional sources which are naturally multitargeting, less expensive, safer and immediately available [34]. The most important types of such nutraceuticals are plant polyphenols derivatives that have been characterized in several cell culture and animal cancer models with antitumor effects [35].

Relative liver weight is an important parameter in judging the pathological condition of the liver. Therefore, lowering in the relative liver weight of rats by Nano Cur treatment is an indication of the pathological improvement of the liver, which is in agreement with Ghosh *et al.* [36]. These results were confirmed by the histopathological results.

Data presented in the current study demonstrate that DEN significantly decreased serum albumin. Vandenberghe [37] reported that, hypoalbuminemia may result from liver disorders, which are accompanied by a reduction in albumin synthesis. Cross *et al.* [38] attributed the hypoalbuminemia state to the increased rate of catabolism rather than impairment of synthesis due to the highly toxic effect of carcinogens, which leads to increase in formation of ROS. These free radicals are capable of damaging biological molecules such as proteins that have an impact on cell activities as well as membrane functions and structure. Treatment of curcumin reverted the albumin level back to normal, which reflects the well-functioning of hepatocytes in protein.

Our data also showed that DEN increased serum indices of liver function enzymes. Such elevations in the transaminases are considered as the most sensitive markers in the diagnosis of hepatocellular damage and loss of functional integrity of the membrane [39]. Ramakrishnan *et al.* [40] attributed the increases in serum aminotransferase enzyme activities to their intracellular location in the cytosol, so toxicity affecting the liver with subsequent breakdown in membrane architecture of the cells leads to their spillage into serum where their concentration rises. ALP, another key hepatic marker enzyme, its elevated activity in serum indicates pathological alterations in bile flow. Studies have shown that dividing cells shed more of ALP as they are located in the bile canalicular plasma membrane [41]. Moreover, GGT elevation reveals cholestasis and bile duct necrosis. This significant elevation of GGT in sera may be attributed to its liberation from the plasma membrane into the circulation as it is located on the outer membrane of the hepatic cells, indicating damage of the cell membrane as a result of carcinogenesis [42]. The overproduction of these enzymes in tumor cells may cause increased permeability of the cell membrane which leads to such drastic rise of enzymes in serum [43]. Fascinatingly, Nano Cur supplementation prevented the increase in such hepatic enzymes, especially in groups received Nano Cur simultaneously with DEN, suggesting that Nano Cur may have a potential protective effect against DEN-induced liver damage.

In the present study, the rate of GGT/ALT was calculated to diagnose liver cancer and it was found to be significantly lower in both group II and group V when compared to the control group, this was in accordance with Dan *et al.* [44] who reported that the rate of GGT/ALT might have a valuable role in diagnosis of primary liver cancer. On the contrary, Nano Cur treatment in group IV resulted in a complete reversal of GGT/ALT decrease to control values which is a sign of the liver improvement to normal state.

Sialic acid, a cell surface glycoconjugate, plays an important role in regulating cell proliferation and epithelial growth [45], and appears to be highly sensitive marker for the progression of tumor growth [46]. Previously, Rachesky *et al.* [47] reported an increased level of glycoproteins in animals exposed to DEN carcinogen. Data from our study revealed that DEN/ $\text{CCl}_4$  significantly increased TSA, such elevation in TSA could be due to neoplastic transformation through TSA shedding from the tumor cell surface or possibly as a product of the tumor itself [48]. Administration of Nano Cur either simultaneously or post-treated leads to significant decrease in TSA. Consequently, this suggests that Nano Cur plays an important role against DEN-induced hepatocarcinogenesis by maintaining TSA status.

Tumor angiogenesis performs a critical role in tumor progression through which the tumor establishes an independent blood supply, consequently facilitating tumor growth and favoring the transition from hyperplasia to neoplasia [49]. Researchers have found out that VEGF seems to be the most potent and predominant angiogenic cellular factor sustaining tumor growth [50]. Simultaneously, Poon *et al.* and Wills *et al.* [51, 52] reported that over expression of VEGF and its receptor VEGFR could be used widely as a biomarker for angiogenic activity in cancer. Our results show that there was over production of VEGF after administration DEN/ $\text{CCl}_4$  especially in positive control group. This is in concurrence with Torimura *et al.* [53] whom stated that VEGF was over expressed and localized around the periportal area of liver sections intoxicated with DEN. Inhibition of tumor growth by neutralization of VEGF has been verified, underlining the importance of VEGF in tumor formation [54]. In our study, quantification of growth factor VEGF indicated a decreased amount of VEGF in groups received Nano Cur either simultaneously or post treated, thereby inhibiting the formation of new blood vessel and tumor growth. This finding is in agreement with [55] who stated that curcumin treatment decreased the levels of the angiogenic biomarker VEGF in hepatocellular carcinoma cells, and resulted in a reduction in tumor neocapillary density compared to the untreated cells.

It has been suggested that the uncompromised generation of free radicals and ROS in the liver may be responsible for disturbing the antioxidant status and ultimately leading to oxidative stress and

paving the way to carcinogenesis [56]. Oxidative stress is associated with damage to a wide range of macromolecular species including lipids, proteins, and nucleic acids thereby producing major interrelated derangements of cellular metabolism including peroxidation of lipids [43]. Lipid peroxidation plays an important role in carcinogenesis [57], and may lead to the formation of several toxic products, such as MDA and 4-hydroxynonenal. These products can attack cellular targets, thereby inducing carcinogenicity [58]. Recently, the increase in lipid peroxidation was reported during DEN induced hepatocarcinogenesis [43]. In our study, all groups treated with DEN/CCl<sub>4</sub>, have a significant increase in the levels of TBARS as compared with normal group animals. The inhibition of peroxidation by curcumin is mainly attributed to the scavenging of the reactive free radicals involved in the peroxidation [59]. Animals in groups received Nano Cur either simultaneously or post-treated exhibited significantly low levels of TBARS, when compared with animals treated with DEN/CCl<sub>4</sub>. This verifies the antilipid peroxidative role of Nano Cur by its ability to scavenge free radical generation.

For the purpose of preventing cellular damage induced by ROS, there is a lot of antioxidative defense system. The anti-oxidative defense system may scavenge ROS that play an important role in the initiation of lipid peroxidation and, therefore, play a protective role in cancer development [33]. This defense system operates through enzymatic (including SOD, GPx, GST and CAT), and nonenzymatic components (mainly GSH) [12, 60]. SOD is the primary step of defense mechanism in the antioxidant system against the oxidative stress, as it dismutates the highly toxic superoxide anions (O<sub>2</sub><sup>-</sup>) to O<sub>2</sub> and H<sub>2</sub>O<sub>2</sub>. Gpx and catalase can scavenge H<sub>2</sub>O<sub>2</sub> and convert it into harmless byproducts, thereby providing protection against ROS [61]. Also, GPx has a high potency in scavenging reactive free radicals in response to oxidative stress and detoxifies peroxides and hydroperoxides that lead to the oxidation of GSH [62]. Furthermore, GST catalyzes the conjugation of the thiol functional groups of GSH to electrophilic xenobiotics, leading to elimination or conversion of xenobiotic-GSH conjugate [63]. GSH is the most important non-enzyme antioxidant in mammalian cells [64]. GSH is said to be involved in many cellular processes including the detoxification of endogenous and exogenous compounds and efficiently protects cells against deleterious effects of oxidative stress by scavenging free radicals, removing H<sub>2</sub>O<sub>2</sub>, and suppressing lipid peroxidation [65].

In the present study, the cancer bearing rats showed decreased activities of enzymatic antioxidants (SOD, CAT, GPx, and GST) and non-enzymatic antioxidants (GSH) in liver tissue in comparison with normal animals. Our data are consistent with previous findings [36, 66]. Pradeep *et al.* [67] reported that such subsequent decrease in the antioxidant defense is due to the decreased expression of these antioxidants during hepatocellular damage. On the other hand, there is a significant increase in the enzymatic and non-enzymatic antioxidant guard in the liver of the animals administered both Nano Cur and carcinogen when compared with animals administered carcinogen alone. This increase is due to the ability of curcumin to prevent the formation of free radicals, enhance the endogenous antioxidant activity beyond its free radical scavenging property and the reduction of hepatic lipoperoxide formation [68].

The p53 gene acts as a guardian of the genome and is one of the major factors controlling cell proliferation, growth suppression and transformation. Inactivation of the p53 tumor suppressor gene is a frequent event in tumorigenesis. Interestingly, mutations in the p53 gene were shown to occur at different phases of malignant transformation, thus contributing differentially to tumor initiation, promotion, aggressiveness, and metastasis [69]. Moreover, Levine *et al.* [70] stated that alterations in p53 gene seem to be critical for hepatocarcinogenesis. In the present study, administration of DEN/CCl<sub>4</sub> as a hepatocarcinogen produced a total of 14 DNA bands. These were higher than those observed in the control normal rats, in which seven bands were polymorphic presenting 50% polymorphism. According to Hilde *et al.* [69], DEN reduced p53 levels in rat liver. It has been suggested that the actual signals for p53 expression are DNA-strand breaks, induced directly by this genotoxic compound. This might explain the induction of p53 by DEN because it is clastogenic in the rat liver due to formation of

different types of DNA-adducts which have very different effects on distortion of the DNA-helix, DNA-replication and induction of gene mutations. On the other hand, our results revealed that, low mutations in the p53 gene were observed when Nano Cur was supplemented with DEN/CCl<sub>4</sub> treatment in rats particularly when taken simultaneously. This may be due to curcumin promotes *de novo* synthesis of p53 protein or some other proteins for the stabilization of p53, indicating that curcumin can induce cancer cell killing predominantly *via* p53-associated signaling pathway [16]. Moreover, Balasubramanyam *et al.* [71] previously demonstrated that curcumin could inhibit p300-specific acetylation of p53, which may be helpful in the acetylation-dependent regulation of p53 function; this causes curcumin, which targets p300 to serve as a lead compound in cancer suppression. Therefore, we can conclude that one of the curcumin pathways which play a role in cancer suppression is modulations of the transcriptional co-activating proteins mediating the p53 gene.

Changes occurring in the biochemical parameters were confirmed by the histopathological observation. The histopathological picture of the liver of rats received DEN/CCl<sub>4</sub>, showed aberrant hepatocellular phenotype with variation in nuclear size, hyperchromatism, and irregular sinusoids with prominent hyperbasophilic preneoplastic focal lesions and eosinophilic clear cell foci. Moreover, highly pleomorphic and degenerated tumor cells are also found. This agrees with Sreepriya *et al.* [72] who stated that the presence of atypical nuclei is a marker of hepatocellular carcinoma. On the other hand, animals received Nano Cur, either simultaneously or post-treated their hepatocytes, appeared with portal areas and hepatic lobules that were more or less like the control ones, indicating liver regeneration; This observations is in agreement with Ghosh *et al.* [36] who proofed that Cur maintains the normal liver cell function.

## CONCLUSION

Nano Cur appeared to be an effective free radical quencher with antioxidant activities, and capable of inhibiting oxidative stress. Also it could protect rat liver from DEN induced altered hepatic functioning, and prevent DEN induced hepatocellular carcinoma formation in rat with renovation potential of liver tissue. Given these promising findings, we suggest that nanocurcumin, which is a potentially safe and inexpensive for clinical use, may be considered as an effective chemopreventive agent against HCC with more protective rather than therapeutic action.

## REFERENCES

1. Parkin DM, Bray F, Ferlay J, Pisani P. Global cancer statistics, 2002. *CA Cancer J Clin* 2005; 55:74-105
2. Wagida A, Hussein M, Hassan A El-Nezami H, Loffredo CA. Changing pattern of hepatocellular carcinoma (HCC) and its risk factors in Egypt: Possibilities for prevention. *Mutat Res* 2008; 659: 176-184.
3. Schütte K, Bornschein J, Malfertheiner P. Hepatocellular carcinoma epidemiological trends and risk factors. *Dig Dis* 2009; 27:80-92.
4. Paraskevi A, Ronald A. Hepatocellular carcinoma pathogenesis: from genes to environment. *Nature Reviews Cancer* 2006; 6:1-14.
5. Yates MS, Kensler TW. Keap1 eye on the target: Chemoprevention of liver cancer. *Acta Pharmacologica Sinica* 2007; 28:1331-1342.
6. Sivaramkrishnan V, Shilpa PN, Kumar VR, Devaraj SN. Attenuation of N-nitrosodiethylamine-induced hepatocellular carcinogenesis by a novel flavonol-Morin. *Chem Biol Interact* 2008; 171: 79-88.
7. Gupta C, Vikram A, Tripathi DN, Ramarao P, Jena GB. Antioxidant and antimutagenic effect of quercetin against DEN induced hepatotoxicity in rat. *Phytotherapy Research* 2010; 24 Suppl 1: 119-128.
8. Hai W, Kim C, Song S, Kang C. Study on mechanism of multistep hepatotumorigenesis in rat: Development of hepatotumorigenesis. *Journal of Veterinary Science* 2001; 2: 53-58.

9. Feo F, Pascale PM, Simile MM, De Miglio MR, Muroli MR, Calvisi D. Genetic alterations in liver carcinogenesis: Implications for new preventive and therapeutic strategies. *Crit Rev Oncog* 2000; 11: 19–62.
10. Mandal AK, Das S, Mitra M, Chakrabarti RN, Chatterjee M, Das N. Vesicular flavonoid in combating diethylnitrosamine induced hepatocarcinoma in rat model. *J Exp Ther Oncol* 2008; 7: 123–133.
11. Jagadeesh MC, Sreepriya M, Bali G, Manjulakumari D. Biochemical studies on the effect of curcumin and embelin during N-nitrosodiethylamine/Phenobarbital induced-hepatocarcinogenesis in wistar rats. *African Journal of Biotechnology* 2009; 8 Suppl 18: 4618–4622.
12. Zhang C, Zeng T, Zhao X, Yu L, Zhu Z, Xie K. Protective effects of garlic oil on hepatocarcinoma induced by N-nitrosodiethylamine in rats. *International Journal of Biological Sciences* 2012; 8 Suppl 3: 363-374.
13. Aggarwal BB, Sundaram C, Malani N, Ichikawa H. Curcumin: The Indian solid gold. *Adv Exp Med Biol* 2007; 595: 1–75.
14. Itokawa H, Shi Q, Akiyama T, Morris-Natschke SL, Lee KH. Recent advances in the investigation of curcuminoids. *Chinese Medicine* 2008; 3:11
15. Hasima N, Aggarwal BB. Review Article: Cancer-linked targets modulated by curcumin. *International Journal of Biochemistry and Molecular Biology* 2012; 3 Suppl 4: 328-351.
16. Sa G, Das T. Anti cancer effects of curcumin: Cycle of life and death. *Cell Division* 2008; 3:14. 10.1186/1747-1028
17. Mimeault M, Batra SK. Potential applications of curcumin and its novel synthetic analogs and nanotechnology-based formulations in cancer prevention and therapy. *Chinese Medicine* 2011; 6:31.
18. Kwon Y, Magnuson BA. Age-related differential responses to curcumin-induced apoptosis during the initiation of colon cancer in rats. *Food Chem Toxicol* 2009; 47: 377–385.
19. Yallapu MM, Maher DM, Sundram V, Bell MC, Jaggi M, Chauhan SC. Curcumin induces chemo/radio-sensitization in ovarian cancer cells and curcumin nanoparticles inhibit ovarian cancer cell growth. *Journal of Ovarian Research* 2010; 3:11 10.1186/1757-2215.
20. Mulik RS, Monkkonen J, Juvonen RO, Mahadik KR, Paradkar AR. Transferrin mediated solid lipid nanoparticles containing curcumin: Enhanced in vitro anticancer activity by induction of apoptosis. *International Journal of Pharmaceutics* 2010; 398:190-203.
21. Surangkul D, Pothacharoen P, Suttajit M, Kongtawelert P. A periodate-resorcinol microassay for the quantitation of total sialic acid in human serum. *Bulletin of Chiang Mai Associated Medical Sciences* 2001; 40 Suppl 3: 111-118.
22. Lefèvre G, Beljean-Leymarie M, Beyerle F, Bonnefont-Rousselot D, Cristol JP, Thérond P, et al. Evaluation of lipid peroxidation by measuring thiobarbituric acid reactive substances. *Ann Biol Clin* 1998; 56 Suppl 3: 305-319.
23. Beutler E, Duron O, Kelly B. Improved method for determination of blood glutathione. *J Lab Clin Med* 1963; 61:882–888.
24. Minami M, Yoshikawa M. A simplified assay method of superoxide dismutase activity for clinical use. *Clin Chim Acta* 1979; 92:337-342.
25. Necheles TF, Boles TA, Allen DM. Erythrocyte glutathione peroxidase deficiency and hemolytic disease of the newborn infant. *J Pediatr* 1968; 72: 319-324.
26. Habig WH, Pabst MJ, Jacoby WB. The first enzymatic step in mercapturic acid formation. *J Biol Chem* 1974; 249: 7130-7139.
27. Sinha, KA. Colorimetric assay of catalase. *Anal Biochem* 1971; 47: 389-394
28. Sambrook JE, Fritsch EF, Maniatis T. editors. Analysis and cloning of eukaryotic genomic DNA. In: *Molecular cloning: a laboratory manual*. 2nd ed. New York: Cold Spring Harbor Laboratory Press. 1989. p. 9.34-9.51
29. Jenkins GJ, Doak SH, Griffiths AP, Tofazzal N, Shah V, Baxter JN, et al. Early p53 mutations in non dysplastic Barrett's tissue detected by the restriction site mutation (RSM) methodology. *Br J Cancer* 2003; 88 Suppl 8:1271-1276.
30. Bancroft J, Gamble M. Theory and practice of histological techniques. 5th ed. London: Churchill Livingstone publisher; 2001.
31. Ruddon RW editor. Characteristic of human cancer in cancer biology. London: Oxford; 1995.
32. Metwally NS, Kholeif TE, Ghanem KZ, Farrag AH, Ammar NM, Abdel-Hamid AH Z. The protective effects of fish oil and artichoke on hepatocellular carcinoma in rats. *Eur Rev Med Pharmacol Sci* 2011; 15: 1429-1444.
33. López-Lázaro M. Anticancer and carcinogenic properties of curcumin: Considerations for its clinical development as a cancer chemo preventive and chemotherapeutic agent. *Molecular Nutrition & Food Research* 2008; 52: S103 –S127.
34. Gupta SC, Kim JH, Kanappan R, Reuter S, Dougherty PM, Aggarwal BB. Role of nuclear factor- $\kappa$ B-mediated inflammatory pathways in cancer-related symptoms and their regulation by nutritional agents. *Experimental Biology and Medicine* 2011; 236: 658–671.
35. Indap MA, Barkume MS. Efficacies of plant polyphenolics on sodium butyrate induced anti-tumor activity, *Indian J Exp Biol* 2003; 41:861–864.
36. Ghosh D, Choudhury ST, Ghosh S, Mandal AK, Sarkar S, Ghosh A, et al. Nano capsulated curcumin: Oral chemopreventive formulation against diethylnitrosamine induced hepatocellular carcinoma in rat. *Chem Biol Interact* 2012; 195 Suppl 3: 206–214.
37. Vandenberghe J. Hepatotoxicology: Structure, function and toxicological pathology. In: Niesink JM, Vries J, Hollinger MA. editors. *Toxicology principles and application*. New York: CRC Press; 1996. p 669-721.
38. Cross C, Halliwell B, Borish E, Pryor W, Ames B, Saul R, et al. Oxygen radical and human diseases. *Ann Intern Med* 1987; 107 Suppl 4: 526-545
39. Plaa GL, Hewitt WR. Detection and evaluation of chemically induced liver injury. In: Wallace H. editor. *Principles and methods of toxicology*. New York: Raven Press; 1989. p399–628,
40. Ramakrishnan G, Augustine TA, Jagan S, Vinodhkumar R, Devaki T. Effect of silymarin on N-nitrosodiethylamine-induced hepatocarcinogenesis in rats. *Experimental oncology* 2007; 29: 39-44
41. Frederiks WM, Van Noorden CJ, Aronson DC, Marx F, Bosch KS, Jonges GN, et al. Quantitative changes in acid phosphatase, alkaline phosphatase and 5'-nucleotidase activity in rat liver after experimentally induced cholestasis. *Liver* 1990; 10 Suppl 3:158-166.
42. Bulle F, Mavier P, Zafrani ES, Preaux AM, Lescs MC, Siegrist S, et al. Mechanism of gamma glutamyl transpeptidase release in serum during intrahepatic and extrahepatic cholestasis in the rat: A histochemical, biochemical and molecular approach. *Hepatology* 1990; 11: 545–550.
43. Revathi R, Manju V. The effects of Umbelliferone on lipid peroxidation and antioxidant status in diethylnitrosamine induced hepatocellular carcinoma. *Journal of Acute Medicine* 2013; 3: 73-82.
44. Zhou D, Chen J, SU Q. The role of serum GGT and GGT/ALT rate in diagnosis of primary liver carcinoma. *Clinical Misdiagnosis & Mistherapy* 2004;12
45. Aranganathan S, Senthil K, Nalini N. A case control study of glycoprotein status in ovarian carcinoma. *Clin Biochem* 2005; 38: 535-539.
46. Sürer Gökmen S, Kazezoğlu C, Tabakoğlu E, Altıay G, Güngör Ö, Türe M. Serum total sialic acid levels in lung cancer patients of different histological types with and no extrapulmonary metastases. *Turkish Journal of Biochemistry* 2004; 29 Suppl 4: 262-267.
47. Rachesky MH, Hard GL, Glick MC. Membrane glycopeptides from chemically transformed cells. *Cancer Res* 1983; 43: 39–42.
48. Suresh K, Manoharan S, Panjamurthy K, Senthil N. Modifying effects of *Annona squamosa* on glycoconjugates levels in 7, 12-dimethylbenz (a) anthracene induced hamster buccal pouch carcinogenesis. *Journal of Medical Science* 2007; 7: 100-105.



49. Bergers G, Benjamin LE. Tumorigenesis and the angiogenic switch. *Nature Reviews Cancer* 2003; 3: 401-410.
50. Ferrara N, Vascular endothelial growth factor: Basic science and clinical progress. *Endocr Rev* 2004; 25: 581-611.
51. Poon RT, Ng IO, Lau C, Zhu LX, Yu WC, Lo CM, et al. Serum vascular endothelial growth factor predicts venous invasion in hepatocellular carcinoma: A prospective study. *Ann Surg* 2001; 233: 227-235.
52. Wills PJ, Suresh V, Arun M, Asha VV. Antiangiogenic effect of *Lygodium flexuosum* against N-Nitrosodiethylamine- induced hepatotoxicity in rats. *Chem Biol Interact* 2006; 164: 25-38.
53. Torimura T, Sata M, Ueno T, Kin M, Tsuji R, Suzaku K, et al. Increased expression of vascular endothelial growth factor is associated with tumor progression in hepatocellular carcinoma. *Hum Pathol* 1998; 29: 986-991.
54. Crawford Y, Ferrara N. VEGF inhibition: insights from preclinical and clinical studies. *Cell Tissue Res* 2009; 335 Suppl 1: 261-269.
55. Yoysungnoen P, Wirachwong P, Bhattarakosol P, Niimi H, Patumraj S. Effects of curcumin on tumor angiogenesis and biomarkers, COX-2 and VEGF, in hepatocellular carcinoma cell-implanted nude mice. *Clin Hemorheol Microcirc* 2006; 34:109-115.
56. Gey KF. Prospects for the prevention of free radical disease, regarding cancer and cardiovascular disease. *Br Med Bull* 1993; 49: 679-699.
57. Banakar MC, Paramasivan SK, Chattopadhyay MB, Datta S, Chakraborty P, Chatterjee M, et al. 1 $\alpha$ , 25-dihydroxyvitamin D3 prevents DNA damage and restores antioxidant enzymes in rat hepatocarcinogenesis induced by diethylnitrosamine and promoted by phenobarbital. *World Journal of Gastroenterology* 2004; 10 Suppl 9: 1268-1275.
58. de Zwart LL, Meerman JH, Commandeur JN, Vermeulen NP. Biomarkers of free radical damage applications in experimental animals and in humans. *Free Radic Biol Med* 1999; 26: 202-226.
59. Wright JS. Predicting the antioxidant activity of curcumin and curcuminoids. *Journal of Molecular Structure* 2002; 591: 207-217.
60. Chen B, Ning M, Yang G. Effect of paeonol on antioxidant and immune regulatory activity in hepatocellular carcinoma rats. *Molecules* 2012; 17: 4672-4683.
61. Vázquez-Garzón VR, Arellanes-Robledo J, García-Román R, Aparicio-Rautista DI, Villa-Treviño S. Inhibition of reactive oxygen species and pre-neoplastic lesions by quercetin through an antioxidant defense mechanism. *Free Radic Res* 2009; 43: 128-137.
62. Usunomena U, Ademuyiwa AJ, Tinuade OO, Uduenevwo FE, Martin O, Okolie NP. N-nitrosodimethylamine (NDMA), liver function enzymes, renal function parameters and oxidative stress parameters: A Review. *British Journal of Pharmacology and Toxicology* 2012; 3 Suppl 4: 165-176.
63. Rao GM, Rao CV, Pushpangadan P, Shirwaikar A. Hepatoprotective effects of rubiadin, a major constituent of *Rubia cordifolia* Linn. *Journal of Ethnopharmacology* 2006; 103: 484-490.
64. Wu G, Fang YZ, Yang S, Lupton JR, Turner ND. Glutathione metabolism and its implications for health. *J Nutr* 2004; 134:489-492.
65. Blair IA. Endogenous glutathione adducts. *Current Drug Metabolism* 2006; 7: 853-872.
66. Rajeshkumar NV, Kuttan R. Inhibition of N-nitroso diethylamine induced hepatocarcinogenesis by Picroliv. *J Exp Clin Cancer Res* 2000; 19 Suppl 4: 459-465.
67. Pradeep K, Mohen CV, Gobian K, Karthikeyan S. Silymarin modulates the oxidant-antioxidant imbalance during diethylnitrosamine induced oxidative stress in rats. *Eur J Pharmacol* 2007; 560: 110-116.
68. Bruck R, Ashkenazi M, Weiss S, Goldiner I, Shapiro H, Aeed H, et al. Prevention of liver cirrhosis in rats by curcumin. *Liver International* 2007; 27: 373-383.
69. van Gijssel HE, Maassen CB, Mulder GJ, Meerman JH. p53 protein expression by hepatocarcinogens in the rat liver and its potential role in mitoinhibition of normal hepatocytes as a mechanism of hepatic tumour promotion. *Carcinogenesis* 1997; 18 Suppl 5:1027-1033.
70. Levine Aj, Momand J, Finley C. The p53 tumor suppressor gene. *Nature* 1991; 351:453-456.
71. Balasubramanyam K, Varier RA, Altaf M, Swaminathan V, Siddappa NB, Ranga U. Curcumin, a novel p300/CREB-binding protein-specific inhibitor of acetyltransferase, represses the acetylation of histone/nonhistone proteins and histone acetyltransferase-dependent chromatin transcription. *J Biol Chem* 2004; 279 Suppl 49: 51163-51171.
72. Sreepriya M, Bali G. Effects of administration of embelin and curcumin on lipid peroxidation, hepatic glutathione antioxidant defense and hematopoietic system during N-nitrosodiethylamine/phenobarbital-induced hepatocarcinogenesis in wistar rats. *Mol Cell Biochem* 2006; 284: 49-55.