

Case Study

RARE BUT REALITY OF METHYL METHACRYLATE IN DENTISTRY- A CASE STUDY

NAVEEN B H. K R KASHINATH. MYTHRI H. NAUSHEEN HAJIRA.

Department of Prosthodontics, Sree Siddhartha Dental College, Tumkur, Karnataka, 572107, India. Department of Public Health Dentistry, Sree Siddhartha Dental College, Tumkur, Karnataka 572107, India
Email: ssdctumkur@gmail.com, drmythripcd@gmail.com

Received: 13 May 2014 Revised and Accepted: 19 Jun 2014

ABSTRACT

Acrylic resins, based on methyl methacrylate are important to the dentist and dental lab technicians especially when dealing with Prosthodontic cases.

Objective: To study a case affected by allergic dermatitis.

Method: A post graduate student of Prosthodontics affected with allergic dermatitis was tested & diagnosed to find out the etiological cause by multidisciplinary approach.

Result: Methyl methacrylate was found to be the etiological factor.

Conclusion: As monomer is known to cause Delayed Hypersensitivity Type IV reactions, it can be a occupational hazard to dentist. Hence, timely diagnosis as reporting the allergic reactions to the clinician is a lucky opportunity to find the etiologic factor to eliminate it from working and the life environment.

Keywords: Methyl methacrylate (Monomer), Contact dermatitis, Prosthodontic, Delayed hypersensitivity.

INTRODUCTION

Since the 1930s, a variety of resins have been introduced into dental treatments for the construction of dental prostheses and their efficacy has been based on physical, chemical and biological properties. However, one of the major factors limiting the use of these materials is their biocompatibility.^[1] In the last few decades, many substitutes for methyl methacrylate acrylic resin have been developed.^[2] Nevertheless, they remain one of the most widely used materials in dentistry because of their low cost, ease of use and many applications.^[3] For a dentist, dental technician and especially for a Prosthodontist, the acrylic resin is the entire world but unfortunately there are some, who are hypersensitive to methyl methacrylate (monomer) solution. The passion and dedication towards their field makes them strong enough to undergo different treatment modalities to overcome this problem. Hence, this case report describes the hypersensitivity reactions occurred due to contact of the monomer and the diagnostic tests used to determine the allergy and the treatment modalities.

Case report

A 25years, female, 1st year post graduate of Prosthodontics noticed itching and burning in hands and fingers while doing her laboratory work. Later, she developed multiple eruptions, fissuring and oedema. On consultation and during detailing the past history, the dermatologist observed no such history of allergy during her under graduation.

On examination, dermatologist revealed moderate lichenification and hyperkeratosis of the palms and the fingers, pigmented maculae with light-brown colour and clearly marked borders. On the palmer skin, several painful fissures with a depth of 2-2.5mm and marked erythematous lesions were observed (Photo 1). Anti histamines and antibiotics were prescribed in order to prevent infection and instructed to handle various materials by wearing gloves (vinyl gloves). There was a small but not constant effect by the prescribed treatment regimen & clinical signs and symptoms persisted (Photo 2). Hence, they advised to undergo various test to determine to which allergen the patient is allergic.

Investigations

A series of epicutaneous tests; patch test for the Indian standard battery antigen series allergens (Photo 3) along with different

materials with which she was in daily contact (polymer, monomer, acrylic resin, latex gloves, vinyl gloves and separating medium - Photo 4) and intradermal test for atopic reaction was carried out. The dermatologist prescribed Prednisolone 30mg (Omnacortil) for 6 days in a tapering dose for the symptomatic relief to the patient.

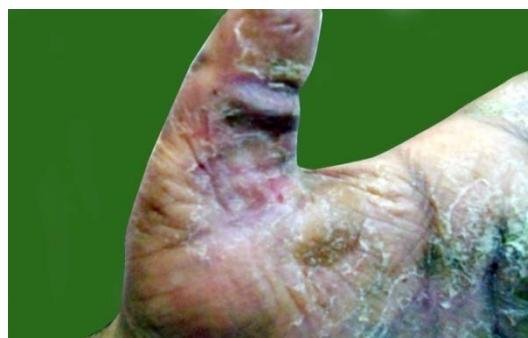

Fig. 1: Moderate lichenification, hyperkeratosis & Fissures with marked erythematous lesions of the palms.

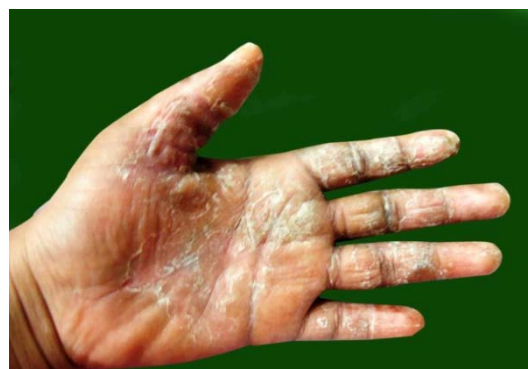

Fig. 2: Persisted symptoms after Antihistamine & Antibiotic therapy.

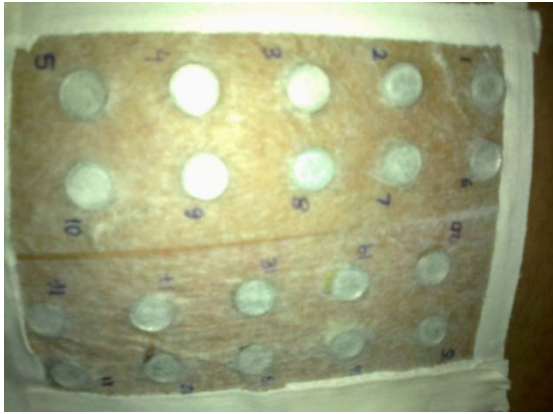


Fig. 3: Patch test for Indian standard battery antigen series & materials with which she was in daily contact

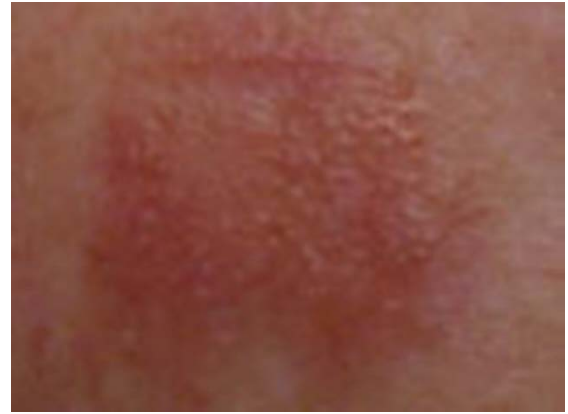

Fig. 4: Positive reaction to methyl methacrylate (Monomer) solution.

Table 1: Patch & Intra dermal test series for epicutaneous screening.

S. No.	Epidermal allergens	Patch test result at 48 th h.		Intra dermal test result.	
1	Polymer	-	negative	-	negative
2	Monomer	++	Positive	++	Positive
3	Acrylic resin	-	negative	-	negative
4	Latex gloves	-	negative	-	negative
5	Separating medium	-	negative	-	negative
6	Vinyl gloves	-	negative	-	negative

RESULTS

The patch test and intra dermal test was reviewed after 2 days and it revealed a very strong positive reaction to monomer.

Treatment modalities

The dermatologist recommended to exclude every contact with the monomer and to use non latex gloves/vinyl gloves. They prescribed intense moisturising cream (Elovera cream) for every three hours and topical application of Halobetasol propionate & Fusidic acid cream (Halovate F cream) during night time till the lesions subside. Patient was reviewed once in two weeks & prescribed the use of Immunomodulator Tacrolimus (Tacorus ointment) application for three months which was believed to reduce the recurrence of contact dermatitis. If the contact dermatitis recurs or if elimination of the cause was not practical, desensitization was recommended.

DISCUSSION

Dentists, handling acrylic resin materials and acrylic resin dentures are concerned with the sensitizing and irritating properties of these materials.^[2] Often the physician, especially dermatologist or allergist, is appealed to for aid in determining the relationship of certain symptoms and signs appearing on the skin or oral mucosa which have come in contact with acrylic resin.^[2,4] Allergy is a hypersensitive condition which is the result of exposure to a particular allergen. Re-exposure to allergen demonstrates an altered capacity of the tissue to react.^[2] Allergic reactions fall in two main categories-immediate and delayed. Acrylic resin response usually falls in delayed type of response.^[5] The dentist in present study reported with an allergic reaction to monomer with all the clinical signs & symptoms. This was similar to the findings of Alexander A F, [4] Everett T M & Carlos E [2], John LG et al [5]. The cytotoxic nature of monomer is supported by an experimental result by Zofia et al [6], Hrizdana [7] & Janaina HJ et al [8]. When a patient is hypersensitive, removal of the etiologic agent is always called for. [5] Similarly, the reported dentist was not relieved by symptomatic treatment & complete remission of symptoms was achieved only after excluding every contact with the monomer. The instructed use of glove to handle monomer didn't subside the symptoms in present study which was similar to the result of Nakamura et al. [9] And hence the patient had to undergo immunomodulator (tacrolimus ointment) treatment. It reduces itching and inflammation by suppressing the release of cytokines from T cells. [10] If the contact

dermatitis recurs even after the Immunomodulator treatment then the patient was advised to undergo the Desensitisation process. The principle behind this is that it increases the production of the beneficial IgG antibody which is then able to tie up the offending antigen before it binds to undesirable IgE antibody which creates the allergic reaction. [11]

CONCLUSION

An allergic reaction to monomer is not so rare in the dental practice. Hence, awareness of these reactions is important to the dentist especially while dealing with acrylic resins when a patient's and practitioners general health is concerned.

REFERENCES

1. Agarwal N et al. Allergy to Self-polymerized Acrylic Resin in Orthodontic Patient - A Case Report. J Ind Dent Assoc 2011;5(4):506-7.
2. Everett T. N and Carlos E del Rio. Stomatitis venenata: reaction of a patient to acrylic resin. J Prosthet Dent 1969;21(25):480-484.
3. Tatiana S, Mario A, Luis C, J. G, M, C Allergy to auto-polymerized acrylic resin in an orthodontic patient. Am Dentofacial Orthop 2006;129:431-5.
4. Alexander AF, J. Allergic sensitization of the skin and oral mucosa to acrylic resin denture materials. Dent 1956;6(5):593-602.
5. John LG, Irving G, Nevin Z, J. Allergic contact stomatitis caused by acrylic resin. Dent 1979;42(2):188-90.
6. Zofia DS, J. Experimental investigations on the cytotoxic nature of methyl methacrylate. Dent 1980;44(1):13-6.
7. Hrizdana H, Mariana D, Krasteva T. A. Petrov. Clinical case of allergic contact occupational dermatitis caused by methyl methacrylate monomer. J of IMAB 2006;12(2):35-7.
8. Janaina HJ, Eunice TG, Ana LM, J. Cytotoxicity of denture base acrylic resins: A literature review. Dent 2003;90:190-3.
9. Nakamura M, Oshima H, Hashimoto Y. Monomer permeability of disposable dental gloves. The Journal of prosthetic dentistry 2003;90(1):81-5.
10. Daniel J, William DJ. H and Allergic contact dermatitis medication. emedicinemedscapecomarticle1049085treatment Cited on 61013.
11. National occupational health and safety commission. Occupational diseases of the skin November www safe work australia govauType_of_Occurrence_Classification_S Cited on 24913 1990.