

ANTIOXIDANT AND GASTROPROTECTIVE ACTIVITY OF ETHANOLIC EXTRACT OF *C.HIRSUTUS* AGAINST PYLORIC LIGATION INDUCED GASTRIC ULCER IN ALBINO RATSD.SWATHI^{1*}, K.V.S.R.G.PRASAD², M.JALAIHAH¹, C.SRAVANTHI¹¹Scient Institute of Pharmacy, Ibrahimpatnam., Hyderabad., Andhra Pradesh., India.,² Institute of pharmaceutical technology, SPMVV. Tirupati. Email: swathi_dharma2003@yahoo.co.in

Received: 3 May 2013, Revised and Accepted: 27 May 2013

ABSTRACT

Objective: The present study was under taken to find out the efficacy of ethanolic extract of *Cocculus hirsutus* against gastric ulcer that developed due to pyloric ligation in rats. **Methods:** Five groups (n=5) of Adult Albino rats were taken. Group-I was the control group. Group-II was given standard drug omeprazole (20mg/kg). Group III and IV were given 100mg/kg (low dose) and 200mg/kg (high dose) of ethanolic extract of *Cocculus hirsutus* respectively. **Results:** The result indicated a significant reduction in the ulcer index, volume of gastric juice, free acidity and total acidity and increase in pH and protection after treatment with extract. The *in vivo antioxidant* studies were shown that the lipid peroxidation levels of the drug were decreased where as the levels of the nitrite, catalase and reduced glutathione seen to be increased. **Conclusion:** The results suggests that antioxidant and gastro protective activity of *Cocculus hirsutus*

Keywords: Pylorus ligation, Lipid peroxidation, Catlase, Nitrite, Reduced Glutathione.**INTRODUCTION**

In the digestive system, peptic ulcers denote one of the most critical disease and a social as well as medical problem of global economic importance [1], Now-a-days the risk of gastric attacks is significantly increased due to exposure of human to many noxious agents and chemicals [2], *Cocculus hirsutus* Linn (*Menispermaceae*) was known as **chilahinta** in Ayurveda and **Kattu Kodi** in Siddha system of medicine [3], *Cocculus hirsutus*, the drug under study was previously assessed to possess various pharmacological effects. These includes anti anti-inflammatory and analgesic activity [4], anti- diabetic activity[5] and immune-stimulant activity.[6] The present study was carried out in order to evaluate the gastro protective potential of the ethanol extract of *Cocculus hirsutus*.

MATERIALS AND METHODS

Plant material collection: Fresh roots of *Cocculus hirsutus* (*Menispermaceae*) was collected shade dried and powdered

Preparation of ethanolic extract of plant: Ethanolic extract was prepared by soxhalation [7]. The yield obtained was 2.6gm.

Preliminary Phytochemical screening [8]

It was performed for

- Flavonoids-Alkaline reagent test
- Saponins-Aqueous test
- Alkaloids-Dragendroff's test
- Steroids-Liebermann-Burchard test

Experimental animals

Young adults Wistar rats (150-180g) of both sexes were used for the experiment. Animals were maintained at controlled room temperature (21 ± 2°C) with free access to food and water, under a 12 hrs light/dark cycle. Twenty-four hours before the experiments, they were transferred to the laboratory and given only water, *ad libitum*. The experiments were performed after approval of the protocol by the Institutional Animal Ethical Committee (IAEC) and were carried out in accordance with the current guidelines for the care of laboratory animals.

Acute toxicity studies

Acute toxicity studies were performed according to OECD guidelines [9], and found that up to 2000mg/kg p.o route found to be safe.

In vivo antioxidant studies

The post mitochondrial supernatant (PMS) [10] was prepared which was used to assay the *in vivo* antioxidant parameters like Lipid peroxidation [11], Catalase [12], Nitrite [13] and reduced glutathione [14].

Pylorus Ligation Model

Gastric ulcers were induced by pylorus ligation model. Animals were divided in four groups (n= 5). Group I receives no treatment, serves as control, Group-II Induced rats received standard drug (Omeprazole 20mg/kg, p.o) Group-III Induced rats received low dose of ethanolic extract of *Cocculus hirsutus* (ECH-I) (100mg/kg,p.o) Group-IV rats received high dose of ethanolic extract of *Cocculus hirsutus* (ECH-II) (200mg/kg,p.o). Animals were fasted 24 hrs before to the experiment, Pyloric ligation was done by ligating the pyloric end of the stomach of rats 1 h after drug administration. 19 h later the ligated rats were sacrificed by decapitation and the abdomen was opened, content in the stomach were drained into a centrifuge tube and centrifuged at 2000 rpm, 3 min for assessing parameters like, gastric pH, total acidity and free acidity [15].

STATISTICAL ANALYSIS

All values are expressed as mean ± S.E.M. Data was analyzed by one-way ANOVA followed by Dunnett's multiple comparison test using Graph Pad PRISM software-4. P-value <0.05 was considered significant

RESULTS**Phytochemical Investigation**

The preliminary phytochemical investigation of the ethanolic extract of *Cocculus hirsutus* showed that it mainly contains tannins, flavonoids and saponins.

Pyloric Ligation Induced Ulcer Model

The ulcer index, pH, free acidity and total acidity of all experimental groups were found to be significantly increased in the pyloric ligation control group. Treatment with ethanolic extract of *Cocculus hirsutus* 200mg/kg and 100mg/kg to pyloric ligation rats showed significant ($P < 0.01$) reduction in ulcer index, free acidity, total acidity and showed significant increase ($P < 0.01$) pH.

In vivo antioxidant activity

The MDA levels were significantly increased in the control group (II)

when compared to the normal (group I) indicating the role of LPO in gastric ulcer formation. Rats treated with Omeprazole, ECH-I and ECH-II exhibited a significant decrease in MDA levels ($p < 0.01$) when compared to control group (II).

A significant decrease in the levels of catalase, nitrite and reduced glutathione was observed in the control (group II) when compared to the normal (group I). A significant increase in catalase, nitrite and reduced glutathione values was observed in groups treated with Omeprazole ($p < 0.01$) and ECH-I and ECH-II ($p < 0.01$) when compared to control group (II)

Table.1: Effect of ethanolic extract of *Cocculus hirsutus* on acidity parameters in pyloric ligation induced ulcers.

Groups	Ulcer index	Protection (%)	pH of gastric juice	Free acidity (mEq/l)	Total acidity (mEq/l)
Control	7.6 ± 2.1	-	1.4 ± 0.4	27.2 ± 3.1	47.5 ± 2.6
Omeprazole	1.6 ± 0.5*	77	6.3 ± 1.2*	12.5 ± 1.3*	24.5 ± 1.5*
ECH-I	2.4 ± 0.9*	68	4.6 ± 0.6*	14.3 ± 2.1*	27.2 ± 1.3*
ECH-II	2.0 ± 0.4*	74	5.0 ± 1.1*	13.1 ± 0.8*	25.2 ± 2.5*

All values are expressed as mean ± S.E.M. * $P < 0.01$ when compared with control group.

Table.2: Effect of Ethanolic extract of *Cocculus hirsutus* on the levels of LPO, catalase and nitrite in pyloric ligation induced ulcers.

Groups	LPO ($\mu\text{M/g}$ tissue)	Catalase ($\mu\text{M/g}$ tissue)	Nitrite ($\mu\text{M/g}$ tissue)	Reduced glutathione ($\mu\text{M/g}$ tissue)
Normal	0.03176 ± 0.0007*	6.5 ± 1.5*	47.34 ± 2.4*	0.29 ± 0.007*
Control	0.075 ± 0.003#	2.05 ± 0.6#	30.67 ± 1.4#	0.09 ± 0.008#
Omeprazole	0.048 ± 0.004*#	4.6 ± 0.7*#	42.94 ± 2*#	0.21 ± 0.01*#
ECH-I	0.057 ± 0.006*#	4.8 ± 0.52*#	38.44 ± 0.9*#	0.16 ± 0.007*#
ECH-II	0.050 ± 0.004*#	5.1 ± 0.9*#	40.85 ± 1.6*#	0.19 ± 0.008*#

All values are expressed as mean ± S.E.M. * $P < 0.01$ when compared with control group. # $P < 0.01$ when compared with normal group.

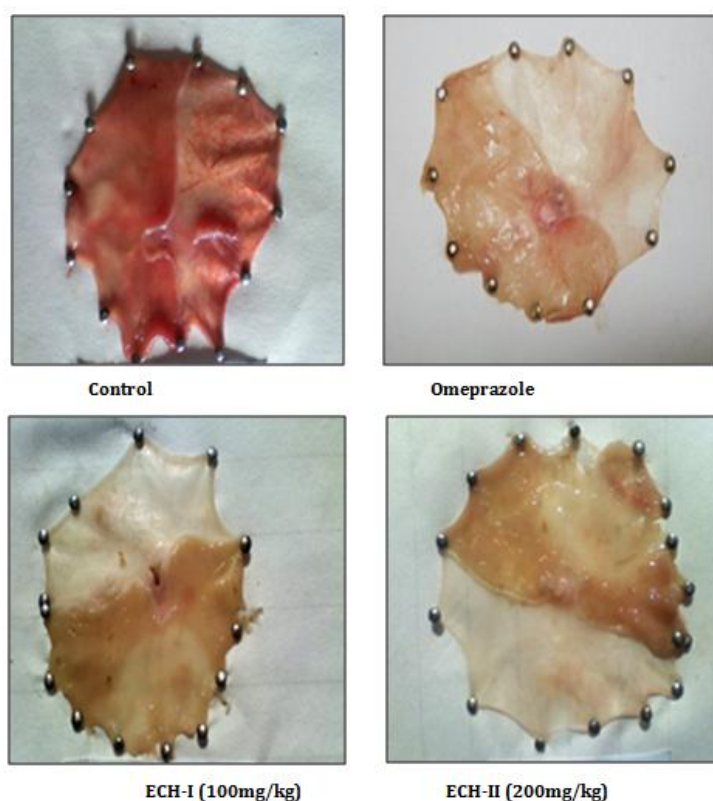


Figure: Effect of ethanolic extract of *Cocculus hirsutus* on acidity parameters in pyloric ligation induced ulcers.

Morphological examination of stomach

It has been observed that the pylorus ligated rat (control group) has shown spot ulcers, hemorrhage streak and red coloration. Rats pretreated with Omeprazole and ethanolic extract of *Cocculus*

hirsutus has not produced any haemorrhage streak but less no. of ulcer spots has been observed when compared to control rats.

DISCUSSION

In the present study, ECH have been shown to possess anti ulcer activity against experimentally induced ulcer model (Pyloric ligation Model). Ethanolic extract of *Cocculus hirsutus* significantly reduced ($P < 0.01$) the acid secretory parameters i.e. total and free acidity as well as the gastric volume and an ulcer index suggests that acid inhibition accelerates ulcer healing. The decrease in gastric volume and simultaneous decrease in acidity may be one of the reasons for the ulcer healing. Ulcers are evident by the increased levels of lipid peroxidation end products in pyloric ligation induced ulcer models. *Cocculus hirsutus* pre-treatment also reduced the extent of oxidative stress, as there was a decrease in the levels of lipid peroxidation end products. Results of this study establish a cytoprotective action of *Cocculus hirsutus* as it was found effective against pyloric ligation induced ulcers. Ulcer protection of drug may be attributed to any of these phytochemical constituents as flavonoids, tannins and saponins which have been shown to produce anti-ulcerogenic and anti-gastric activity.

CONCLUSION

Depending on experimental data it could be clearly concluded that administration of the ethanolic extract of *Cocculus hirsutus* at the dose used in this study tends to ameliorate ulcers. Reason could be the due to the presence of flavonoids. Its use in indigenous medicine should be scientifically scrutinized with further research.

REFERENCES

- Sanchez-Mendoza, M.E., Reyes-Ramírez, A., Cruz Antonio, L., Martinez Jiminez, L.,Rodríguez-Silverio, J., Arrieta, J.,: Bioassay-guided isolation of an anti-ulcer compound, tagitinin C, from *Tithonia diversifolia*: role of nitric oxide, prostaglandins and sulfhydryls. *Molecules* 2011; 16, 665-674.
- Chaturvedi.A, Kumar, M M, Bhawami.G, Chaturvedi.H, Goel: Effect of ethanolic extract of *Eugenia jambolana* seeds on gastric ulceration and secretion in rats. *Indian Journal of Physiology and Pharmacology* 2007; 51, 131.
- V.Madhavan, S.Nyoganasimhan et.al: Pharmacognostic studies on the leaves of leaves of *cocculus hirsutus*. *Indian Journal of Natural Products and Resources* 2010; Vol1 (1), pp, 38-43.
- Nayak SK, Singhai AK.:Anti-inflammatory and analgesic activity of roots of *Cocculus hirsutus*. *Indian J Nat Prod*1993; 9:12-4.
- Badole S, Patel N, Bodhankar S.: Antihyperglycemic activity of aqueous extract of leaves of *cocculus hirsutus* (L) Diels in alloxan-induced diabetic mice. *Indian J pharmacology*2006; 38:49-53.
- Bhavana R, Umesh T, Aditi Dubey, Bhavana B.: immunostimulant activity of *Cocculus hirsutus* on immunosuppressed rat. *Pharmacologyonline* 2008; 3:38-57.
- Extraction procedure: URL: 1.en.wikipedia.org/wiki/soxhaletexttractor.
- Kokate C.K.PurohitA.P.,Gokhle.S.P, : *Pharmacognosy*34th edition .Nirali Prakashan 2008;607-10
- OECD guidelines for the testing of chemicals (Acute oral toxicity up and down procedure). Adopted 23rd march2006. [Cited 2008 Jun 20]; Available from: URL: www.oecd.org
- Niehaus, W.G.Jr. and Samuelsson, B. 1968: Formation of malondialdehyde from phospholipids arachidonate during microsomal lipid peroxidation. *Eur J Biochem* 1968; 6: 126-30.
- Hugo, E.B colowick, S.P, kalpan : *Oxidoreductase acting on other than CHOH: catalase.in methods in enzymology*. London Academic Press1984; 121-25.
- Green, L.C., Wagner, D.A., Glogowski, J., Skipper, P.L., Wishnok, J.S. and Tannenbaum, S.R.: Analysis of nitrate, nitrite and [¹⁵N] nitrate in biological fluids. *Anal Biochem* 1982; 126: 131-138.
- Moran RG, Spears CP, Heidelberger C.: Biochemical determinants of tumor sensitivity to 5-fluorouracil: ultra sensitive methods for the determination of 5-fluro-2-deoxyuridylate, 2-deoxyuridylate, and thymidylate synthetase. *Proc Nati Acad* 1979; 76(3):1456-60
- Shay, H., Komarov, S.A., Fels, S.S., Meranze, D., Gruenstein, M., Siple, H., A simple method for the uniform production of gastric ulceration in the rat. *Gastroenterology* 1945; 5, 4361.