

SEVERE GASTROINTESTINAL MANIFESTATIONS COMPLICATING HENOCH-SCHÖNLEIN PURPURA IN ADULT: A RARE CASE IN INDONESIA

WILLIAM RAY CASSIDY*, KETUT SURYANA, DEWI CATUR WULANDARI

Department of Internal Medicine, Wangaya Regional General Hospital, Jalan Kartini No.133, Dauh Puri Kaja, Denpasar Utara, Dauh Puri Kaja, Denpasar Utara, Denpasar, Bali. Email: rsudwangaya.dpskota@gmail.com

Received: 04 August 2018, Revised and Accepted: 06 September 2018

ABSTRACT

Henoch-Schönlein purpura (HSP), also known as immunoglobulin A vasculitis, is a self-limiting, small vessel systemic vasculitis rarely found in adults characterized by palpable purpura, arthritis or arthralgia, gastrointestinal, and renal involvement. We report a case of a 31-year-old male with HSP complicated with severe gastrointestinal manifestations mimicking acute abdomen. He was successfully managed with conservative approach. Meticulous diagnosis, treatment, and long-term monitoring are important to reduce patient morbidity.

Keywords: Adult-onset Henoch-Schönlein Purpura, Severe bowel angina, Small vessel vasculitis.

© 2018 The Authors. Published by Innovare Academic Sciences Pvt Ltd. This is an open access article under the CC BY license (<http://creativecommons.org/licenses/by/4.0/>) DOI: <http://dx.doi.org/10.22159/ajpcr.2018.v11i11.28911>

INTRODUCTION

Henoch-Schönlein purpura (HSP) is one of the most common small vessel vasculitides in children. It is characterized by non-thrombocytopenic, leukocytoclastic vasculitis with immunoglobulin A (IgA) deposition [1]. However, HSP cases in adults are uncommon. It is also related to more severe clinical episodes and may leave long-term target organ complications in a number of patients [1,2]. This prompts a meticulous investigation and management to prevent lasting complications. Abdominal pain is a common finding in HSP with varying severity; it may be easily mistaken for an acute abdomen if the underlying cause is overlooked. We report a case of an adult-onset HSP with severe gastrointestinal symptoms successfully treated with steroid therapy.

CASE REPORT

A 31-year-old man came to internal medicine clinic with a 2-day history of rash over his legs. The lesions were small at first, increasing in size to red plaques overnight. There were no burning sensations on the skin lesion; he only felt a slight non-disturbing itch. He also experienced diffuse abdominal pain and joint pain all over his body, without any limitations to movement. There were no changes in bowel habit, he was not nauseous, urinary complaints were absent. Significant medical history was a sore throat about 1 week before the skin complaints, in which he took medications from primary health-care center (he was unable to recall the drug names). He denied any previous history of drug allergies.

On examination, he was alert with normal vital signs. There were no abnormalities in the head and neck region. Respiratory and cardiovascular physical examinations were unremarkable. The abdomen was flat on inspection, bowel sound was normal, pain after soft palpation was noticed in all quadrants without muscle guarding, and no enlargement of liver and spleen was found either. Red, palpable purpuras were seen all over his lower extremities (Fig. 1), several smaller lesions were found on his elbow as well. Joint swelling or redness was absent. A working diagnosis of HSP was established and the patient was admitted to the internal medicine ward. The patient was started on 62.5 mg of intravenous methylprednisolone every 12 h. Ceftriaxone was also administered due to suspicion on secondary infection. To ease the joint pain, intravenous paracetamol was chosen. Laboratory tests

revealed leukocytosis (white blood cells 15.590/uL) with neutrophilia, normal hemoglobin (16.5 g/dL), hematocrit (49.5%), normal platelet count (332.000/uL), hypoalbuminemia (3.0 g/dL), normal kidney function (urea 19 mg/dL, serum creatinine (0.9 mg/dL), normal alanine aminotransferase (48 U/L), and aspartate aminotransferase (32 U/L). Urinalysis result was unremarkable. Neither gross nor microscopic hematurias were seen, and proteinuria was absent. Dermatology department was consulted and topical desoximetasone + gentamycin ointment was added to therapy. Skin biopsy could not be done in our hospital due to lack of related equipment.

On the first night of admission, the patient began to feel nauseous. He started vomiting profusely on the following day. There was no blood or blood clots observed in the vomitus. 4 mg of intravenous ondansetron was administered every 8 h, in addition to intravenous esomeprazole 40 mg once daily. On the next day, the abdominal pain worsened with muscle guarding, which did not present before. He was also complaining of difficulty in defecating. Bowel movement was still audible with auscultation and no distention was seen. An urgent surgery consultation was commenced, arising suspicion of acute abdomen. Despite the patient's clinical condition, the surgeon decided not to conduct a surgical intervention. Plain abdominal radiography appeared unremarkable (Fig. 2).

Abdominal distention was observed on the 4th day. On physical examination, shifting dullness was positive. The diffuse abdominal pain did not decrease in intensity. Abdominal ultrasound examination revealed free fluid in the abdominal cavity, pelvic cavity, and McBurney area (Fig. 3). Pleural effusion was also visible, although the patient never complained of shortness of breath and his respiratory rate was always normal. Over the next 3 days, the abdominal pain resolves spontaneously without any intervention, the patient's abdomen was no longer distended, and his bowel habit returned to normal. Furthermore, the purpuric rashes became less visible (Fig. 4) and his joint pain became milder. The patient was discharged uneventfully. Oral methylprednisolone treatment was continued 8 mg twice daily, and he was scheduled for a follow-up visit to internal medicine and dermatology clinics.

DISCUSSION

HSP is a self-limiting, systemic, non-granulomatous, autoimmune complex, and small vessel vasculitis. It is associated with multiorgan

involvement [3]. Schönlein first described a syndrome of acute purpura and arthritis in children in 1837. Manifestations of colicky abdominal pain and nephritis were then added by Henoch in 1874 [4].

The exact cause of HSP is still unknown, but it is established that IgA has an important role in the pathophysiologic process [5]. Bacterial and viral infections, drugs, and autoimmune mechanisms may trigger the formation of antigen and antibody complex such as IgA. Streptococcal infection with positive antistreptolysin-O titer has been reported to hypothetically initiate the immune cascade in HSP. Only IgA1 is found in HSP. Immune complexes, including IgA deposit in small vessel walls, activate the complement pathway, leading to polymorphonuclear cells accumulation causing inflammation and vessel wall necrosis (focal fibrinoid necrosis) without granulomatous reaction, and with associated erythrocyte extravasation, consistent with a form of leukocytoclastic vasculitis. The aforementioned vasculitis is most likely responsible to the development of edema and hemorrhage [3,6]. The patient, in this case, has just recovered from upper respiratory tract infection, which might have been the trigger to HSP.

As the most common systemic vasculitis affecting children, HSP has the annual incidence of 3–26/100,000, most frequently found in children from 4 to 7 years old. In adults, the incidence of HSP is relatively rare with the annual incidence ranging from 0.1 to 1.8/100,000 individuals [5]. The self-limiting nature of HSP might also mask the true incidence rate [3]. The overall incidence of adult-onset HSP in Indonesia to this date is still unclear, most probably due to the lack of reports or underdiagnosis.

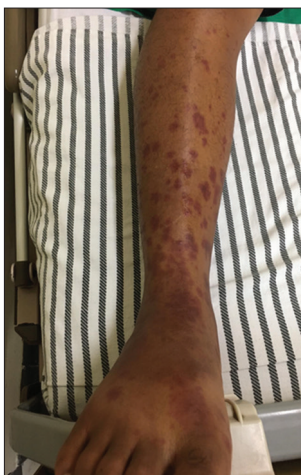

Fig. 1: The right leg showing palpable erythematous purpuras

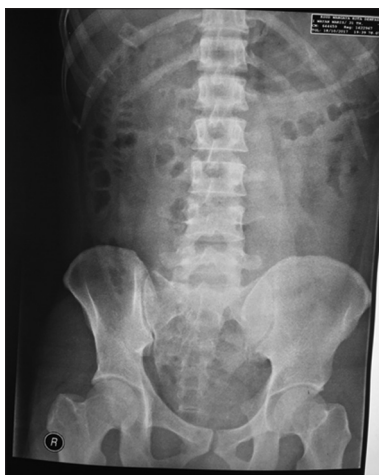

Fig. 2: Plain abdominal radiograph

HSP is classically characterized by tetrad of non-thrombocytopenic palpable purpura, arthritis or arthralgia, gastrointestinal, and renal involvement. Cutaneous manifestation is present in a majority of cases. Purpura in HSP is defined as palpable, non-blanching cutaneous hemorrhages >1 cm in diameter. The erythematous rashes usually appear in dependent areas that are subject to pressure including lower extremities, belt line, and buttocks. The arthritis is non-migratory, transient, and leaves no deformity. Abdominal pain might mimic an acute abdomen due to its severity. Vomiting and gastrointestinal bleeding are common. Occult blood may be found in the fecal examination. Intussusception may also occur, but it is uncommon.

There are no specific serologic tests to diagnose HSP. Elevated IgA level is found in the majority of cases [6-8]. Although it is not specific, serum IgA measurement may help physicians to distinguish HSP/IgA vasculitis from other forms of small vessel vasculitis such as antineutrophil cytoplasmic antibody-associated vasculitis, Churg–Strauss, and Wegener’s granulomatosis [3,9]. Serum IgA measurement was not available in our hospital; hence, the diagnosis relies heavily on patient history and clinical manifestations.

Routine urinalysis is vital in patients with HSP. Microscopic hematuria is the most sensitive finding suggestive of IgA nephropathy in the presence of vasculitis. In addition to hematuria, proteinuria is not uncommon in HSP. Renal involvements are more frequent and severe in adults compared to those in children [5,7]. HSP has been documented to occur in pregnancy. The diagnosis in this special population is challenging because the systemic signs and symptoms are similar to commonly encountered pregnancy complications such as preeclampsia. History of HSP during childhood is a major risk factor for developing hypertension and proteinuria in pregnancy [10].

In 1990, ACR proposed the first criteria to diagnose HSP derived from both clinical and histopathology findings. A patient is said to have HSP if at least two of four findings are present (Table 1), with a sensitivity of 87.1% and specificity of 87.7% [4].

Using the 2010 EULAR/PRINTO/PRES criteria shown in Table 4, a patient fulfills the diagnosis of HSP when palpable purpura is present (mandatory), in addition to either abdominal pain, histopathology showing IgA deposition, the presence of arthralgia, or evidence of renal involvement [11].

However, the 2010 EULAR/PRINTO/PRES criteria for diagnosing HSP (Table 2) have its data sourced from pediatric patients, raising concerns it might not be suitable for use in the adult population. There was a study reviewing adult patients with positively diagnosed HSP from the 2012 International Chapel Hill Consensus Conference Nomenclature of Vasculitides to match the ACR and EULAR criteria. The result was the 2010 EULAR/PRINTO/PRES criteria had a 99.2% sensitivity and 86% specificity, compared to 86.8% sensitivity and 81% specificity using the 1990 ACR criteria. The better performance of 2010 EULAR/PRINTO/PRES criteria is contributed by the addition of joint and renal involvements, which were not included in the old ACR criteria [12].

In our patient, a skin biopsy was not possible due to limitations in hospital pathologic facility, prohibiting the use of several diagnostic criteria where all require biopsy result to prove IgA deposition to distinguish the palpable purpura from other similar lesions such as drug-related hypersensitivity maculopapular eruption or ecchymosis [13-15]. This prompted the use of criteria from the 1990 American College of Rheumatology [4] criteria and the latest 2010 European League against Rheumatism/Paediatric Rheumatology International Trials Organisation/Paediatric Rheumatology European Society (EULAR/PRINTO/PRES) [11] to establish the working diagnosis of HSP in the absence of histopathology examination.

Early steroid initiation is beneficial to reduce gastrointestinal symptoms, prevent major complications, i.e., gastrointestinal bleeding or intussusception, and slow down the rate of renal progression. There

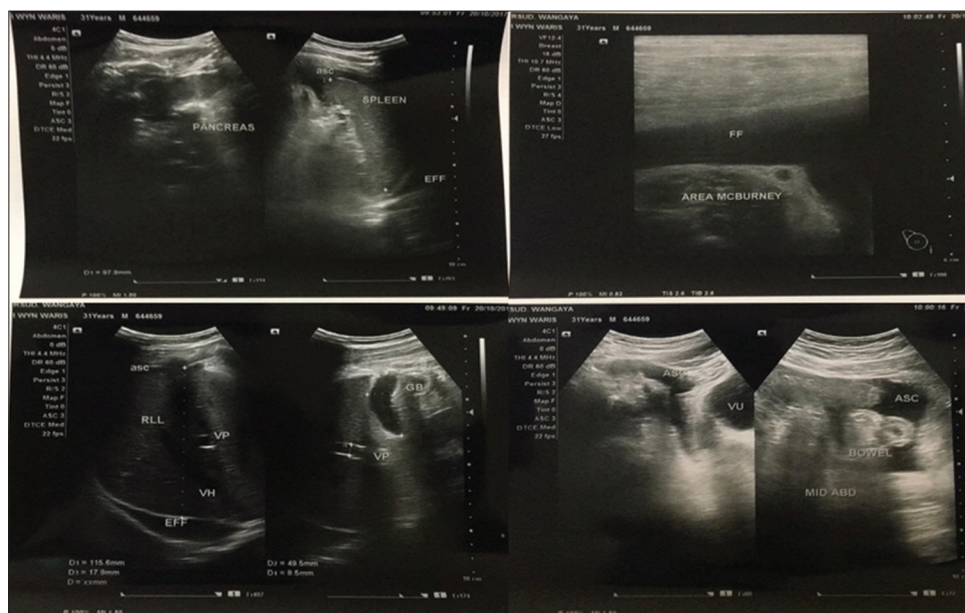


Fig. 3: Abdominal ultrasound, note the presence of free fluid in the abdominal cavity and pleural effusion

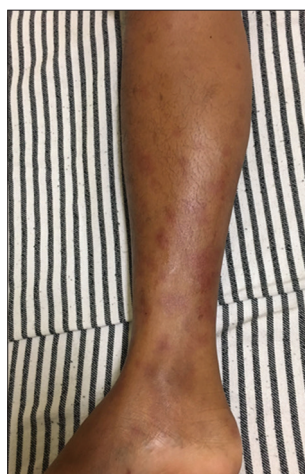

Fig. 4: Regressed palpable purpura

Table 1: ACR 1990 criteria for the classification of Henoch-Schönlein purpura [4]

Criterion	Definition
Palpable purpura	Slightly raised “palpable” hemorrhagic skin lesions, not related to thrombocytopenia
Age ≤ 20 at disease onset	Patients 20 years or younger at onset of first symptoms
Bowel angina	Diffuse abdominal pain, worse after meals, or the diagnosis of bowel ischemia, usually including bloody diarrhea
Wall granulocytes on biopsy	Histologic changes showing granulocytes in the walls of arterioles or venules

is no strict steroid dosing regimen in HSP treatment. This depends highly on the clinical manifestations of HSP and the severity of the disease. Steroid therapy is indicated in patients with severe rash, edema, severe abdominal pain, and renal involvement. Oral steroid is preferred

when tolerated, methylprednisolone 1–2 mg/kg/day for up to 2 weeks then tapered down to 0.5 mg/kg/day over 1 week, and 0.5 mg/kg every other day for another 1 week. The same principle applies to intravenous steroid where the patient is unable to tolerate oral drug form [3].

Methylprednisolone pulse has been reported in successfully treating HSP with severe gastrointestinal signs and symptoms (severe abdominal tenderness, obstipation, vomiting, and absent bowel movement) resembling intestinal ischemia [16]. A prospective trial in adults supported this evidence, where methylprednisolone pulses followed by oral prednisolone provided excellent 10-year renal survival compared to a control group [17]. There is a reported case of HSP presenting with hemorrhagic ascites and extensive bowel thickening in computed tomography scan. Complete resolution was achieved with steroid therapy, without surgical intervention [18]. Low-dose intravenous methylprednisolone demonstrated satisfactory result in this case, leading to resolution of almost all symptoms, eliminating the necessity for surgery. Fig. 5 shows a proposed treatment algorithm for managing HSP patients according to each commonly found organ system involvements [5].

Nonsteroidal anti-inflammatory drugs are generally avoided to alleviate pain in patients with renal involvement and to prevent further exaggerate gastrointestinal symptoms. Paracetamol is safe to use even in renal impairment, providing mild analgesia to reduce the arthralgia. Few studies showed that colchicine has decent efficacy in terms of reducing inflammation in patients with cutaneous leukocytoclastic vasculitis, but evidence is limited, and relapse has been reported after discontinuation of colchicine. Leukotriene receptor antagonist has been used in children population, relieving symptoms, and inhibiting relapse. At present, there is not enough evidence supporting the benefit of using azathioprine in adult patients. Other immunosuppressive drugs including cyclosporin A, mycophenolate mofetil, and cyclophosphamide have been used in combination with steroid therapy for adult patients with nephrotic range proteinuria. Remission rates were better compared to those receiving steroid alone, although the statistical power was low in some studies [5]. We decided to manage the bowel angina and arthralgia with paracetamol as it was deemed to provide mild analgesia without compromising kidney function and avoiding the risk of further gastrointestinal side effects of nonsteroidal anti-inflammatory drugs.

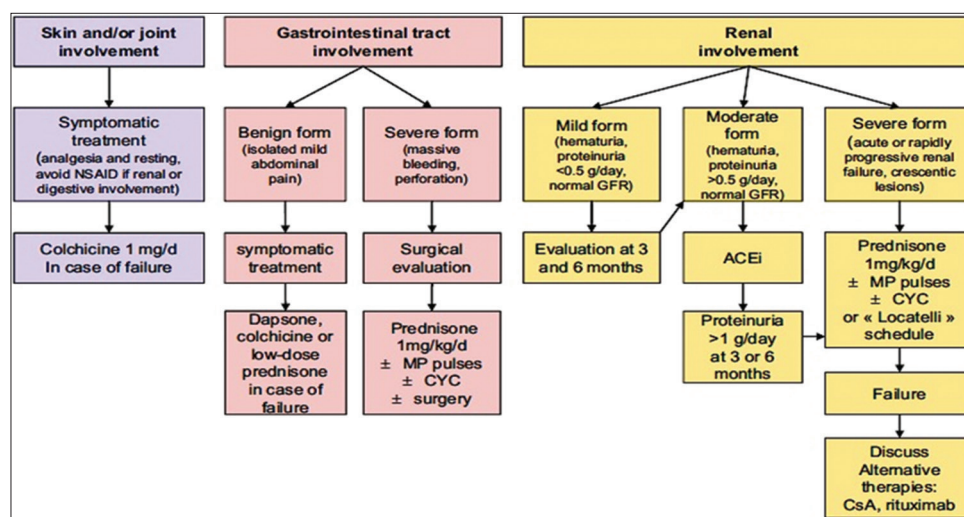


Fig. 5: Treatment algorithm for Henoch-Schönlein purpura [5]

Table 2: EULAR/PRINTO/PRES 2010 criteria for Henoch-Schönlein purpura [11]

Criterion	Glossary
Purpura (mandatory criterion)	Purpura (commonly palpable and in crops) or petechiae, with lower limb predominance, not related to thrombocytopenia
Abdominal pain	Diffuse abdominal colicky pain with acute onset assessed by history and physical examination. May include intussusception and gastrointestinal bleeding
Histopathology	Typically leukocytoclastic vasculitis with predominant IgA deposit or proliferative glomerulonephritis with predominant IgA deposit
Arthritis or arthralgias	Arthritis of acute onset defined as joint swelling or joint pain with limitation on motion Arthralgia of acute onset defined as joint pain without joint swelling or limitation on motion
Renal involvement	Proteinuria >0.3 g/24 h or >30 mmol/mg of urine albumin/creatinine ratio on a spot morning sample Hematuria or red blood cell casts: >5 red blood cells/high power field or red blood cells casts in the urinary sediment or ≥2+ on dipstick

IgA: Immunoglobulin A

Prognosis of HSP in adult is good, due to its self-limiting nature. Persistent renal damage is the most common complication in adult-onset HSP. A long-term follow-up in one study reported persistent hematuria and renal failure needing hemodialysis in adults with HSP [19]. Recurrences within the first 6 months after onset are also more frequent in patients presenting with renal involvement. On the contrary, those without evidence of renal involvement at the onset of HSP may not develop permanent renal impairment. Blood pressure measurement and urinalysis should be performed in every follow-up visit.

Our patient had no episodes of macroscopic and microscopic hematuria throughout the hospitalization period. Serum urea and creatinine levels

were within normal limits. In patients without any renal involvement such as in this case, a monthly urinalysis up to 6 months is recommended to facilitate early recognition of renal damage [7].

CONCLUSION

We report a case of a 31-year-old male presenting with palpable purpura and severe gastrointestinal symptoms diagnosed as HSP. Utilizing the 2010 EULAR/PRINTO/PRES criteria, the clinical diagnosis was established despite the lack of histopathology and serum IgA level examination. Despite the presence of free fluid within the abdominal cavity, complete resolution was achieved using intravenous steroid, without remaining abdominal symptoms, palpable purpura, arthralgia, or evidence of renal damage.

HSP is a small vessel systemic vasculitis rarely found in adults. It is a self-limiting disease and benign in nature. Nevertheless, severe cases of HSP in adults were reported from worldwide. Severe gastrointestinal manifestations mimicking surgical emergency may occur. Such event rarely requires urgent surgical intervention. Management for HSP varies from symptomatic treatments to immunosuppressive drugs. Steroid therapy was proven to be effective. Prognosis is generally good. Follow-up visits are needed, with blood pressure measurement and urinalysis every month up to 6 months to monitor recurrence and the possible evolution to renal impairment. This case serves as a reminder for physicians to increase awareness of HSP in adults. Refined documentations and/or studies on systemic vasculitis in Indonesia are highly necessary to provide better patient management.

AUTHORS' CONTRIBUTION

Dr. William Ray Cassidy as the main author is the attending Medical Officer wrote the manuscript. Dr. Dewi Catur Wulandari, the attending internal medicine specialist contributed significantly in providing guidance and reviewed the manuscript. Dr. Ketut Suryana as the Head of the Department of Internal Medicine, Allergy and Immunology Consultant supervised and reviewed the manuscript.

CONFLICTS OF INTEREST

The authors declare no conflicts of interest in preparing this article.

REFERENCES

- Hung SP, Yang Yh, Lin YT, Wang LC, Lee JH, Chiang BL. Clinical manifestations and outcomes of henoch-schonlein purpura: Comparison between adults and children. *Pediatr Neonatol* 2009;50:162-8.
- Kang Y, Park JS, Ha YJ, Kang MI, Park HJ, Lee SW, et al. Differences

- in clinical manifestations and outcomes between adult and child patients with Henoch-Schönlein purpura. *J Korean Med Sci* 2014;29:198-203.
3. Sohagia AB, Gunturu SG, Tong TR, Hertan HI. Henoch-Schonlein purpura-a case report and review of the literature. *Gastroenterol Res Pract* 2010;2010:597648.
 4. Mills JA, Michel BA, Bloch DA, Calabrese LH, Hunder GG, Arend WP, *et al.* The American college of rheumatology 1990 criteria for the classification of Henoch-Schonlein purpura. *Arthritis Rheum* 1990;33:1114-21.
 5. Audemard-Verger A, Pillebout E, Guillevin L, Thervet E, Terrier B. IgA vasculitis Henoch-Schonlein purpura in adults: Diagnostic and therapeutic aspects. *Autoimmun Rev* 2015;14:579-85.
 6. Jithpratuck W, Elshenawy Y, Saleh H, Youngberg G, Chi DS, Krishnaswamy G. The clinical implications of adult-onset Henoch-Schonlein purpura. *Clin Mol Allergy* 2011;9:9.
 7. Reamy BV, Williams PM, Lindsay TJ. Henoch-Schonlein purpura. *Am Fam Physician* 2009;80:697-704.
 8. Pillebout E, Thervet E, Hill G, Alberti C, Vanhille P, Nochy D. Henoch-Schonlein Purpura in adults: Outcome and prognostic factors. *J Am Soc Nephrol* 2002;13:1271-8.
 9. Jennette JC, Falk RJ, Bacon PA, Basu N, Cid MC, Ferrario F, *et al.* 2012 Revised international Chapel Hill consensus conference nomenclature of vasculitides. *Arthritis Rheum* 2013;65:1-11.
 10. Djakovic I, Butorac D, Vucicevic Z, Kosec V, Kuna AT, Lugović-Mihic L. Henoch-Schönlein purpura in the third trimester of pregnancy. *Biochem Med* 2018;28:010801.
 11. Ozen S, Pistorio A, Iusan SM, Bakkaloglu A, Herlin T, Brik R, *et al.* EULAR/PRINTO/PRES criteria for Henoch-Schonlein purpura, childhood polyarteritis nodosa, childhood Wegener granulomatosis and childhood Takayasu arteritis: Ankara 2008. Part II: Final classification criteria. *Ann Rheum Dis*. 2010;69:798-806.
 12. Hočevcar A, Rotar Z, Jurčić V, Pižem J, Čučnik S, Vizjak A, *et al.* IgA vasculitis in adults: The performance of the EULAR/PRINTO/PRES classification criteria in adults. *Arthritis Res Ther* 2016;18:58.
 13. Yang YH, Yu H, Chiang B. The diagnosis and classification of Henoch-Schönlein purpura: An updated review. *Autoimmun Rev* 2014;13:355-8.
 14. Joshisree KP, Rajesh G, Siddarama R. Corticosteroids induced ecchymosis. *Int J Pharm Pharma Sci* 2018;10:211-3.
 15. Lakshmi R, Liniya S, Vijayalakshmi S. Dapsone Induced hypersensitivity syndrome-a case report. *Int J Pharm Pharma Sci* 2015;7:585-7.
 16. Sharma A, Wanchu A, Kalra N, Singh S, Bambery P. Successful treatment of severe gastrointestinal involvement in adult-onset Henoch-Schonlein purpura. *Singapore Med J* 2007, 48:1047-50.
 17. Pozzi C, Andrulli S, Del Vecchio L, Melis P, Fogazzi GB, Altieri P, *et al.* Corticosteroid effectiveness in IgA nephropathy: Long-term results of a randomized, controlled trial. *J Am Soc Nephrol* 2004;15:157-63.
 18. Lee BM, Jung HC, Bang SJ, Suh HS, Choi SW. A Case of Henoch-Schönlein Purpura complicated by hemorrhagic ascites. *J Korean Rheum Assoc* 2004;11:417-21.
 19. García-Porrúa C, Calviño MC, Llorca J, Couselo JM, González-Gay MA, *et al.* Henoch-Schönlein purpura in children and adults: Clinical differences in a defined population. *Semin Arthritis Rheum* 2002;32:149-56.