

EPIDEMIOLOGY, PATHOLOGY, TYPES AND DIAGNOSIS OF SOFT TISSUE SARCOMA: A RESEARCH REVIEW

RAJANYA BANERJEE, DEBASMITA BANDOPADHYAY AND V.G.ABILASH*

Division of Biomolecules and Genetics, School of Bio Sciences and Technology VIT University, Vellore, Tamil Nadu, India
 Email: abilashvg@gmail.com

Received: 18 May 2013, Revised and Accepted: 16 June 2013

ABSTRACT

A sarcoma is a type of cancer disease which develops from certain tissues, like bone or muscle. The main types of sarcoma are: osteosarcoma and soft tissue sarcoma. Osteosarcoma which develops from bone and soft tissue sarcomas can develop from soft tissues like fat, muscle, nerves, fibrous tissues, blood vessels, or deep skin tissues. This article presents the overall information about the soft tissue sarcoma. Soft tissue sarcoma is an exceptional form of cancer which affects the adjoining body areas such as muscles, fat, fibrous tissue, blood vessels or else other supporting tissue of the body. Along with connective tissues many other parts of the body get mainly affected in this sarcoma, and when these parts get affected, they start dividing randomly and henceforth, create a lump. This lump exceeds in the shape due to internal pressure and causes a disruption in the neighboring organs of the body. It is a very rare cancer. About 1% among adult and 15% among the children is affected in this soft tissue sarcoma. Various types of genes are also present in inducing the soft tissue sarcomas are retinoblastoma protein 1(RB1); N-RAS; cyclic AMP dependent kinase number 2(CDKN2); protein 53 or tumor protein 53 (p53); Mouse double minute 2 homolog (MDM2). For detection mainly biopsy, CT scan or MRI is done and to pursue the treatment surgery, chemotherapy, radiation is given which may increase the survival rate of the patients.

Keywords: Soft tissue sarcoma, osteosarcoma, Cancer, Tissue, Muscle

INTRODUCTION

Soft tissue sarcoma (STS) is a family of rare tumors that can occur anywhere in the soft tissues of the body — fat, muscle, connective tissue, and nerves. Sarcomas can start anywhere in the body. Typically, they develop in the soft tissues that surround, connect or support the body's structure and organs. STS are uncommon tumours that present notable difficulties of diagnosis and classification. Some soft-tissue sarcomas are benign (not cancer), and others are malignant (cancer). There are more than 30 types of sarcoma, making each extremely rare. Sarcomas are classified into groups that have similar types of cancer cells and symptoms. They usually are named for the type of tissue where they start. Sarcomas within a classification often are treated the same way. Soft tissue sarcomas make up 1percent of all cancer types and have been estimated to occur approximately 30 cases among every one million people. Studies have connected soft tissue sarcomas to exposure certain chemicals, high-dose radiation, and certain viral infections, and to specific genetic abnormalities. In most cases, the cause is unknown. Assigning a pathologic type or grade to an individual sarcoma as a means of predicting clinical behaviour is often difficult, with a 40% discordance rate even between expert sarcoma pathologists[1]. However, in recent years, genetic analyses of soft tissue sarcomas have provided a vast amount of new information. Cytogenetic and karyotyping analysis has revealed a number of specific aberrations in certain sub-types which have proved to be of use in diagnosis and in targeting treatment. In the case of synovial sarcoma, an t(X;18) translocation from which the involved genes have been identified is almost always present and can be used to directly assist in diagnosis[2]. Soft tissue sarcomas (STS) exhibit heterogeneity in their clinical behavior, even within the same histological subtypes. This heterogeneity is an important problem in the treatment of patients with STS. Gene expression is felt to play a critical role in cell development and malignant transformation, and gene expression profiles are of potential use in the classification and diagnosis of malignancies [3-5]. Several recent studies have found distinctive gene expression patterns that can differentiate between histologic subtypes of STS [6-7].

Epidemiology

Soft tissue sarcoma is much prevalent in children rather than adults. It spreads in the whole body rather than affecting the small area and appears as small painless lump which further start growing in size. A diverse group of tumor that can be benign or malignant. Malignant soft tissue tumors grow in an uncontrolled manner and can invade adjacent tissue and metastasis around the body. It can occur at any age with different symptoms and mainly affect the lower lymph. Benign tumor cannot spread to other parts of body but, they grow continuously at the original site and thus, cause an obstruction for the surrounding organs. The maximum affected parts are given in Table1 below.

Table1: Soft Tissue Sarcoma affected site in the body

Region	% Affected
Upper extreme	10%
Head and neck	15%
Chest wall	15%
Membrane that lines the peritoneum and the wall	15%
Lower extreme	45%

Soft tissue sarcoma is able to be cured as per the early diagnosis is concerned. Relatively 5 years of survival is possible for the sarcoma affected patients but unfortunately very low percentage of patient can enjoy their lives more than 5 years (refer: Table 2). Unluckily there is a chance of recurrence of the soft tissue sarcoma in the first two years of the treatment for 70% of patients. In 2006, about 9,500 new cases were diagnosed in the United States[8].

Pathology of soft tissue sarcoma:

Soft tissue sarcoma basically arises due to the random development of the cells in the joint areas and tissue parts which affects the neighboring organs of the affected area. Soft tissue sarcoma occurs in different parts of the body and henceforth, different names are designated according to the affected parts. Various types of soft tissue sarcoma is found, which evolves in different parts of the body and they are as:

Table2: Survival rate for different stages in Soft Tissue Sarcoma

Sites and Stages	Survival rate (observed for 5 years)
Localized or primary site	83%
Regional site (nearby lymph node)	54%
Distant site	16%
1 st stage	90%
2 nd stage	81%
3 rd stage	56%

Fibrosarcoma (grow in fibrous body tissue) – Fibrosarcoma is cancerous and it mainly occurs in the connective tissue i.e., at the end of the bone of arms and legs. Thus, mainly it affects the arms and lower part of the leg. It also occurs around scars, muscles, nerves, tendons, bone lining. It can also invade local tissue and spread among bloodstream and lungs. Fibrosarcoma are generally divided into two categories:

- **Infantile or congenital fibrosarcoma:** This sarcoma is mainly found in the children below 1 year age. It grows up very slowly and tends to be benign than the affected older children.
- **Adult form fibrosarcoma:** It occurs in older children and in adolescence. It is very aggressive and its treatment is very complex.

It mainly occurs due genetic alterations. Surgery is done and also limb-sparing is done instead of amputation. Radiation is not mainly used in this sarcoma as it may affect the bone growth. Chemotherapy is provided to the patients. MRI and bone scanning techniques is also performed to the fibrosarcoma patients. To be noted, this fibrosarcoma is a rare bone tumor in dogs, and for cat it is the most common vaccine associated sarcoma[9].

Leiomyosarcoma and Rhabdomyosarcoma (starts in muscle)- Leiomyosarcoma-The cancer tumor in smooth tissue muscle in which brain doesn't have control such as muscles in the walls of blood vessels, the uterus or the gastrointestinal tract and uterus [10]. This type of sarcoma basically occurs among 60 years aged group person. The children are much affected^[11] in the gastrointestinal tract, which possibly includes the stomach, small intestines, colon, appendix, rectum and anus but in childhood it is not detected as the symptoms are found in adolescence. It is not an aggressive sarcoma because once it is removed from the body by a proper treatment, it do not affect any other parts of the body. Among all the soft tissue sarcoma, 5-10% sarcoma are leiomyosarcoma^[12]. Various types of leiomyosarcoma are as follows:

- **Soft tissue leiomyosarcoma:** It is usually found in children and is same as the affected parts which occur in leiomyosarcoma. The common or the main symptom is weight loss and abdominal discomfort.
- **Cutaneous leiomyosarcoma:** normally men suffer from this sarcoma but in childhood girl and boy equally suffer from this sarcoma. It is benign and do not spread to other part of the body. As a symptoms a purple or red spots are seen deeper in skin.
- **Vascular leiomyosarcoma:** it is a very rare sarcoma and it occurs from the major blood vessels. It further leads to blockage in the vein, enlarged liver, abdominal pain, jaundice, shortness of breath, chest discomfort.
- **Immunocompromised host leiomyosarcoma:** AIDS, HIV comprises immune system and the children get prone to this sarcoma.
- **Bone leiomyosarcoma:** it is very rare sarcoma. It mainly occurs in long bones and the bone sarcoma is indeed very hard to find. They are found by using X-Rays in a very translucent way.

Rhabdomyosarcoma- This type of sarcoma is most common type found in skeletal muscle soft tissue sarcoma. The common site for origination is the arms or legs, but also develops in the head, neck,

urinary or reproductive organ areas. 85% of this type of sarcoma occurs in infants, children and teenagers. The major risk of rhabdomyosarcoma is to those children those are born by accompanying birth defects. The common symptoms for this sarcoma are a mass but without a pain. If the tumor is found in the nose or throat, it may cause bleeding or neurological defects. If in eyes, it causes bulging of eyes and vision problems. This sarcoma is detected very late as the symptoms are very rare. Rhabdomyosarcoma is very aggressive as it spreads randomly. It is detected by using biopsy, chest X-ray, bone marrow biopsy, CT- scan. For curing the sarcoma chemotherapy and radiation is given combined or is used individually. Various histological subtypes of rhabdomyosarcoma is there, which have a variation in the clinical and pathological characteristics. Various classification system have been for classifying these tumors, the "International Classification of Rhabdomyosarcoma" is the most recent classifying system[13]. This classifying system helps in combining the previous systems and the prognosis based on the tumor types. Example for such subtypes are sclerosing rhabdomyosarcoma.

Liposarcoma of fatty tissue – This type of sarcoma can be developed at anywhere of the body but most site is the lining in the back of the abdominal cavity. It also occurs in the thigh, the gluteal areas or behind the knee. Basically it's a malignant tumor[14], it is commonly found among 30 to 60 years of aged group person but most common among men than women. These sarcomas have mainly 3 biologic forms: firstly, well differentiated liposarcoma, secondly, myxoid or round cell and thirdly, pleomorphic. Chromosomal abnormalities create a fusion protein which is the main component of the formation of the cancer. The abnormality which is caused in 12q13 leads to liposarcoma. The mortality rate is approximately 50%. Liposarcoma mainly occurs in males as compared to that of females. The major symptoms for liposarcoma are vomiting, weight loss, fatigue, painful swelling, and enlargement of veins (refer: fig1).

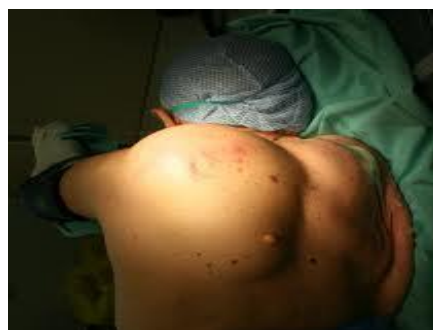

Figure1: Lump formation in liposarcoma (Panoraia Paraskeva et al, 2009)[15]

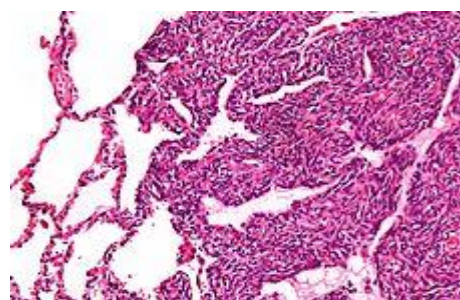


Figure2: Micrograph of a monophasic synovial sarcoma. The histologic appearance is non-specific and overlaps with MPNST and fibrosarcoma (Raphael E. Pollock, (2002)[18]

Synovial sarcoma- This is a type of sarcoma which is found mainly in males as compared to females. Mainly this sarcoma occurs in the synovial tissues. It is a high grade tumor among all the mentioned sarcomas. It occurs due to the translocation t(X;18) (p11;q11) i.e. in chromosome 18 and X chromosomes the translocation takes place.

Due to the translocation the sarcoma contains a mutant gene. It has similar symptoms as that of the other mentioned sarcoma. Synovial sarcoma is found 8% of all the other sarcoma^[16], but about 15-20% cases in young adults and adolescence^[17].

It can be diagnosed by image studying such as X-ray, MRI, sonogram, CT scan and also by biopsy (refer: fig: 3).

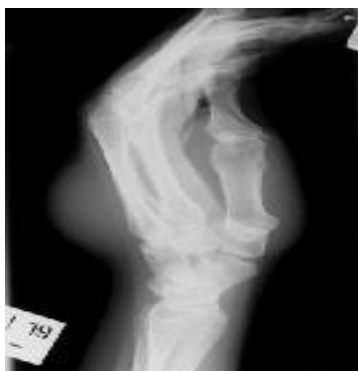

Figure 3:-Lateral radiograph depicts a synovial sarcoma of the dorsum of the hand (Bernardo Vargas, 2012)[19]

Angiosarcoma – Start in the inner-lining wall of blood or lymphatic vessels. It is a malignant neoplasms which occurs very randomly and it proliferates in a very fast manner. This sarcoma is said as angiosarcoma as it is a wide range of endothelial vascular neoplasms. It affects various parts of the body such as liver, spleen, breast or heart. It occurs due to lympheda, and also due to much exposure to radiation or carcinogenic components. This sarcoma can be presented in the form of skin infection or a lump formation. This sarcoma can be possible to the person aged from 5 to 97 years^[20]. The mortality rate is very low in this sarcoma. Angiosarcoma mainly affects the neck and head part of the body. Angiosarcoma can be diagnosed by using X-Rays, MRI and CT scan, for lump formation biopsy is done. This sarcoma is very aggressive and grows very rapidly so once it is diagnosed it should be treated immediately. The treatment provided for after angiosarcoma is detected are mainly chemotherapy in which doxorubicin is much more preferred. Paclitaxel and docetaxel are provided for head, neck, and scalp affected angiosarcoma.

MPNST (Malignant peripheral nerve sheath tumors) – This type of malignant tumors are occurred among old aged person. It is also known as neurofibrosarcoma; neurosarcoma. This type of sarcoma occurs twice common among men than female. Main site for the development of this soft tissue sarcoma is the extremities and the anatomical space behind the abdominal cavity. Mainly it starts from the peripheral nerves or from the cells which are associated with the nerve sheath, also arises from neurofibroma. This sarcoma is normally available in a big lump along with a pain and it grows very rapid and also very aggressive. Its lifetime risk with neurofibromatosis type1 is 8-13%^[21]. MPNST is very deep-seated

and it gets involved in proximal upper and lower extremities. To detect the area of the sarcoma CT scan or MRI is done; along with it imaging studies is also done. This sarcoma is staged into four parts and those are stage 1 which describes low- grade tumor, stage 2 which describes high low grade tumor, stage 3 which describes high grade large tumor, and at last stage 4 with evidence of metastasis. Biopsy is done to detect the affected area and after detection for treatment surgery is the mainstay for this sarcoma, later radiation and chemotherapy is provided to the patient.

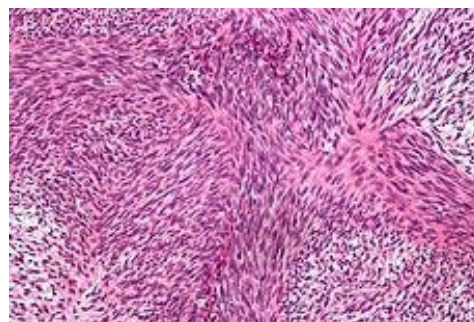


Figure 5: Micrograph of a tumor with the herringbone pattern as may be seen in fibrosarcoma (Ettinger, Stephen J; Feldman, Edward C, 1995)^[22]

GIST (Gastrointestinal Stromal Sarcoma) – The cancer which affect the digestive tracts and nearby structure within the abdomen. These types of sarcomas generally occur among age 50 to 70 and rarely occur among the children. This sarcoma generally takes place of cancer, if not treated at an early stage or not detected. Basically this sarcoma is defined as tumors whose behavior is driven by mutations in KIT gene or PDGFRA gene and may or may not stain positive for KIT gene^[23]. About 60% of this sarcoma starts in the stomach i.e., any part of the digestive tract (For further information refer table). In GIST patients it is found that OBSCN tends to be expressed at a higher level than C9orf65^[24]. The major symptoms of this sarcoma is feeling uneasiness and pain in the abdominal part, low red blood cell count, vomiting, blood in stool, feeling tired. After the detection of this sarcoma with the help of biopsy or through image studying, surgery is the main treatment which is capable of curing small tumors. In image studying to distinguish it with gastric adenocarcinoma or gastric/small bowel lymphoma, malignant lymphadenopathy (swollen lymph nodes) is uncommon and thus it shows absence of lymph node enlargement^[25]. Unluckily, chemotherapy or radiation does not work well for this sarcoma and hence biological therapy commonly called as Glivec is applied. For further information, Glivec is an inhibitor of tyrosinase kinase, it blocks the enzyme which help the tumor to grow further. GIST is able to be cured if the affected part is completely removed by surgery, Glivec therapy helps the patient to survive for a longer period of duration as per the case studies is done, they may lead there more than 8 years after the treatment.

Table 3: Risk Stratification of Primary GIST by Mitotic Index, Tumor Size, and Tumor Location (Corless CL, Heinrich MC, 2008)^[26]

Mitotic Index, hpf	Size, cm	Site and Risk of Progressive Disease (%)			
		Gastric	Duodenum	Jejunum/Ileum	Rectum
≤5 per 50	≤2	None (0)	None (0)	None (0)	None (0)
	>2 ≤5	Very low (1.9)	Low (4.3)	Low (8.3)	Low (8.5)
	>5 ≤10	Low (3.6)	Moderate (24)	(Insufficient data)	(Insufficient data)
>5 per 50	>10	Moderate (10)	High (52)	High (34)	High (57)
	≤2	None	High	(Insufficient data)	High (54)
	>2 ≤5	Moderate (16)	High (73)	High (50)	High (52)
	>5 ≤10	High (55)	High (85)	(Insufficient data)	(Insufficient data)
	>10	High (86)	High (90)	High (86)	High (7)

GIST = gastro intestinal stromal tumor; hpf = high-power field, assessed from an area that on initial screen appears to have the highest mitotic activity.

Dermatofibrosarcoma- Dermatofibrosarcoma(DFSP)[27] is one of the rarest forms of sarcoma which mainly occur in the dermis layer of the skin. It is found only among 1 case per million of the year. This type of sarcoma is considered to be as a benign tumor, but 2-5% of cases become metastasize. Hence, it also has malignant potential. It is most commonly found among adults as compared to the children and mostly occur 2-6% of soft tissue sarcoma cancer. This type of sarcoma mainly occur in minor firm area of skin and gradually spread and found on torso and also found on arms, legs, and neck. It is divided into different form i.e. according to their occurrences. About 90% of dermatofibrosarcoma are low grade and 10% are mixed hence this type of sarcoma is considered to be intermediate grade sarcoma.

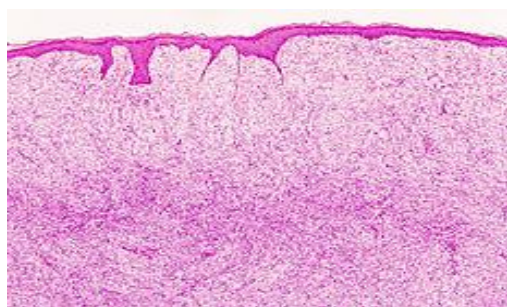


Figure6 :- Histopathological image of dermatofibrosarcoma protuberans

(Patel KU, Szabo SS, Hernandez VS, et al. (February 2008)[28].

Biopsy is core for the diagnosis of Dermatofibrosarcoma, where the portions of the tumor have to be removed for examination. For the assurance that the enough tissue has been removed, initial biopsy of a suspected DFSP is done by core needle or a surgical incision. This can be primarily treated by surgery, chemotherapy and by radiation therapy. Now a day's CCPDMA or Mohs surgery is also very common for this disease. Mohs surgery is one of the effective technique in which not only tumor is removed but all pathological cells without a wide area excision that may overlook sarcoma cells that have penetrated muscle tissue. Newly discovered drug which is quite effective against this disease is IMATINIB this drug inhibit tyrosine kinase^[29].

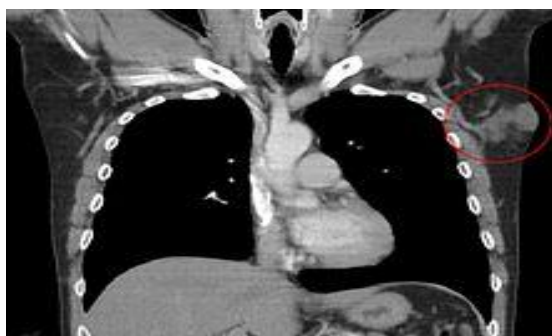

Figure7 :- Dermatofibrosarcoma protuberans of the left axilla
(Gloster HM, Harris KR, Roenigk RK (July 1996)[39].

Dermatofibrosarcoma occur due to chromosomal translocation at t(17; 22). The translocation fuses the collagen gene (COL1A1) with the platelet-derived growth factor gene. The resulting fusion cause maturation of platelet derived growth factor and the fibroblast which contain the receptor for this growth factor thinks producing its structural protein and the cells started rapidly dividing for the tumor formation. This is quite positive for the CD3. Lymphangiosarcoma: A rare malignant tumor is a lymphangiosarcoma, and the other name for lymphangiosarcoma is Stewart-Treves syndrome. It is very fatal in nature and it affects mainly the skin. This sarcoma is related to lymphedema. Lymphedema is nothing but the swelling of legs and arms caused due to blood vessels or lymphatic system. There are 3 stages of

lymphangiosarcoma such as stage1; stage2; stage3. The descriptions are given below briefly:

Stage1: Chronic lymphedema: In this stage only the swelling of arms and legs occurs and later it leads to the breakdown of collagen and fats in skins. This lymphedema from other causes may also be associated with Stewart-Treves syndrome[30].

Stage2: Premalignant angiomatosis: In the layer of dermis and subdermis, containing the lining of endothelial cells forms a channel like. Affected areas of angiomatosis appear as a deep hemorrhages or bruises. Some of the lesion can be malignant or benign.

Stage3: Malignant angiosarcoma: This is the final stage of lymphangiosarcoma. It is very aggressive in this stage and it turns to be cancerous and starts to spread rapidly. Multiple areas get affected as it starts growing rapidly.

Chemotherapy and radiation is mainly used for treating angiosarcoma. Biopsy is done for the suspected lesion areas. These treatments should be done very rapidly, and the progression of treatment should be very rapid to obstruct the swelling of the affected areas.

Kaposi's sarcoma:- Kaposi's sarcoma was originally described by Moritz Kaposi, an Hungarian dermatologist practicing at the University of Viennain 1872[31]. Kaposi sarcoma is a form of tumor caused by human herpesvirus8 (HHV8), hence it is also known as kaposi's sarcoma associated herpesvirus. Kaposi's sarcoma is present with cutaneous lesions with or without internal involvement. This type of sarcoma has been subdivided into four types and they are as follows: Classic KS, African sarcoma, KS in iatrogenically immunosuppressed patients and AIDS related KS. KS can be detected by observing macular, patch, plaque, nodular, and eophytic. Classic KS tends to be indolent, presenting with erythematous or violaceous patches on the lower extremities. African endemic KS and AIDS-related KS tend to be more aggressive. The AIDS-related KS lesions often rapidly progress to plaques and nodules affecting the upper trunk, face, and oral mucosa. The treatment of KS is totally depending on their subtypes once it will get detected. Localized cutaneous disease can be treated with the cryotherapy, intralesional injection of vinblastine, alliteration gel, radiotherapy, tropical immunotherapy.

Symptoms of KS are nodules of blotches that may be red, purple, brown, or black (refer: fig8). Primarily it occurs in the skin that gradually spread throughout the mouth, gastrointestinal tract and respiratory tract. Most commonly affected area of KS is lower limbs, back, face, mouth and genital in skin.

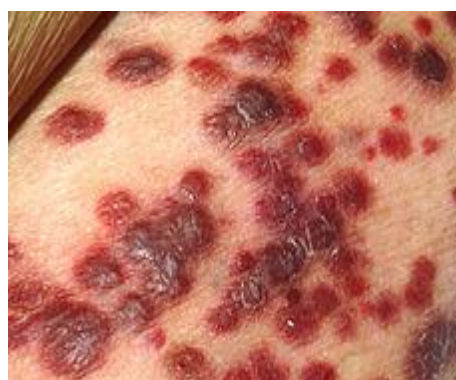

Figure8 :-Kaposi sarcoma occur in skin

(Chang, Y., E. Cesarman, M. S. Pessin, F. Lee, J. Culpepper, D. M. Knowles, and P. S. Moore. 1994)[40].

About 30%, and is the initial site in 15% of AIDS-related KS. In the mouth, the hard palate is most frequently affected, followed by the gums. Lesions in the mouth may be easily damaged by chewing and bleed in mouth. When KS occur in gastrointestinal tract main symptoms behind this is silent loss of weight, pain, nausea, diahorrea with bleeding, vomiting, malabsorption.

But in respiratory tract diagnosis can be confirmed by bronchoscopy. It involves shortness of breath, fever, chest pain and hemotysis. As such no treatment is there for this type of sarcoma. Surgery is totally restricted in this type of sarcoma. But somewhat radiation therapy or cryosurgery is recommended for this type patients suffering from KS. Surgery is not recommended on this type sarcoma because in this sarcoma wound formation takes place. Even this type sarcoma can be treated with systemic therapy with interferon alpha, liposomal anthracyclines, or paclitaxel.

Hemangiosarcoma: Hemangiosarcoma is rapidly growing, highly invasive type of cancer which mainly occurs among the dogs and cats. This type sarcoma arises from the lining of blood vessel that is blood filled channels and spaces are commonly observed microscopically. It is associated with the toxic exposure to thorium dioxide, vinyl chloride and arsenic.

Treatment includes chemotherapy and practical remove of tumor with the affected organ. Drugs include doxorubicin also quite affective against this disease.

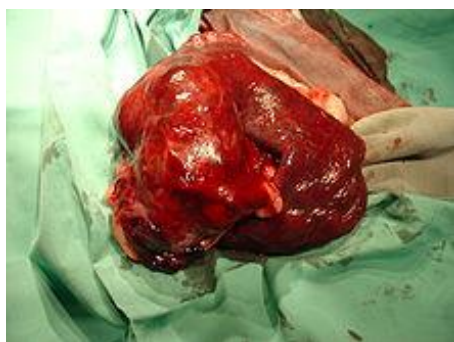


Figure9 :- Hemangiosarcoma of the spleen in the dogs(Ettinger, Stephen J; Feldman, Edward C, 1995)

Neurofibrosarcoma: Neurofibrosarcoma is sometimes said to be as a "Peripheral nerve sheath tumor", it is a very rare kind of tumor. As the name suggests, it affects the peripheral nerves which are the part of nervous system and do not include brain and spinal cord. The mainly affected areas are legs and arms. Neurofibrosarcoma is classified as soft tissue sarcoma and this sarcoma begins in the tissues (refer: fig10). This sarcoma do not spread in the body or metastasize but when it starts spreading it becomes very aggressive and it attacks lungs. The victims of the neurofibrosarcoma remains fit till the pain and soreness occur as a symptom along with the lump formation below the skin. This sarcoma is a genetic sarcoma and also happens due to mutated gene. The occurrence of the neurofibrosarcoma is still unknown but it has been found that this sarcoma accounts for 5% to 7% of all soft tissue sarcoma cases.

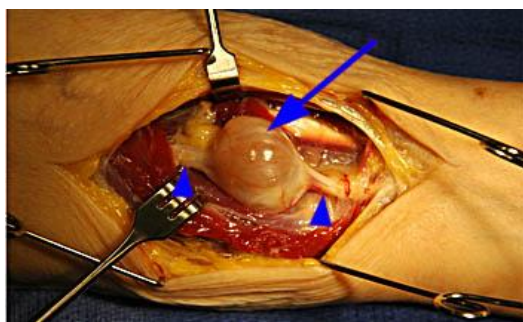


Figure 10: Malignant Neurofibrosarcoma

(MRI Web Clinic - May 2011 Schwannoma of the Median Nerve by William N. Snearly)[41].

The treatment given by doctor is to provide X-rays or Magnetic Resonance Imaging (MRI) procedure. To shrink the tumor and destroy the cancer, chemotherapy and radiation is given combined or in single way. Early diagnosis increases the rate of survival. This

sarcoma varies from patient to patient and also there is a variation in size and shape of the tumor.

As children and adults are both affected in this sarcoma, so the below mentioned Table 4 and Table 5 shows different names of the soft tissue as per the affected area.

Table4: Major types of soft tissue sarcoma found in Adults (Ries LAG, Harkins D, Karpcho M, et al)[8].

Site of origin	Type of sarcoma	Location in the body
	Fibro sarcoma	Arms; legs; trunk
Fibrous tissue	Malignant fibrous hystiocytoma	Legs
Fat	Dermatofibrosarcoma Liposarcoma	Trunk Arms; legs; trunk
Muscle	Rhabdomyosarcoma	Arms; legs; uterus; digestive tract
Blood vessels	Hemangiosarcoma Kaposi's sarcoma	Arms; legs; trunk Legs; trunk
Lymph vessels	Lymphangiosarcoma	Arms
Synovial tissue	Synovial sarcoma	Legs
Peripheral nerves	Neurofibrosarcoma	Arms; legs; trunk

Table5: Major types of soft tissue sarcoma found in Children (Ries LAG, Harkins D, Karpcho M, et al)[8].

Site of origin	Type of sarcoma	Location in the body	Common ages
Muscle	Rhabdomyosarcoma Embryonal	Head, neck, GI tract	4 yrs 19 yrs
	Alveolar soft part sarcoma, Leiomyosarcoma Fibrosarcoma	Arm, head, neck, leg Trunk Arms; legs	15-19 yrs 15-19 yrs
Fibrous tissue	Malignant fibrous hystiocytoma Dermatofibrosarcoma	Leg Trunk	15-19 yrs 15-19 yrs
Fat	Liposarcoma	Arms; leg	15-19 yrs
Blood vessel	Infantyl hemangiopericytoma	Arms; leg; trunk; head; neck	4 yrs
Synovial tissue	Synovial sarcoma	Leg; arm; trunk	15-19 yrs
Peripheral nerves	Neurofibrosarcoma	Arm; leg; trunk	15-19 yrs
Muscular nerves	Alveolar soft part sarcoma	Arm; leg	19 yrs

(*note: for information about the mentioned different types of sarcoma in a table, a brief idea is given above)

Various genes are present in inducing soft tissue sarcoma and they are as follows:

Nf-1 gene: Officially Nf-1 gene is said to be neurofibromin-1. NF-1 gene is also known as WSS, NFNS, and VRNF (Stowe IB, et al. Genes

Dev, 2012). It is found in chromosome 17 in the long arm at the position 11.2, and it is located from base pair 29,421,944 to base pair 29,704,694. Nf-1 gene provides instruction for making protein neurofibromin, this protein is produced by various cell like nerve cell and some specialized cell called oligodendrocytes. This protein acts a tumor suppressor protein and prevents cell from growing and dividing rapidly in uncontrolled manner but, inactivation of this one copy of gene in each cell increase the risk of developing Juvenile Myelomonocytic Leukemia (JMML). It is a type of cancer of blood forming tissue that occur among children younger than 2. The incidence of NF-1 is about 1 in 3500 live births. The incidence of NF-1 is about 1 in 3500 live births[32].

P53 gene: It was first identified in 1979 by Arnold Levine, David Lane, and William Old. Officially P53 is known to be as TP53, tumor protein, BCC7, LFS1, TRP53. It is found in chromosome 17 (p, 13.1) (Bar JK, et al. Adv Clin Exp Med, 2012). This gene is response to diverse cellular stress to regulate target gene that induce cell cycle arrest apoptosis, senescence, DNA repair or change in metabolism. Loss of chromosome 17 and inactivating point mutations have frequently been observed in soft tissue sarcomas, particularly in malignant fibrous histiocytoma, rhabdomyosarcomas, and leiomyosarcomas[33,34]. But mutation in this type of gene causes loss in tumor suppressor activity which further leads to different types of cancer.

Alteration of this gene not only cause somatic mutation but also causes germ line mutation, in some cancer prone families with Li-Fraumeni Syndrome. Hence, mutation in such type of gene causes soft tissue sarcoma, bone sarcoma and adrenal cortical carcinoma.

CDKN2: The full form of CDKN2 is known as cyclic dependent kinase2, which is located in chromosome number 12(q, 13). It is also known as p33(CDKN2) (Ludgate L, et al. J Virol, 2012). The protein coded by this gene is a member of the Ser/Thr protein kinase family. The subunit of this gene is responsible to restrict the G1-S phase, an essential for cell cycle. But alteration in this gene for example, spliced variants and multiple transcription initiation factor can lead to soft tissue sarcoma. The latter observation agreed with an immunological study showing that the cyclin D1 protein level is elevated in up to 40% of soft tissue sarcomas[35] and with an early report of CDK4 gene amplification in a rhabdomyosarcoma [36].

RB1 gene: RB1 gene is said as retinoblastoma 1, located in chromosome number 13(q, 14.2) [37]. It is also known as RB, pRb, OSRC, pp110 (Cel T, et al. J Biol Chem, 2012). The protein encoded by this gene is negative regulator for cell cycle and was first tumor suppressor gene found. It stabilizes constitutive heterochromatin to maintain overall chromatin structure. Defects in this gene such as deletion can cause childhood cancer retinoblastoma, bladder cancer and osteogenic sarcoma (provided by RefSeq, 2008).

N-RAS Gene: The official name of the gene is neuroblastoma RAS viral oncogene homolog. It is located in p arm of chromosome number 1, position 13.2. This gene is responsible for encoding N-RAS protein which leads to the conversion of GTP to GDP. But mutation in this gene may cause Noonan syndrome lead to alternation of N-RAS protein that show increased in GTP binding and decrease in ability to convert GTP into GDP. Instead of triggering for cell growth in response to particular signal the over expression of this protein may lead to cells to grow rapidly and divide constantly. Activated N-RAS was detected in a leiomyosarcoma[38].

Risk factor for the development of soft tissue sarcoma

Soft tissue sarcoma is very rare and it is found in the whole world but less in rate. Hardly 5-6 cases come to be heard in a single year. There are various risk factors which lead to soft tissue sarcoma such as when the persons are much more exposed to chlorophenols and wood preservative; phenoxy herbicides have increased the rate of soft tissue sarcoma. Exposures to Vinyl chloride cause Angiosarcoma in the liver. High dosage of radiation also leads to soft tissue sarcoma. Human herpes virus8 tends to give birth to Kaposi's sarcoma that occurs in lining of blood vessel. Certain inherited disease also have high risk of developing soft tissue sarcoma such as neurofibromatosis type-1, which leads to alteration of gene Nf-1 gene which increase the risk of developing soft tissue sarcoma known as malignant peripheral nerve sheet tumor. In general there

are 46 chromosomes which together comprises of 30,000 genes. Many a times cytogenetic aberrations are visualized in the chromosomes under microscope, one cytogenetic abnormalities found in 50% Leiomyosarcoma due to deletion of chromosome 1 short arm (1,2). Various genes get mutated in the chromosomes and lead to form soft tissue sarcoma, in the general region of RB1 gene loss of single copy of 13 chromosome tends to cause Fibroushistiocytoma, Leiomyosarcoma, Rhabdomyosarcoma. Loss of both gene copies of CDKN2 gene which encodes for p16 cause malignant peripheral nerve sheet tumor, Rhabdomyosarcoma, Leiomyosarcoma. In soft tissue sarcoma loss of chromosome 17 an inactivating point mutations are frequently observed in malignant Fibrous Histiocytoma, Rhabdomyosarcoma and Leiomyosarcoma. There are certain genes whose affects are under study of soft tissue sarcoma such as MDM2, N-RAS.

Diagnosing of soft tissue sarcoma

There are 5 suspicious methods to detect the painless lump, for instance

Biopsy (small piece of tissue studied under a microscope): Refer to fig11

- Fine needle aspiration biopsy (FNA) –thin needle is used to withdraw the small fragment of tissue from tumor mass and physical examination is done.
- Core needle biopsy – larger needle compared to FNA is used.
- Surgical biopsy – entire tumor is removed for the physical examination.

Immunohistochemistry - This cell are treated with chemicals for the detection of sarcoma which cause changes in the color due to specific type of protein.(fig12)

Cytogenetics – In this test cell chromosomes are examined under microscope to look for changes.

FISH (Fluorescence in-situ Hybridization) - Detect translocation on other chromosomal changes, but this technique is not used much for the detection.

Reverse transcription – Detect translocation in some sarcomas to confirm the type of tumor.

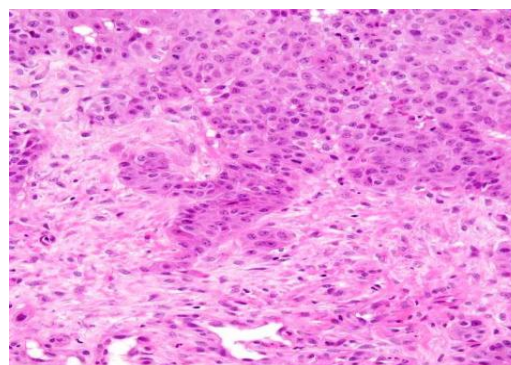


Figure11: Biopsy sample seen under microscope (Wakui S et al, 1992)[42]

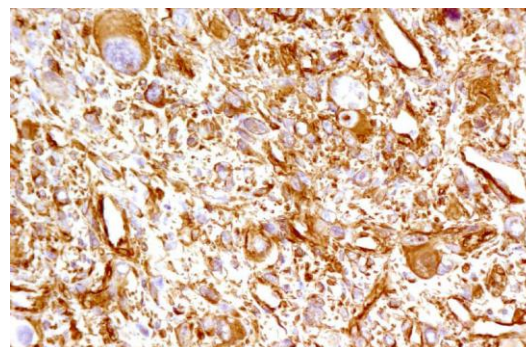


Figure12: Immunohistochemistry technique done and visualized under microscope (Hudacko R et al 2011)[43]

CONCLUSION

We can conclude that by giving a brief summary, sarcoma are basically classified into two types i.e. soft tissue sarcoma and bone sarcoma. Out of these two soft tissue sarcoma is very rare and hardly 4 to 5 cases are found in every year. Various types of soft tissue sarcoma are found which affects various parts of the body and the names of the sarcoma are given according to the affected parts. Mainly the tissue part is affected in the body. Young aged and adults are affected with this sarcoma along with the involvement of the painless lump. Various genes are also involved in inducing soft tissue sarcoma and they are as RB1, CDKN2, P53, N-RAS. In addition to the known immunoreactivity for CAM5.2 and EMA the positivity for CK7 and 34BE12 for small proportion cases is also observed. Research work is still under process and this soft tissue sarcoma has basically four stages (stage 1; stage 2; stage 3; stage 4). The survival rate for the patients is 5 years. At an early stage if the symptoms are diagnosed then it can be cured but the percentage for the cure is very low. Recurrence of this sarcoma can also happen but the probability is yet low. As this sarcoma is seen with the painless lump various detection is done such as with the help of biopsy, immunohistochemistry, cytogenetics, reverse transcript. Chemotherapy is done to cure the patients along with the surgery. Various researches are still under process to bring this soft tissue sarcoma under control and hope that affected people get cured at an early stage.

REFERENCE

- Singer S (1999). New diagnostic modalities in soft tissue sarcoma. *Semin Surg Oncol* 17 (1): 11-22.
- Saboorian, M.H., Ashfaq, R., Vandersteenhoven, J.J. and Schneider, N. (1997). Cytogenetics as an adjunct in establishing a definitive diagnosis of synovial sarcoma by fine-needle aspiration. *Cancer Cytopathology* 81:187-192.
- Alizadeh AA, Eisen MB, Davis RE, Ma C, Lossos IS, Rosenwald A, Boldrick JC, Sabet H, Tran T, Yu X, et al.: Distinct types of diffuse large B-cell lymphoma identified by gene expression profiling. *Nature* 2000, 403:503-511.
- Khan J, Wei JS, Ringner M, Saal LH, Ladanyi M, Westermann F, Berthold F, Schwab M, Antonescu CR, Peterson C, Meltzer PS: Classification and diagnostic prediction of cancers using gene expression profiling and artificial neural networks. *Nat Med* 2001, 7:673-679.
- Perou CM, Sorlie T, Eisen MB, Rijn M van de, Jeffrey SS, Rees CA, Pollack JR, Ross DT, Johnsen H, Akslen LA, et al.: Molecular portraits of human breast tumours. *Nature* 2000, 406:747-752.
- Baird K, Davis S, Antonescu CR, Harper UL, Walker RL, Chen Y, Glatfelter AA, Duray PH, Meltzer PS: Gene expression profiling of human sarcomas: insights into sarcoma biology. *Cancer Res* 2005, 65:9226-9235.
- West RB, Rijn M van de: The role of microarray technologies in the study of soft tissue tumours. *Histopathology* 2006, 48:22-31.
- Ries LAG, Harkins D, Krapcho M, et al. SEER Cancer Statistics Review, 1975-2003. Bethesda, MD: National Cancer Institute, 2006.
- Ettinger, Stephen J.;Feldman, Edward C. (1995). Textbook of Veterinary Internal Medicine (4th ed. ed.). W.B. Saunders Company.
- Albert H. O-Yurvati, DO, University of North Texas Health Science Center, Department of Surgery, 855 Montgomery St, Fort Worth, TX 76107-2553.
- Yannopoulos K, Stout AP. Smooth muscle tumors in children. *Cancer* 15:958, 1962.
- Miettinen M, Lasota J (October 2006). "Gastrointestinal stromal tumors: review on morphology, molecular pathology, prognosis, and differential diagnosis". *Arch. Pathol. Lab. Med.* 130 (10): 1466-78.
- Newton WA, Gehan EA, Webber BL, et al. (September 1995). "Classification of rhabdomyosarcomas and related sarcomas. Pathologic aspects and proposal for a new classification—an Intergroup Rhabdomyosarcoma Study". *Cancer* 76 (6): 1073-85.
- Dei Tos AP (August 2000). "Liposarcoma: new entities and evolving concepts". *Ann Diagn Pathol* 4 (4): 252-66.
- Panoraia Paraskeva, Paraskevas Katsaronis, Eleftherios D Spartalis, Andreas C Lazaris, Hara Gakiopoulou, Panagiotis Mallis and Periklis Tomos: *Giant liposarcoma of the back with 4 types of histopathology: a case report, Cases Journal* 2009, 2:9339
- Ferrari and Collini (2012). "Synovial Sarcoma".
- Weiss SW, Goldblum J. "Malignant soft tissue tumors of uncertain type". In Weiss SW, Goldblum JR. *Enzinger and Weiss's Soft Tissue Tumors*. St Louis, Missouri: CV Mosby. pp. 1483-1571.
- Raphael E. Pollock, ed. (2002). *Soft Tissue Sarcomas*. American Cancer Society Atlas of Clinical Oncology. BC Decker. ISBN [[Special:BookSources/1055009128X|1055009128X.
- Bernardo Vargas, Mark Clayer, Howard A Chansky. *Synovial Cell Sarcoma*, medscape references, 2012
- Meis-Kindblom JM, Kindblom LG. Angiosarcoma of soft tissue: a study of 80 cases. *Am J Surg Pathol.* Jun 1998;22(6):683-97.
- Evans DG, Baser ME, McGaughran J, Sharif S, Howard E, Moran A (May 2002). "Malignant peripheral nerve sheath tumours in neurofibromatosis 1". *J. Med. Genet.* 39 (5): 311-4.
- Ettinger, Stephen J.;Feldman, Edward C. (1995). *Textbook of Veterinary Internal Medicine* (4th ed.). W.B. Saunders Company.
- Miettinen M, Lasota J (October 2006). "Gastrointestinal stromal tumors: review on morphology, molecular pathology, prognosis, and differential diagnosis". *Arch. Pathol. Lab. Med.* 130 (10): 1466-78.
- Price ND, Trent J, El-Naggar AK et al. Highly accurate two-gene classifier for differentiating gastrointestinal stromal tumors and leiomyosarcomas. *Proceedings of the National Academy of Sciences*. 2007;104:3414-3419.
- Hersh MR, Choi J, Garrett C, Clark R. (2005). "Imaging Gastrointestinal Stromal Tumors". *Cancer Control* 12 (2): 111-115.
- Corless CL, Heinrich MC: Molecular pathobiology of gastrointestinal stromal sarcomas. *Annu Rev Pathol* 3: 557-86, 2008.
- Mendenhall WM, Zlotecki RA, Scarborough MT (December 2004). "Dermatofibrosarcoma protuberans". *Cancer* 101 (11): 2503-8.
- Patel KU, Szabo SS, Hernandez VS, et al. (February 2008). "Dermatofibrosarcoma protuberans COL1A1-PDGFB fusion is identified in virtually all dermatofibrosarcoma protuberans cases when investigated by newly developed multiplex reverse transcription polymerase chain reaction and fluorescence in situ hybridization assays". *Hum. Pathol.* 39 (2): 184-93.
- Sirvent N, Maire G, Pedeutour F (May 2003). "Genetics of dermatofibrosarcoma protuberans family of tumors: from ring chromosomes to tyrosine kinase inhibitor treatment". *Genes Chromosomes Cancer* 37 (1): 1-19.
- Sánchez-Medina MT, Acosta A, Vilar J, Fernández-Palacios J. Angiosarcoma in Chronic Lymphedema (Stewart-Treves Syndrome). *Actas Dermosifiliogr.* Feb 23 2012.
- Kaposi, M (1872). "Idiopathisches multiples Pigmentsarkom der Haut". *Arch. Dermatol. Syph.* 4 (2): 265-273.
- Online 'Mendelian Inheritance in Man' (OMIM) NEUROFIBROMATOSIS, TYPE I; NF1 -162200.
- Stratton MR, Moss S, Warren W, Patterson H, Clark J, Fisher C, Fletcher CDM, Ball A, Thomas M, Gusterson BA, Cooper CS. Mutation of the p53 gene in human soft tissue sarcomas: Association with abnormalities of the RB1 gene. *Oncogene* 5:1297-1301, 1990.
- Mulligan LM, Matlashewski GJ, Scoble HJ, Cavenee WK. Mechanisms of p53 loss in human sarcomas. *Proc Natl Acad Sci USA* 87:5863-5867, 1990.

35. Bartkova J, Lukas J, Strauss M, Bartek J. Cyclin D1 oncoprotein aberrantly accumulates in malignancies of diverse histogenesis. *Oncogene* 10:775-778, 1995.
36. Khatib ZA, Matsushime H, Valentine M, Shapiro DN, Sherr CJ, Look AT. Coamplification of the CDK4 gene with MDM2 and GL1 in human sarcomas. *Cancer Res* 53:5535-5541, 1993.
37. Stratton MR, Williams S, Fisher C, Ball A, Westbury G, Gusterson BA, Fletcher CDM, Knight JC, Fung Y-K, Reeves BR, Cooper CS. Structural alterations of the RB1 gene in human soft tissue tumours. *Br J Cancer* 60:202-205, 1989.
38. Gill S, Stratton MR, Patterson H, Spurr NK, Fisher C, Gusterson B, Cooper CS. Detection of transforming genes by transfection of DNA from primary soft tissue tumours. *Oncogene* 6: 1651-1656, 1991.
39. Gloster HM, Harris KR, Roenigk RK (July 1996). "A comparison between Mohs micrographic surgery and wide surgical excision for the treatment of dermatofibrosarcoma protuberans". *J Am Acad Dermatol.* 35 (1): 82-7.
40. Chang Y, Cesarman E, Pessin MS, Lee F, Culpepper J, Knowles DM, Moore PS. Identification of herpesvirus-like DNA sequences in AIDS-associated Kaposi's sarcoma. *Science.* 1994 Dec 16;266(5192):1865-9.
41. William N. Snearly. Schwannoma of the Median Nerve, MRI Web Clinic - May 2011.
42. Wakui S, Furusato M, Nomura Y, Iimori M, Kano Y, Aizawa S, Ushigome S. (1992) Testicular epidermoid cyst and penile squamous cell carcinoma. *Vet Pathol.* 1992 Nov;29(6):543-5.
43. Hudacko R, Rapkiewicz A, Berman RS, Simsir A. ALK-negative anaplastic large cell lymphoma mimicking a soft tissue sarcoma. *J Cytol* 2011;28:230-3.