

CLINICO-RADIOLOGICAL FEATURES IN CORROBORATION WITH INTRAOPERATIVE FINDINGS OF INTUSSUSCEPTION IN INFANTS-LESSONS LEARNED IN REMOTE SET UP DURING OVERSEAS DEPLOYMENT (EAST AFRICA)

NARENDER YADAV¹, RAVISHEKAR N HIREMATH², PEEYUSH DHAGAT¹, KASUKURTHI LEELAKANTH¹, RISHI RAJ³

¹Department of Radio-Diagnosis, AFMS, New Delhi, India. ²Department of Community Medicine, AFMS, New Delhi, India. ³Department of Medical Informatics, AFMS, New Delhi, India. Email: yadavnarender97@gmail.com

Received: 31 October 2022, Revised and Accepted: 18 January 2023

ABSTRACT

The incidence rate of Intussusception is higher in some developing countries, which leads to a higher rate of complications in those areas especially in children. Plain abdomen radiograph is the initial radiological examination to be done in a case of acute abdomen in a peripheral set up. Ultrasound (USG) would be best modality for initial screening even in remote areas as it has the advantages of being non-invasive, rapid, and not only cost effective but also avoids radiation exposure and easily available even in peripheral set up in today's era. Moreover, it can be done bedside, even with less experienced readers. Here, in this article, we are discussing the clinic-radiological and intraoperative features of intussusception in infants, while we were deployed in remote areas of Eastern Africa with limited settings. This article highlights the importance of strong clinical suspicion and timely ultrasonographic evaluation as primary screening modality in suspected cases of intussusception. USG not only confirms the diagnosis with classical signs and appearances but also help rule out other conditions mimicking the diagnosis and will decrease the risk for bowel obstruction, perforation, necrosis, and death by aiding in timely surgical intervention. In addition to this, the lesson learned from various cases is that, assessment of length of segment of bowel telescoping into the other segment will aid in deciding mode of surgical intervention.

Keywords: Intussusception, Infants, Clinical, Radiological.

© 2023 The Authors. Published by Innovare Academic Sciences Pvt Ltd. This is an open access article under the CC BY license (<http://creativecommons.org/licenses/by/4.0/>) DOI: <http://dx.doi.org/10.22159/ajpcr.2023v16i5.46713>. Journal homepage: <https://innovareacademics.in/journals/index.php/ajpcr>

INTRODUCTION

Intussusception as the name indicates is telescoping of one part into another part of bowel involving either the small intestine or large intestine or both. The most common site of involvement is ileocecal junction while other sites such as ileoileal, jejunojejunal, jejunoileal, lleoileocolic, and colocolonic are known [1,2]. Among children, ileocolic type is most common with approximately constituting about 80% of the cases and the most common reason for bowel obstruction [2] which usually presents as abdominal emergency in early childhood [3]. Abdominal emergency is basically due to invagination of ileum into cecum which in turn compresses the mesentery leading to venous, lymphatic congestion. It ultimately leads to ischemia, perforation, peritonitis, and significant morbidity [4,5]. In such cases, immediate diagnosis and action become a priority. One more atypical sequence in children would be the absence of typical symptoms and the presence of non-specific symptoms such as pain abdomen and vomiting with weakness which may be prominent [3]. In adults, intussusception presents with the classic triad of pain abdomen, vomiting, and blood in the stool, while, in children, this triad is uncommon and seen in <50% of cases complicating the diagnosis process based on physical examination, history, and, thus, the management [6]. Moreover, in infants with <6 months to the child of 36 months, the history is often limited [3], which can compound the difficulty of diagnosis. Intussusception in children is most common in <2 years old. While in United States, the incidence is 56 children per lakh per year [7]. Of these, 60% of cases occur before 1 year of age and 80% before 2 years. Among children < a year, it is more often seen between 5 and 9 months of age, being uncommon in neonates [8]. In most studies, it is more common in males with ratio of 3:2. Among developed nations, such as Europe, North America, and Australia, the incidence of intussusception among infants is between 0.3 and 2.7 cases per 1000 live births [9, 10] which are less compared to developing countries, where the incidence is very high further leading to more complications [11].

In remote areas, due to lack of resources, only radiological evaluation using X-ray abdomen is the first step which gives us an indication for pneumoperitoneum, and appendicolith, since typical radiography signs of intussusception cannot be visualized in all cases, necessitating further evaluation by sonography. In general, surgeons use USG for initial diagnosis and later on do air contrast or barium enema for reduction, or immediate operation if the baby appears to be perforated. However, in cases where risk of perforation is higher with longer duration before presentation despite indeterminate ultrasonographic findings, many clinicians prefer that surgical intervention should be considered alternatively. CT scan can be helpful in accurate assessment, but, in remote areas, these facilities are not available to diagnose intussusception and pneumoperitoneum due to perforation.

Ultrasound (USG) would be best modality for initial screening even in remote areas as it has the advantages of being non-invasive, rapid, and not only cost effective but also avoids radiation exposure and easily available even in peripheral set up in today's era. Moreover, it can be done bedside, even with less experienced readers. Super added, it helps in identifying alternative diagnoses as well as the evaluation of the reducibility of an intussusception, the presence of a lead point mass, and intussusception limited to the small bowel [7,12]. Various review of the literature suggests USG to be of high accuracy, approaching 100% in experienced hands, with sensitivity of 98–100% and specificity of 88–100% [13]. CT is another reliable method for diagnosing intussusception in adults but is not available in remote locations.

CASE SERIES

The detailed basic and clinical profile along with radiological and laparotomy findings, intra-operatively are given in the Table 1.

DISCUSSION

Intussusception is one of the most common abdominal emergencies encountered in pediatric population especially in the age group of

Table 1: Clinico-radiological features in corroboration with intraoperative findings of intussusception in infants

Age	Sex	Clinical profile	Radiological findings	Laparotomy findings (intraoperative)	Management
8 months [Fig. 1]	Male	Pain, abdominal distension, blood and mucus in stools for 3 days	X-ray: Dilated small bowel loops USG-target lesion with crescent in a doughnut and pseudokidney appearance in consistent with ileo-colo-colic intussusception	Long segment ileocolonic and colo-colonic intussusception (terminal ileum into ascending colon and ascending colon into transverse colon) up to mid transverse colon and multiple enlarged mesenteric lymph nodes	Manual reduction by milking of small bowel loops
5 months [Fig. 2]	Male	Vomiting, watery diarrhea and abdominal distension for 2 days	X-ray: Dilated small bowel loops with air fluid levels USG-target lesion with crescent in a doughnut and pseudokidney appearance and mesenteric nodes in crescent in consistent with ileocolic intussusception	Ileocolic intussusception with terminal ileal perforation	Manual reduction and perforation repair
9 months [Fig. 3]	Male	Pain, abdominal distension, blood and mucus in stools for 2 days	X-ray: dilated small bowel loops with air fluid levels USG: target lesion with crescent in a doughnut and pseudokidney appearance and mesenteric nodes in crescent in consistent with ileocolic intussusception	Ileocolic intussusception with contused bowel segment with ileal perforation	Manual reduction with resection of necrosed bowel with ileostomy and mucus fistula

USG: Ultrasound

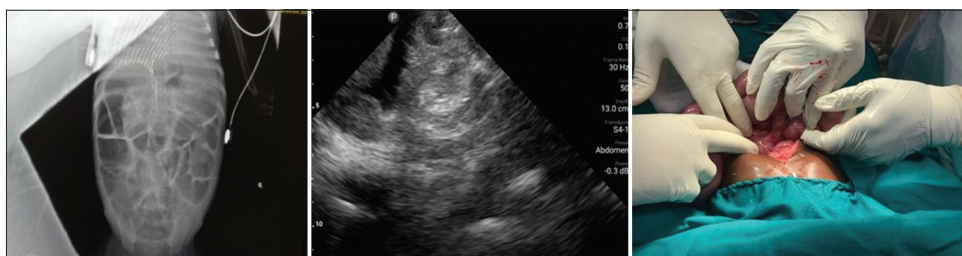


Fig. 1: X-ray, ultrasound, and intraoperative findings of case 1

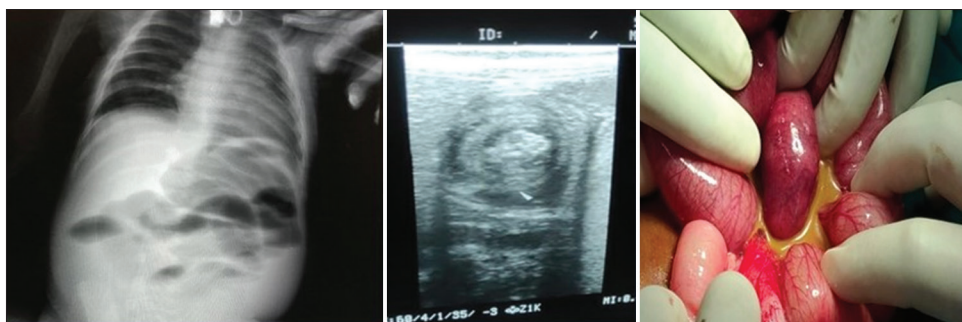


Fig. 2: X-ray, ultrasound, and intraoperative findings of case 2

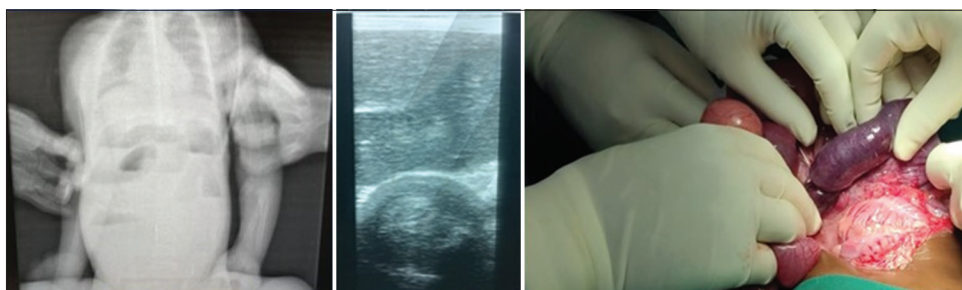

Fig. 3: X-ray, ultrasound, and intraoperative findings of case 3

6 months–3 years in developing countries. Ileocolic intussusception is the most common finding in the published literature. The classical triad of red currant jelly stool, vomiting, and intermittent severe abdominal pain is seen in approximately 20% of the cases. There is always need of a strong clinical suspicion with rapid radiological evaluation for confirming the diagnosis as timely intervention is the utmost priority to prevent morbidity and mortality. Delay in the diagnosis may result into perforation peritonitis leading to difficult invasive management and subsequently prolonged hospital stay in critical care and may prove fatal in many cases. Plain radiographs and ultrasonography are available at most of the places in peripheral set up in today's era. Utilizing ultrasonography as primary screening modality in such cases and abdominal radiography in cases of suspected perforation will reduce the decision time and give the treating physician necessary information required to decide further intervention and course of action decreasing the morbidity and mortality in pediatric population.

Abdominal radiography will not always lead to the conclusive diagnosis of intussusception; however, it is a useful screening tool to look for the signs of bowel obstruction with air fluid levels and dilated loops and paucity of the gas shadows in the right iliac fossa. Sometimes, a mass can be seen in the right upper quadrant with meniscus appearance of bowel. Appendicolith and right lower lobe consolidation mimicking the diagnosis may be identified in some cases. Ultrasonography is a real time examination which is non-invasive, without radiation hazard, readily available round the clock at most of the places and in experience hands has been proven very useful not only for the diagnosis but also for guided reduction depending on the clinical condition of the patient and decision of treating physician.

In our case series study, all the three cases revealed classical USG appearances of pseudokidney appearance on oblique longitudinal scans and crescent in a doughnut on transverse scan. Abdominal lymphadenopathy was observed along with mesenteric crescent. In experienced hands, as per our case series pointing toward novelty, length of segment of bowel telescoping into the other segment can also be assessed, further aiding the surgeon in deciding mode of treatment. In addition to this, predictors of perforation peritonitis such as trapped ascitic fluid and pathological lead points such as duplication cysts, appendix, Meckel's diverticulum, tumors, and lymphadenopathy can be assessed with USG. The review of literature showed that many authors have used USG to maximum extent in intussusception cases like Bartocci *et al.* [14] in their study found out that the USG examination was positive in 16/18 patients with a final diagnosis of intussusception. Dadlani *et al.* [15] concluded in their study that the use of ultrasonography in cases with intussusception has proven to be a reliable and accurate method for diagnosing intussusception. Kim [16] enumerated in their study, the typical and atypical USG features of intussusception. Chukwubike [17] did a correlation study of USG reports and intraoperative findings and concluded USG to be a reliable and accurate diagnostic modality in childhood intussusception. Chang *et al.* [18] found out that emergency physicians with USG training have higher diagnostic sensitivity for pediatric intussusception.

The clinico-radiological findings were corroborated with the intraoperative findings which were consistent and helped the surgeon in deciding the approach and mode of treatment. Bai *et al.*, [19] reported USG-guided hydrostatic reduction in 5218 cases where the success rate was 95.5% with 0.17% perforation rate. Flaum *et al.* [20] in their case series discussed USG-guided hydrostatic reduction of intussusception with low complication rate (1 in 270 cases). Gondek *et al.* [21] discussed the predictive model to detect the success of hydrostatic reduction with approximate success rate of 77%. Menke and Kahl [22], in their study, found out that radiation-free sonography-guided hydrostatic reduction has a good success rate in children with ileocolic intussusception. Pineda and Hardasmalani [23], in their case series, showed that contrast enemas (barium, water-soluble, and air) are diagnostic and therapeutic techniques, with reduction rates of 70–90%. Air enema is now considered the gold standard treatment of intussusception in

children [3]. Surgical intervention is needed only in unstable patients with non-operative reduction contraindications or in prior unsuccessful reduction attempts [24-26]. Limchareon and Boonyarit [27], in their case series, discussed the importance and success rate of hydrostatic reduction as primary modality of treatment. However, in our case series, hydrostatic reduction with normal saline was also tried twice in our Case1. As there were long segments of intussusceptum of terminal ileum telescoping into the ascending colon and further into the transverse colon, hydrostatic reduction was not successful. Based on that experience and with the help of ultrasonographic assessment of long segment length of intussusceptum, exploratory laparotomy was performed to avoid the risk of perforation and further deterioration of patient condition in a peripheral set up with limited resources. The length of intussusceptum segment can be measured approximately on the USG based on the mesenteric crescent from base of intussusception up to the apex (on oblique longitudinal scans), as the mesenteric crescent is not seen at the level of apex (assessment on transverse scan) of intussusception.

CONCLUSION

This article highlights the importance of strong clinical suspicion and timely ultrasonographic evaluation as primary screening modality in suspected cases of intussusception. USG not only confirms the diagnosis with classical signs and appearances but also help rule out other conditions mimicking the diagnosis and will decrease the risk for bowel obstruction, perforation, necrosis, and death by aiding in timely surgical intervention. In addition to this, the lesson learned from this case series is that, assessment of length of segment of bowel telescoping into the other segment will aid in deciding mode of surgical intervention.

ACKNOWLEDGMENTS

Nil.

AUTHORS CONTRIBUTION

All authors have contributed to the preparation of the manuscript.

CONFLICTS OF INTEREST

Nil.

AUTHORS FUNDING

Nil.

REFERENCES

- Walsh D. Intussusception. Society of American Gastrointestinal and Endoscopic Surgeons (SAGES). Available from: <https://www.sages.org/wiki/intussusception> [Last accessed on 2022 Mar 01].
- Williams H. Imaging and intussusception. *Arch Dis Child Educ Pract Ed* 2008;93:30-6. doi: 10.1136/adc.2007.134304, PMID 18208983
- Waseem M, Rosenberg HK. Intussusception. *Pediatr Emerg Care* 2008;24:793-800. doi: 10.1097/PEC.0b013e31818c2a3e, PMID 19018227
- Tareen F, Mc Laughlin D, Cianci F, Hoare SM, Sweeney B, Mortell A, *et al.* Abdominal radiography is not necessary in children with intussusception. *Pediatr Surg Int* 2016;32:89-92. doi: 10.1007/s00383-015-3817-6, PMID 26546340
- Vujović D, Lukac M, Sretenović A, Krstajić T, Ljubić V, Antunović SS. Indications for repeated enema reduction of intussusception in children. *Srp Arh Celok Lek* 2014;142:320-4. doi: 10.2298/sarh1406320v, PMID 25033588
- Daneman A, Alton DJ. Intussusception. Issues and controversies related to diagnosis and reduction. *Radiol Clin North Am* 1996;34:743-56. doi: 10.1016/S0033-8389(22)00506-1, PMID 8677307
- Applegate KE. Clinically suspected intussusception in children: Evidence-based review and self-assessment module. *AJR Am J Roentgenol* 2005;185 Suppl: S175-83. doi: 10.2214/ajr.185.3_supplement.0185s175, PMID 16120899
- Sorantin E, Lindbichler F. Management of intussusception. *Eur Radiol*

- 2004;14 Suppl 4:L146-54. doi: 10.1007/s00330-003-2033-2, PMID 14752570
9. Justice FA, Auld AW, Bines JE. Intussusception: Trends in clinical presentation and management. *J Gastroenterol Hepatol* 2006;21:842-6. doi: 10.1111/j.1440-1746.2005.04031.x, PMID 16704533
 10. Fiegel H, Gfroerer S, Rolle U. Systematic review shows that pathological lead points are important and frequent in intussusception and are not limited to infants. *Acta Paediatr* 2016;105:1275-9. doi: 10.1111/apa.13567, PMID 27588829
 11. Lehnert T, Sorge I, Till H, Rolle U. Intussusception in children—clinical presentation, diagnosis and management. *Int J Colorectal Dis* 2009;24:1187-92. doi: 10.1007/s00384-009-0730-2, PMID 19418060
 12. Justice FA, de Campo M, Liem NT, Son TN, Ninh TP, Bines JE. Accuracy of ultrasonography for the diagnosis of intussusception in infants in Vietnam. *Pediatr Radiol* 2007;37:195-9. doi: 10.1007/s00247-006-0381-1, PMID 17180657
 13. Harrington L, Connolly B, Hu X, Wesson DE, Babyn P, Schuh S. Ultrasonographic and clinical predictors of intussusception. *J Pediatr* 1998;132:836-9. doi: 10.1016/s0022-3476(98)70314-2, PMID 9602196
 14. Bartocci M, Fabrizi G, Valente I, Manzoni C, Specca S, Bonomo L. Intussusception in childhood: Role of sonography on diagnosis and treatment. *J Ultrasound* 2015;18:205-11. doi: 10.1007/s40477-014-0110-9, PMID 26261462
 15. Dadlani A, Lal S, Shahani B, Ali M. Ultrasonography for the diagnosis of intussusception in children: An experience from Pakistan. *Cureus* 2020;12:e9656. doi: 10.7759/cureus.9656, PMID 32923254
 16. Kim JH. US features of transient small bowel intussusception in pediatric patients. *Korean J Radiol* 2004;5:178-84. doi: 10.3348/kjr.2004.5.3.178, PMID 15467415
 17. Chukwubuike KE. Childhood intussusception: Correlation between ultrasound reports and intra-operative findings. *Proc Singapore Healthc* 2021;5:1-5.
 18. Chang YJ, Huang JL, Wu CT, Yan DC, Chao HC, Kong MS. Validation of ultrasound for intussusception at pediatric emergency department. *Pediatr Res* 2011;70:570. doi: 10.1038/pr.2011.795
 19. Bai YZ, Qu RB, Wang GD, Zhang KR, Li Y, Huang Y, et al. Ultrasound-guided hydrostatic reduction of intussusceptions by saline enema: A review of 5218 cases in 17 years. *Am J Surg* 2006;192:273-5. doi: 10.1016/j.amjsurg.2006.04.013, PMID 16920416
 20. Flaum V, Schneider A, Ferreira CG, Philippe P, Sancho CS, Lacreuse I, et al. Twenty years' experience for reduction of ileocolic intussusceptions by saline enema under sonography control. *J Pediatr Surg* 2016;51:179-82. doi: 10.1016/j.jpedsurg.2015.09.022, PMID 26592955
 21. Gondek AS, Riaza L, Cuadras D, Castellarnau XT, Krauel L. Ileocolic intussusception: predicting the probability of success of ultrasound guided saline enema from clinical and sonographic data. *J Pediatr Surg* 2018;53:599-604. doi: 10.1016/j.jpedsurg.2017.10.050, PMID 29150367
 22. Menke J, Kahl F. Sonography-guided hydrostatic reduction of ileocolic intussusception in children: Analysis of failure and success in consecutive patients presenting timely to the hospital. *Eur J Pediatr* 2015;174:307-16. doi: 10.1007/s00431-014-2394-3, PMID 25132464
 23. Pineda C, Hardasmalani M. Pediatric intussusception: A case series and literature review. *Internet J Pediatr Neonatol* 2008;11.
 24. Beasley S. Intussusception. *Pediatr Radiol* 2004;34:302-4. doi: 10.1007/s00247-003-1074-7, PMID 15024529
 25. Daneman A, Navarro O. Intussusception, Part 2: An update on the evolution of management. *Pediatr Radiol* 2004;34:97-108; quiz 187. doi: 10.1007/s00247-003-1082-7, PMID 14634696
 26. Meyer JS, Dangman BC, Buonomo C, Berlin JA. Air and liquid contrast agents in the management of intussusception: A controlled, randomized trial. *Radiology* 1993;188:507-11. doi: 10.1148/radiology.188.2.8327705, PMID 8327705
 27. Limchareon S, Boonyarit A. A nine case series of ultrasound-guided hydrostatic reduction of intussusception by saline enema. *ASEAN J Radiol* 2023;19:61-71. doi: 10.46475/aseanjr.v19i1.23