

## A CASE SERIES ON THE MANAGEMENT OF INTUSSUSCEPTION IN INFANTS: CHALLENGING ENTITY DURING OVERSEAS DEPLOYMENT IN REMOTE AREAS

PRANAV CHANDRAKANT KULKARNI<sup>1\*</sup>, VISHAL VERMA<sup>1</sup>, RAVISHEKAR N HIREMATH<sup>2</sup> , AMIT KAMEWAD<sup>3</sup>, KALE M<sup>3</sup>, NARENDER YADAV<sup>4</sup>, RISHI RAJ<sup>5</sup>

<sup>1</sup>Department of Surgery, AFMS, New Delhi, India. <sup>2</sup>Department of Community Medicine, AFMS, New Delhi, India. <sup>3</sup>Department of Anaesthesiology, AFMS, New Delhi, India. <sup>4</sup>Department of Radiology, AFMS, New Delhi, India, <sup>5</sup>Department of Medical Informatics, AFMS, New Delhi, India.

\*Corresponding author: drpranavkulkarni@gmail.com

Received: 31 October 2022, Revised and Accepted: 06 April 2023

### ABSTRACT

Intussusception is a major cause of acute intestinal obstruction in children. Idiopathic intussusception occurs predominantly under the age of 3 and is rare after the age of 6 years. This paper reports three cases of infant intussusception, including one ileo-ceaco-colic intussusception in an 8-month-old baby boy (an uncommon condition in small infants) treated at the peripheral hospital during deployment in remote settings. This case series highlights diverse signs and symptoms of intussusception, and very few cases present with a typical triad of intussusception (abdominal pain, vomiting, and red currant jelly stool). Strong clinical suspicion is required for the diagnosis of intussusception, especially in a remote peripheral setting where diagnostic facilities are scarce. Furthermore, the surgeon should be ready for a surprise challenge after opening Pandora's box. Delay in diagnosis may result in complications such as perforation, necrosis, and death. An important lesson learned from these three different cases is that the postoperative behavior of surgically reduced intussusception differs from case by case, and we have to be careful and alert during the postoperative period.

**Keywords:** Intussusception, Infants, Intestinal obstruction.

© 2023 The Authors. Published by Innovare Academic Sciences Pvt Ltd. This is an open access article under the CC BY license (<http://creativecommons.org/licenses/by/4.0/>) DOI: <http://dx.doi.org/10.22159/ajpr.2023v16i8.46718>. Journal homepage: <https://innovareacademics.in/journals/index.php/ajpr>

### INTRODUCTION

The term intussusception is a combination of the Latin words Quintus, meaning "within," and susception, meaning "an undertaking" or "to take up." It was first described by Paul Barbet of Amsterdam in 1674 as "introsusception," only to obtain its official moniker over a century later by John Hunter when he encountered three cases [1,2]. The first successful operation on a child with intussusception was performed by Sir Jonathan Hutchinson in 1871 [2]. Intussusception is the most frequent cause of intestinal obstruction in infants and toddlers. Intussusception is defined as the invagination of one segment of the bowel into an immediately adjacent segment. The intussusceptum refers to the proximal segment that invaginates into the distal segment, or the intussusciptens (recipient segment). Intussusception is more common in the small bowel and rarely involves only the large bowel. The natural history of intussusception starts with a lead point, which acts as a focal area of traction that draws the proximal bowel within the peristaltic distal bowel. Symptoms occur due to continued peristaltic contractions of the intussuscepted segment against the obstruction. With continued invagination resulting in edema, eventually the vascular flow to the bowel becomes compromised, resulting in ischemia to the affected segment that, left untreated, can result in necrosis and perforation [3].

Intussusception is a major cause of acute intestinal obstruction in children [4]. Idiopathic intussusception occurs predominantly under the age of 3 and is rare after the age of 6 years. Most patients are well-nourished, healthy infants, and approximately two-thirds are boys. The highest incidence occurs in infants between 4 and 9 months, and it is also the most common cause of small bowel obstruction in this age group. Intussusception is uncommon below 3 months and above 3 years of age [5]. Its incidence worldwide is 1–4 out of every 2000 infants and children. It is most commonly reported in boys at a ratio of 2:1 or 3:2. 75% of cases occur before the age of 2, and more than 40% occur from 3 to 9 months of age [6]. The classic clinical triads of intussusception are colicky abdominal pain, vomiting, and bloody (red currant jelly) stools;

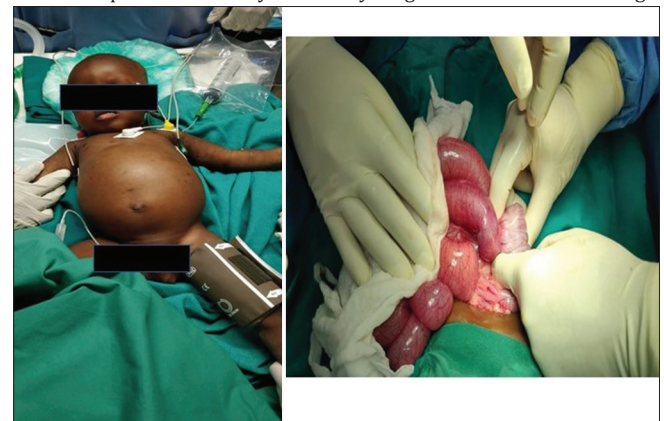however, they are found in only 20% of patients [4]. The majority of pediatric cases (85%) are ileocolic [4]. Others are ileoileocolic (10%), appendicolocolic, cecocolic, colocolic (2.5%), jejunoleocolic, and ileoileal (2.5%) [6]. This article reports three cases of infant intussusception, including one ileo-ceaco-colic intussusception in an 8-month-old baby boy (an uncommon condition in small infants) treated at the peripheral hospital during deployment in remote settings.

### CASE PRESENTATION

Details of all three cases with signs and symptoms, radiological, intra-operative, and post-operative findings are presented in Table 1.

### DISCUSSION

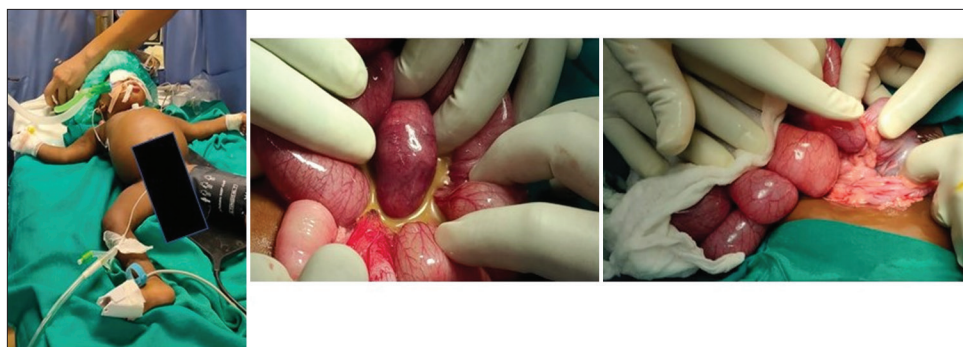
Intussusception is seldomly found in young children between the age



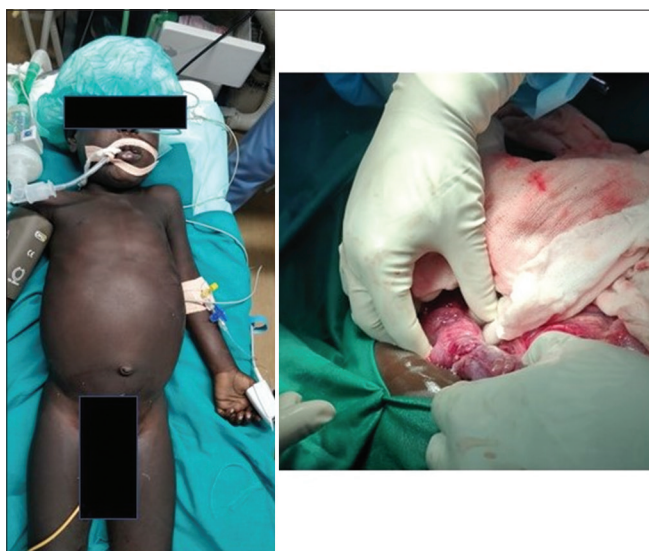**Fig. 1:** Pre-operatively showing distended abdomen and Intra-operatively showing distended abdomen and a large segment of terminal ileum into the Cecum and ascending colon into the transverse colon of case 1

Table 1: Signs and symptoms, radiological, intra-operative and post-operative findings of all three cases

Case No.	Age	Fever	Presentation	Examination	X-ray	USG	Intra operative findings	Post-operative findings
1	8 months	No Fever	Drowsy, dehydrated, loose stools with blood, abdominal distention for 4 days	Abdomen was soft with absent bowel sounds and no mass per abdomen palpable	Dilated small bowels with intestinal obstruction	Donut sign suggestive of intussusception (? ileo-colic)	Two trials of saline enema hydrostatic reduction were given but failed. Exploratory laparotomy done, intra-operatively there was large segment of terminal ileum into the caecum and ascending colon into the transverse colon. Manual milking of bowel segments done, and viability of bowel checked (Fig. 1).	Post-operative period was uneventful, and child discharged on 5 <sup>th</sup> post-operative day.
2	5 months	Fever (101F)	Blood mixed with loose stools, abdominal distention for 3-4 days	Abdomen was distended, soft, bowel sounds sluggish, no mass palpable in abdomen	Dilated bowel loops with features suggestive of Sub-acute intestinal obstruction	Donut sign suggestive of intussusception	Emergency laparotomy done. Intraoperatively there was ileo colic intussusception with concealed ileal perforation. After reduction, Primary repair of perforation was done (Fig. 2).	Post-operative period was uneventful, and patient discharged.
3	9 months	No fever	Diarrhoea with blood and mucus, vomiting for 4 days	Abdominal distention, soft, mass palpable in RUQ, empty RLQ	Dilated bowel loops with multiple air fluid levels. X-ray on post-operative day 5 showed gas under diaphragm suggestive of perforation of bowel	Donut sign suggestive of intussusception	Laparotomy done, intraoperative findings - ileo-ileo-colic intussusception, no perforation noted. Terminal ileum regained its vasculature and colour after pouring warm saline. Resection of bowel avoided (Fig. 3).	Post operatively baby was fine TLC count increased, x-ray abdomen suggestive of perforation. Re-exploration of the abdomen done, intraoperatively, there was perforation of ileum with fecal contamination of cavity. Resection of affected bowel done followed by defunctioning ileostomy and mucus fistula. Post-operative period uneventful and child discharged on 5 <sup>th</sup> day.



**Fig. 2: Pre-operatively showing distended abdomen and Intra-operative findings of concealed ileal perforation showing fecal matter in the abdomen and ileocolic intussusception of case 2**



**Fig. 3: Pre-operatively showing distended abdomen and Intra-operatively showing ileo-ileocolic intussusception with no perforation of case 3**

have a “lead point” or specifically identified cause, such as Meckel’s diverticulum, duplications, polyposis, and lymphomas (in decreasing order of incidence) [7]. In our peripheral setup, we had these three cases of abdominal obstruction. It was very difficult for us to confirm the diagnosis of intussusception after clinical suspicion as we only had a mini-portable ultrasound machine. Furthermore, we did not have any experience operating on such young infants. Thus, this was the firsthand experience with which we had undertaken to operate on these children, as it was a life-saving measure. In the first case, we first tried saline enema hydrostatic reduction, which failed twice, and then intraoperatively, there was a large segment of terminal ileum invaginated into the caecum and the whole ascending colon again invaginated into the transverse colon up to mid-point. In the second case, there was concealed perforation of the ileum, and the primary repair of the perforation was done by us. In the third case, there was also ileal-colic intussusception; the ileal segment intussusceptum was decompressed initially, but after warm saline pouring, it regained its vascularity and color. As there was no perforation, we avoided resection of the bowel. However, during the postoperative period, on the 6<sup>th</sup> day, the child had a fever, his abdominal girth increased, and the x-ray showed pneumoperitoneum. Thus, re-exploration was carried out, which showed perforation of the ileum and fecal contamination of the cavity. Hence, we did a resection of the bowel and an end ileostomy with a mucus fistula. Thus, managing these three cases in a remote setting was challenging, starting from the confirmation of the diagnosis until the recovery of the infants. An important lesson learned from these three

different cases is that the postoperative behavior of surgically reduced intussusception differs from case by case, and we have to be careful and alert during the postoperative period. Recurrent intussusception is present in only 5–8% of children and is most common after hydrostatic versus surgical reduction. Fifty percent of recurrent intussusception cases occur within 48 h of a prior episode (but have been reported up to 18 months later) [8]. Most postoperative intussusception cases are in the small bowel [9].

Pineda and Hardasmalani [7] in their case series tried contrast enemas (barium, water-soluble, air) as a therapeutic and diagnostic technique, but in our case, as we are located in remote peripheral settings, the only options were diagnostic ultrasound and open laparotomy as a therapeutic technique. Makrinioti *et al.* [10] describe a possible association between SARS-CoV-2 infection and intussusception in their article, but in our cases, no such history or confirmation was available. A multi-institutional retrospective study of intussusception by Banapour *et al.* [11] suggested that increasing age is associated with a higher likelihood of finding a pathological lead point such as reckless diverticulum, lymphoid hyperplasia, inspissated appendicular mass, etc., but in our cases, we did not find any leading point as a cause for intussusception. Mappiwali *et al.* [12] in their case report found the cecal diverticulum as a lead point for intussusception, and they performed wedge resection of the diverticulum, but in our case, no such findings were found.

A retrospective study done by Madan *et al.* [13] concludes that most of the intussusceptions that came as surgical emergencies in their institute were managed non-operatively. About 89% of cases were below 3 years of age, and no seasonal variation was demonstrated. In our setup, we tried the non-operative method for the first case, but it failed to reduce. Possible reasons were delayed presentation and a long segment with complex intussusception. In the second and third cases, preoperatively on ultrasound, we found a large segment of the small bowel as intussusceptum, and the child presented lately within 4–5 days of presentation; hence, we decided to do laparotomy at the first go.

#### CONCLUSION

This case study highlights diverse signs and symptoms of intussusception, and very few cases present with a typical triad of intussusception (abdominal pain, vomiting, and red currant jelly stool). Strong clinical suspicion is required for the diagnosis of intussusception, especially in a remote peripheral setting where diagnostic facilities are scarce. Furthermore, the surgeon should be ready for a surprise challenge after opening Pandora’s box. A delay in diagnosis may result in complications such as perforation, necrosis, and death.

#### CONFLICTS OF INTERESTS

The authors declared no conflicts of interest.

**AUTHORS FUNDING**

The study was not supported by any grants and funds.

**REFERENCES**

1. Honjo H, Mike M, Kusanagi H, Kano N. Adult intussusception: A retrospective review. *World J Surg* 2015;39:134-8. doi: 10.1007/s00268-014-2759-9, PMID 25192846
2. Yalamarthy S, Smith RC. Adult intussusception: Case reports and review of literature. *Postgrad Med J* 2005;81:174-7. doi: 10.1136/pgmj.2004.022749, PMID 15749793
3. Marsicovetere P, Ivatury SJ, White B, Holubar SD. Intestinal intussusception: Etiology, diagnosis, and treatment. *Clin Colon Rect Surg* 2017;30:30-9. doi: 10.1055/s-0036-1593429, PMID 28144210
4. Singhal BM, Kaval S, Sagar S, Kumar V. Ileoileal intussusception due to Meckel's diverticulum: An uncommon aetiology. *OA Surgery* 2013;1:2.
5. Huppertz HI, Soriano-Gabarró M, Grimprel E, Franco E, Mezner Z, Desselberger U, *et al.* Intussusception among young children in Europe. *Pediatr Infect Dis J* 2006;25:1 Suppl: S22-9. doi: 10.1097/01.inf.0000197713.32880.46, PMID 16397426
6. Guerrero I, Ramirez-Patiño L. Intussusception secondary to Meckel's diverticulum in a 3-month-old girl: Case report. *Rev Med Hosp Gen Mex* Available from: <https://cyberleninka.org/article/n/655132/viewer> [Last accessed on 2022 Jul 25].
7. Pineda C, Hardasmalani M. Pediatric intussusception: A case series and literature review. *Internet J Pediatr Neonatol* 2008;11:1.
8. Daneman A, Alton DJ, Ein S, Wesson D, Superina R, Thorne P. Perforation during attempted intussusception reduction in children—a comparison of perforation with barium and air. *Pediatr Radiol* 1995;25:81-8. doi: 10.1007/BF02010311, PMID 7596670
9. Navarro O, Daneman A. Intussusception. Part 3: Diagnosis and management of those with an identifiable or predisposing cause and those that reduce spontaneously. *Pediatr Radiol* 2004;34:305-12, quiz 369. doi: 10.1007/s00247-003-1028-0, PMID 14534754
10. Makrinioti H, MacDonald A, Lu X, Wallace S, Jobson M, Zhang F, *et al.* Intussusception in 2 children with severe acute respiratory syndrome Coronavirus-2 infection. *J Pediatr Infect Dis Soc* 2020;9:504-6. doi: 10.1093/jpids/piaa096, PMID 32770243
11. Banapour P, Sydorak RM, Shaul D. Surgical approach to intussusception in older children: Influence of lead points. *J Pediatr Surg* 2015;50:647-50. doi: 10.1016/j.jpedsurg.2014.09.078, PMID 25840080
12. Mappiwali A, Habar TR, Mariana N, Sulmiati FA, Fitri AW. Ileocolic intussusception secondary to caecal diverticulum in a 4-month-old boy. *J Pediatr Surg Case Rep* 2020;60:101550. doi: 10.1016/j.epsc.2020.101550
13. Madan AJ, Haider F, Alhindi S. Profile and outcome of pediatric intussusception: A 5-year experience in a tertiary care center. *Ann Pediatr Surg* 2021;17:31. doi: 10.1186/s43159-021-00097-5