

## FUNCTIONAL OUTCOME OF ARTHROSCOPIC ASSISTED MINI OPEN ROTATOR CUFF TEAR REPAIR

KAPIL GHORPADE, JAYDEEP PATIL, TANISH PATIL, SHOURYASHIL KHAMBALKAR\*

Department of Orthopaedics, Prakash Institute of Medical Sciences and Research, Urun Islampur Dist Sangli Maharashtra India.  
Email: khambalkar04@gmail.com

Received: 12 February 2023, Revised and Accepted: 28 March 2023

### ABSTRACT

**Objective:** The aim of the study was to analyze the functional outcome of patients with rotator cuff injuries treated by arthroscopically-assisted mini-open repair.

**Methods:** This was a prospective and cohort study conducted in the Department of Orthopaedics of Prakash Institute of Medical Sciences (PIMS) and Research, Urun Islampur Dist Sangli. Forty patients with rotator cuff injuries treated by arthroscopic assisted mini open rotator cuff tear repair were included in this study on the basis of a predefined inclusion and exclusion criteria. Post-surgery patients were followed up for 6 months. At each follow-up visit, functional outcome was assessed by Constant Score (CS) and University of California-Los Angeles (UCLA) shoulder scale. For statistical purpose, SSPS 21.0 software was used and  $p < 0.05$  was taken as statistically significant.

**Results:** A total of 40 patients were included in this study out of which there were 23 (57.50 %) males and 17 (42.50 %) females with a M:F ratio of 1:0.73. The mean age of affected patients was found to be  $57.07 \pm 11.31$  years. The most common cause of rotator cuff tear was degenerative changes which was seen in 19 (47.50%) patients followed by spontaneous rotator cuff tear (30.00%) and traumatic rotator cuff injury (22.50%). There was significant functional improvement from pre-operative to last follow-up period as shown by improved CS and UCLA scores ( $p < 0.05$ ).

**Conclusion:** Arthroscopic assisted mini-open surgery for rotator cuff injuries is found to have excellent results in terms of functional outcome.

**Keywords:** Rotator cuff injuries, Degenerative changes, Constant score, UCLA, Functional outcome.

© 2023 The Authors. Published by Innovare Academic Sciences Pvt Ltd. This is an open access article under the CC BY license (<http://creativecommons.org/licenses/by/4.0/>) DOI: <http://dx.doi.org/10.22159/ajpcr.2023v16i5.48102>. Journal homepage: <https://innovareacademics.in/journals/index.php/ajpcr>

### INTRODUCTION

Shoulder joint is known to be most mobile joint of the body but with this increased mobility comes the inherent instability [1]. The combination of increased mobility and decreased stability makes it vulnerable for injuries as well as dislocation. Shoulder comprises of acromioclavicular (AC) joint, scapulothoracic joint (ST), and glenohumeral joint (GH). These joints and their articulations are responsible for shoulder motion [2]. The smaller glenoid area is compensated by cartilaginous labrum which is responsible for formation of socket of shoulder joint and is responsible for increase in surface area for humeral head to make a contact with. In addition to cartilaginous labrum rotator cuff also acts a great stabilizer of shoulder joint and comes under the category of dynamic stabilizer [3]. The rotator cuff consists of four muscles, namely, the supraspinatus, infraspinatus, subscapularis, and teres minor. Among these four muscles, the supraspinatus is the main supporting muscle of the rotator cuff complex. The main function of the rotator cuff is to stabilize the GH joint so that the larger shoulder joint attains mobility for carrying out function. Increased movement causes shearing forces across the joint and may result impingement on the rotator cuff muscles and tendons [4].

With increasing age, rotator cuff injuries are common. Increasing age is associated with age related degenerative process in muscle tendons that are part of rotator cuff that predisposes an individual for development of rotator cuff injuries. The other contributing factors for rotator cuff injuries include compromised microvascular supply and outlet impingement [5]. Sports related rotator cuff injuries are usually due to overuse and may be seen in individuals engaging in sports such as cricket, tennis, basketball, and golf. Rotator cuff injuries are also common after falls and collision seen in sports such as football and hockey. Irrespective of the mechanism of injury rotator cuff injuries commonly presents as pain on motion, weakness on overhead abduction,

limited motion secondary to pain, and clicking sound on motion [6]. On inspection, there can be deltoid and infraspinatus atrophy, on palpation localized tenderness may be observed at subacromial bursa and a decreased range of motion in affected shoulder and weakness of supraspinatus and infraspinatus checked by Jobes empty can test and external rotator weakness, respectively. The diagnosis is confirmed on the basis of imaging techniques. On X-ray rotator, cuff injuries may present as narrowed acromio-humeral distance. However, X-ray is not a sensitive technique and magnetic resonance imaging can reliably diagnose rotator cuff injuries [7].

The conservative management usually consists of rest, non-steroidal anti-inflammatory drugs, and local injection of steroids [8]. Physiotherapy can also play a key role in maintenance phase. Full thickness rotator cuff tear usually requires surgical intervention and has been treated traditionally by open surgical repair [9]. Open surgical repair though found to have good results in terms of functional outcome pain persisted in many cases. To reduce pain as well as morbidity associated with open repair less invasive surgical techniques such as arthroscopically-assisted mini-open repair, as well as completely arthroscopic techniques are being increasingly employed [10]. These techniques are less invasive and reported to have excellent functional outcome and significantly reduced severity as well as duration of pain [11].

We conducted this study to analyze the functional outcome of patients with rotator cuff injuries treated by arthroscopically-assisted mini-open repair.

### METHODS

The study was a prospective and cohort study conducted in the Department of Orthopaedics of Prakash Institute of Medical Sciences

(PIMS) and Research, Urun Islampur Dist Sangli. Forty patients with rotator cuff injuries treated by arthroscopic assisted mini open rotator cuff tear repair were included in this study on the basis of a predefined inclusion and exclusion criteria. Institutional ethical committee approved the study. Informed written consent was obtained from all the participants of the study. Demographic details such as age, gender, and area of residence was noted. A detailed history was taken in all patients in terms of cause as well as mechanism of injury, duration since injury, and in old patients history of similar episodes of pain and restricted range of motion in past. A detailed clinical examination was done in all the cases so as to find out presence of swelling, severity of pain, and range of motion and amount of rotator cuff weakness. Functional evaluation of affected shoulder was done by Constant Score [12]. University of California-Los Angeles (UCLA) shoulder scale [13]. The diagnosis of rotator cuff injuries was confirmed by magnetic resonance imaging. Rotator cuff injuries were classified as full or partial thickness tears. Partial thickness tears were further classified as articular surface or bursal surface depending on location of tear. All patients in whom surgical intervention was planned underwent investigations such as complete blood count, kidney function tests (Blood urea, and serum creatinine levels), Hepatic function test (Serum Bilirubin, SGOT, and SGPT), Blood group and Rh typing, bleeding time, clotting time, and prothrombin time. Pre-anesthetic evaluation was done.

### Surgical technique

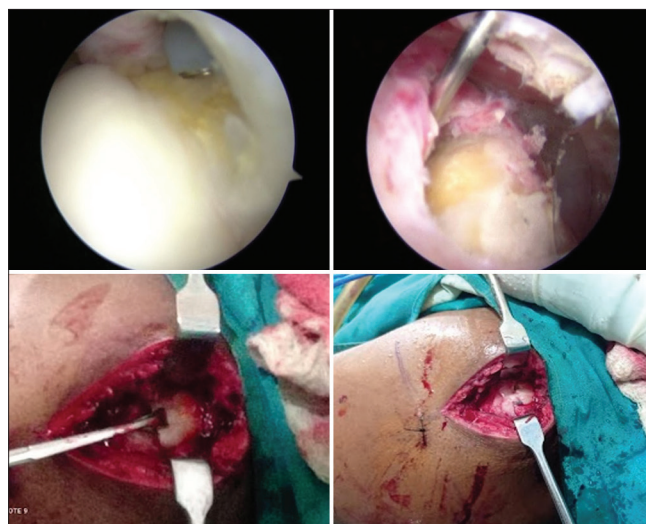
Patient positioned supine in semi beach chair position. Affected shoulder was then scrubbed painted and draped under aseptic precautions. Bony prominences identified and surface markings were done. Classical posterior portal was then taken. Diagnostic shoulder arthroscopic examination was done to evaluate intra articular pathologies and to check status of labrum, Biceps insertion, subscapularis insertion, and status of footprints of supraspinatus and infraspinatus tendons.

In cases with partial articular surface tear, a marker stitch was placed with 2.0 ethilon through 18 g spinal needle during shoulder arthroscopy to identify tear during subacromial scopy. Then, subacromial arthroscopy followed by subacromial bursectomy was done. Acromioplasty was done in cases with Type 2 acromion. Supraspinatus and infraspinatus tear were identified and torn edges were freshened and footprint preparation was done. Tear marked with 18 g spinal needle keeping arm in adduction and neutral rotation. Then, according to spinal needle position, a 3–4 cm incision was taken, Deltoid split done followed by subdeltoid bursectomy. Anchor position was then marked and one or two double loaded 5.5 mm PEEK or Titanium anchors were used according to size of tear. Medialisation of repair was done nearer to articular margins to achieve low tension single row repair. Anchor placement was done; suture shuttling device was used to take deep bites in supraspinatus and infraspinatus tendons. Finally, from posterior to anterior sliding knots were placed over which five half hitches were placed with help of knot pusher to achieve knot position on bursal surface. After carefully checking strength of repair by hook probe, microfractures done on footprint area with 2.5 mm k wire to enhance healing.

Deltoid split closure was done with no 1 Vicryl intermittent sutures. Subcutaneous closure was done with 2.0 vicryl. Skin closure was done with 2.0 ethilon. Adhesive dressing was applied and patient was discharged 3 days after surgery. After surgery patients shoulder was immobilized with shoulder immobilizer for 6 weeks. Pendulum exercises were started after 4 weeks. Patients were discharged 3 days after surgical procedure with a follow-up advice at 4 weeks, 6 weeks, 12 weeks, and 6 months (Fig. 1).

At each follow-up, functional assessment of patients was done by UCLA. The functional outcome was labeled as excellent, good, fair, or poor on the basis of UCLA score.

Sample size was calculated according to the previous reference studies, when surgical repair of rotator cuff injuries was studied, as the main



**Fig. 1: Arthroscopic assisted mini-open repair of rotator cuff tears. Identification of PASTA tear (left upper) identification of tear with 18 g needle (right upper) approach and exposure of tear (left lower) repaired rotator cuff (right lower)**

result in the event of at least 35 patients was calculated by Open Epi-Version 3 online software, a 10% difference could be determined between the group at 80% power and 5% significance ( $\alpha=0.05$ ,  $\beta=0.80$ ). For statistical purposes, SSPS 21.0 software was used. Microsoft Excel was used for preparation of charts and graphs.  $p<0.05$  was taken as statistically significant.

### Inclusion criteria

The following criteria were included in the study:

- Patients with supraspinatus and infraspinatus tear.
- Small and medium tears up to 3 cm size.
- Grade 1 or Grade 2 retracted tear.
- Age between 18 and 70 years.
- Patients willing to give informed written consent to be part of study.

### Exclusion criteria

The following criteria were excluded from the study:

- Refusal to give consent.
- Associated subscapularis tear
- Moderate and massive tears size more than 3 cm
- More than Grade 2 retracted tear
- Patients with history of fracture involving humerus, scapula, or clavicle on ipsilateral side
- Any previous surgical intervention in same shoulder.

### RESULTS

This study was conducted to analyze functional outcome of patients with rotator cuff injuries who had undergone arthroscopic assisted mini-open repair. A total of 40 patients were included in this study out of which there were 23 (57.50%) males and 17 (42.50%) females with a M: F ratio of 1:0.73 (Fig. 2).

The most common affected age group was between the age of 61–70 years (52.50%) followed by 51–60 years (22.50%) and 41–50 years (17.50%) It was found to be less common in patients below 40 years (7.5%). The mean age of affected patients was found to be  $57.07\pm 11.31$  years (Table 1).

The mean age of male ( $58.04\pm 8.98$  years) as well as female ( $56.10\pm 9.12$  years) were found to be comparable with no statistically significant difference in the age group of males and females ( $p=0.5368$ ) (Table 2).

Table 1: Comparison of gender wise age distribution

Age groups	Males		Females		Total	
	No of cases	Percentage	No of cases	Percentage	No of cases	Percentage
30 years or less	1	2.50%	0	0.00%	1	2.50
31-40 years	1	2.50%	1	2.50%	2	5.00
41-50 years	4	12.50%	3	5.00%	7	17.50
51-60 years	6	17.50%	3	5.00%	9	22.50
61-70 years	11	35.00%	10	17.50%	21	52.50
Total	23	70.00%	17	30.00%	40	100.00

Mean age=57.07±11.31 years

Table 2: Gender wise distribution of the mean age of the patients

Gender	Mean age	SD	Test of significance
Males	58.04	8.98	p=0.5368
Females	56.10	9.12	Not Significant

Table 3: Etiology, side and degree of tears in rotator cuff injuries

Rotator cuff tears	No of cases	Percentage
Etiology		
Degenerative changes	19	47.50
Spontaneous tear	12	30.00
Traumatic tear	9	22.50
Side of tear		
Right	25	62.50
Left	15	37.50
Degree of tear		
Complete	29	72.50
Partial	11	27.50

The analysis of the patients on the basis of etiology showed that out of 40 patients the most common cause of rotator cuff tear was degenerative changes which were seen in 19 (47.50%) patients followed by spontaneous rotator cuff tear (30.00%) and traumatic rotator cuff injury (22.50%). Right and left rotator cuff tears were seen in 25 (62.50%) and 15 (37.50%) patients, respectively. Twenty-nine (72.50%) patients had complete tears whereas partial tears were seen in 11 (27.50%) (Table 3).

At the time of presentation, the functional assessment was done using Constant Score (CS) as well as UCLA score. Patients were followed up at 6 weeks 12 weeks and 6 months and during each follow-up visit functional assessment was done using CS as well as UCLA score.

At the time of presentation, the mean constant score of the patients was found to be 36.24±8.12. At 6 weeks postoperatively the mean CS was found to be 48.62±11.58. At 12 weeks and 6 months postoperatively, the mean CS score was found to be 62.46±9.20 and 82.46±12.48. The difference between preoperative CS score and CS score at the time of final follow up showed that there was a significant functional improvement in studied cases. The CS score improved from 36.24 (preoperatively) to 82.46 (last follow-up). The difference was found to be statistically significant (p<0.05) (Fig. 3).

At the time of presentation, the mean UCLA score of the patients was found to be 19.24±6.46. At 6 weeks postoperatively, the mean UCLA score was found to be 25.34±7.64. At 12 weeks and 6 months postoperatively, the mean ULCA score was found to be 29.46±6.20 and 33.84±4.22. The difference between pre-operative UCLA score and UCLA score at the time of final follow-up showed that there was a significant functional improvement in studied cases. The UCLA score improved from 19.24 (preoperatively) to 33.84 (last follow-up). The difference was found to be statistically significant (p<0.05) (Fig. 4).

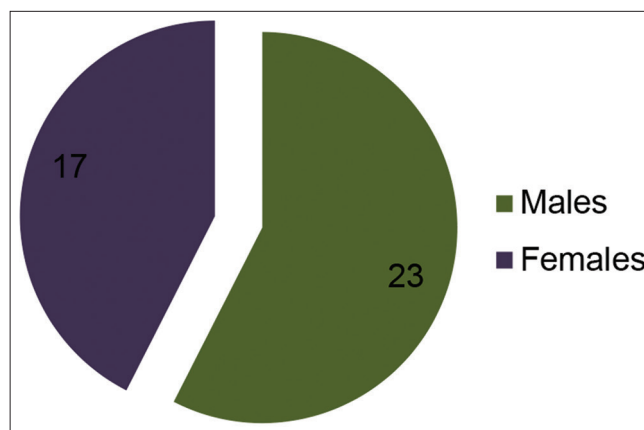


Fig. 2: Gender distribution of the studied cases

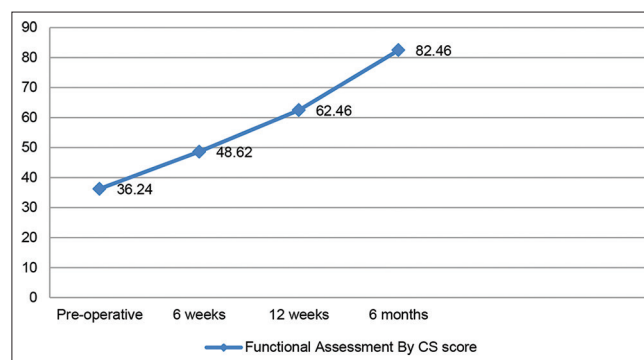


Fig. 3: Functional assessment of outcome assessed by CS score

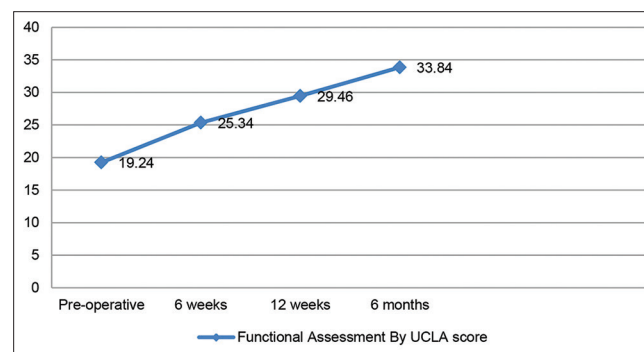


Fig. 4: Functional assessment of outcome assessed by UCLA score

DISCUSSION

We conducted this study of 40 patients with rotator cuff injury who had been treated with arthroscopically assisted mini open technique of rotator cuff repair. In our study, there were 23 (57.50%) males and



17 (42.50%) females with a M:F ratio of 1:0.73. The male preponderance can be explained because males are more likely to be affected in cases of traumatic rotator cuff injuries. Salvio *et al.* conducted a study to evaluate the functional outcome of shoulder after open rotator cuff repair [14]. In this study, 26 patients with rotator cuff injuries treated by mini open technique were included in the study. Out of 26 patients, there were 14 (53.8%) males and 12 (46.2%) females. The male preponderance in cases of rotator cuff tears were also reported by the authors such as Razmjou *et al.* [15]. and Motabar *et al.* [16].

Most common affected age group was between the age of 61–70 years (52.50%) followed by 51–60 years (22.50%) and 41–50 years (17.50%) It was found to be less common in patients below 40 years (7.5%). The mean age of affected patients was found to be 57.07±11.31 years. Yamaguchi *et al.* conducted a study to compare the morphological characteristics and prevalence of asymptomatic and symptomatic rotator cuff disease in patients who presented with unilateral shoulder pain [17]. Five hundred and eighty-eight consecutive patients in whom a standardized ultrasonographic study had been performed by an experienced radiologist for the assessment of unilateral shoulder pain were evaluated with regard to the presence and size of rotator cuff tears in each shoulder. The mean age of the patients in this study was found to be 58.7 years for the patients with unilateral rotator cuff tear. Similar age of the affected cases was also reported by the authors such as Keener *et al.* [18] and Gombera *et al.* [19].

In our study out of 40 patients, the most common cause of rotator cuff tear was degenerative changes which was seen in 19 (47.50%) patients followed by spontaneous rotator cuff tear (30.00%) and traumatic rotator cuff injury (22.50%). Abechain *et al.* conducted a study to compare the functional outcomes of traumatic and non-traumatic rotator cuff tears after arthroscopic repair [20]. Of the 87 patients who underwent rotator cuff repairs, 35 had traumatic tears and 52 had non-traumatic tears. In patients with non-traumatic tears, the average age was 59 years, 74.5% were female, 96.1% were right-hand dominant, and 92.3% had their dominant shoulder affected. Predominance of non-traumatic causes of rotator cuff tears seen in this study was similar to our study. Similar predominance of non-traumatic causes of rotator cuff tears was also reported by the authors such as Harryman *et al.* [21] and Kluger *et al.* [22].

Finally, the functional assessment of patients at, 6 weeks, 12 weeks, and 6 months after surgery showed that there was a significant functional improvement in patients after arthroscopic assisted mini-open surgery. At the time of presentation, mean CS and UCLA scores were found to be 36.24±8.12 and 19.24±6.46. The final mean CS and UCLA scores at final follow-up (6 months after surgery) were found to be 82.46 and 33.84. There was considerable improvement in CS and UCLA score and the improvement was found to be statistically significant ( $p < 0.05$ ). Demirhan *et al.* conducted a study to assess outcome of patients with rotator cuff injury who had been treated with arthroscopically assisted mini open technique of rotator cuff repair [23]. Twenty-five patients (81%) achieved excellent or good results and 6 patients (19%) had satisfactory results. The mean constant score at final follow-up was 84.6. Arthroscopic capsular release followed by a heavy exercise program enabled him to return to his former sports activity level within 3 months. Similar good functional outcome was also reported by the authors such as van Deurzen *et al.* [24] and Bell *et al.* [25].

## CONCLUSION

Patients having traumatic as well as non-traumatic rotator cuff injuries and treated by arthroscopic assisted mini open rotator cuff repair show significant improvement in functional outcome as assessed by improved CS and UCLA scores.

## AUTHORS' CONTRIBUTION

KG: Concept and design of the study; prepared first draft of manuscript, and interpreted the results; JP: reviewed the literature and manuscript

preparation; TP: Concept, coordination, review of literature, and manuscript preparation; SK: Statistically analyzed and interpreted, preparation of manuscript, and revision of the manuscript.

## CONFLICTS OF INTEREST

None.

## AUTHORS' FUNDING

None.

## REFERENCES

1. Labriola JE, Lee TQ, Debski RE, McMahon PJ. Stability and instability of the glenohumeral joint: The role of shoulder muscles. *J Shoulder Elbow Surg* 2005;14(1 Suppl S):32S-8. doi: 10.1016/j.jse.2004.09.014, PMID 15726085
2. Jansen T, Thorns C, Oestern HJ. Anatomy of the shoulder joint. *Zentralbl Chir* 2001;126:168-76. doi: 10.1055/s-2001-12501, PMID 11301881
3. Lugo R, Kung P, Ma CB. Shoulder biomechanics. *Eur J Radiol* 2008;68:16-24. doi: 10.1016/j.ejrad.2008.02.051, PMID 18511227
4. Klement C, Prinold JA, Morgans S, Smith SH, Nolte D, Reilly P, *et al.* Analysis of shoulder compressive and shear forces during functional activities of daily life. *Clin Biomech (Bristol, Avon)* 2018;54:34-41. doi: 10.1016/j.clinbiomech.2018.03.006, PMID 29550641
5. Garving C, Jakob S, Bauer I, Nadjar R, Brunner UH. Impingement syndrome of the shoulder. *Dtsch Arztebl Int* 2017;114:765-76. doi: 10.3238/arztebl.2017.0765, PMID 29202926
6. Manske R, Ellenbecker T. Current concepts in shoulder examination of the overhead athlete. *Int J Sports Phys Ther* 2013;8:554-78. PMID 24175138
7. Sharma G, Bhandary S, Khandige G, Kabra U. MR imaging of rotator cuff tears: Correlation with arthroscopy. *J Clin Diagn Res* 2017;11:TC24-7. doi: 10.7860/JCDR/2017/27714.9911, PMID 28658874
8. Sun Y, Chen J, Li H, Jiang J, Chen S. Steroid injection and nonsteroidal anti-inflammatory agents for shoulder pain: A PRISMA systematic review and meta-analysis of randomized controlled trials. *Med (Baltim)* 2015;94:e2216. doi: 10.1097/MD.0000000000002216, PMID 26683932
9. Di Benedetto P, Mancuso F, Tosolini L, Buttironi MM, Beltrame A, Causero A. Treatment options for massive rotator cuff tears: A narrative review. *Acta Biomed* 2021;92(S3):e2021026. doi: 10.23750/abm.v92iS3.11766, PMID 34313657
10. Baker CL, Whaley AL, Baker M. Arthroscopic rotator cuff tear repair. *J Surg Orthop Adv* 2003 Winter;12:175-90. PMID 15008280
11. van der Meijden OA, Westgard P, Chandler Z, Gaskill TR, Kokmeyer D, Millett PJ. Rehabilitation after arthroscopic rotator cuff repair: Current concepts review and evidence-based guidelines. *Int J Sports Phys Ther* 2012;7:197-218. PMID 22530194
12. Constant CR, Gerber C, Emery RJ, Søbjerg JO, Gohlke F, Boileau P. A review of the Constant score: Modifications and guidelines for its use. *J Shoulder Elbow Surg* 2008;17:355-61. doi: 10.1016/j.jse.2007.06.022, PMID 18218327
13. Thamyongkit S, Wanitchanon T, Chulsomlee K, Tuntiyatorn P, Vasaruchapong S, Vijitrakamrungs C, *et al.* The University of California-Los Angeles (UCLA) shoulder scale: Translation, reliability and validation of a Thai version of UCLA shoulder scale in rotator cuff tear patients. *BMC Musculoskelet Disord* 2022;23:65. doi: 10.1186/s12891-022-05018-0, PMID 35042509
14. Savio A, Nishara MS. Functional outcome of patients undergoing open rotator cuff repair. *Int J Res Orthop* 2020;6:1082-6. doi: 10.18203/issn.2455-4510.intjresorthop20203733
15. Razmjou H, Holtby R, Myhr T. Gender differences in quality of life and extent of rotator cuff pathology. *Arthroscopy* 2006;22:57-62. doi: 10.1016/j.arthro.2005.10.014, PMID 16399462
16. Motabar H, Nimbarde AD. Sex differences in rotator cuff muscles' response to various work-related factors. *IJSE Trans Occup Ergon Hum Factors* 2021;9:1-12. doi: 10.1080/24725838.2021.1931562, PMID 34011247
17. Yamaguchi K, Ditsios K, Middleton WD, Hildebolt CF, Galatz LM, Teefey SA. The demographic and morphological features of rotator cuff disease. A comparison of asymptomatic and symptomatic shoulders. *J Bone Joint Surg Am* 2006;88:1699-704. doi: 10.2106/JBJS.E.00835, PMID 16882890
18. Keener JD, Wei AS, Kim HM, Steger-May K, Yamaguchi K. Proximal humeral migration in shoulders with symptomatic and asymptomatic rotator cuff tears. *J Bone Joint Surg Am* 2009;91:1405-13. doi: 10.2106/

- JBJS.H.00854, PMID 19487518
19. Gombera MM, Sekiya JK. Rotator cuff tear and glenohumeral instability: A systematic review. *Clin Orthop Relat Res* 2014;472:2448-56. doi: 10.1007/s11999-013-3290-2, Erratum in: *Clin Orthop Relat Res*. Gomberawalla, M Mustafa [corrected to Gombera, Mufaddal Mustafa]. 2015;473:751.
  20. Abechain JJ, Godinho GG, Matsunaga FT, Netto NA, Daou JP, Tamaoki MJ. Functional outcomes of traumatic and non-traumatic rotator cuff tears after arthroscopic repair. *World J Orthop* 2017;8:631-7. doi: 10.5312/wjo.v8.i8.631, PMID 28875129
  21. Harryman DT 2<sup>nd</sup>, Mack LA, Wang KY, Jackins SE, Richardson ML, Matsen FA 3<sup>rd</sup>. Repairs of the rotator cuff. Correlation of functional results with integrity of the cuff. *J Bone Joint Surg Am* 1991;73:982-9. doi: 10.2106/00004623-199173070-00004, PMID 1874784
  22. Kluger R, Bock P, Mittlböck M, Krampla W, Engel A. Long-term survivorship of rotator cuff repairs using ultrasound and magnetic resonance imaging analysis. *Am J Sports Med* 2011;39:2071-81. doi: 10.1177/0363546511406395, PMID 21610262
  23. Demirhan M, Atalar AC, Kocabey Y, Akalin Y. Arthroscopic-assisted mini-open rotator cuff repair. *Acta Orthop Traumatol Turc* 2002;36:1-6.
  24. van Deurzen D, Scholtes V, Willems WJ, Geerdink HH, van der Woude HJ, van der Hulst V, *et al*. Long-term results of arthroscopic and mini-open repair of small-to medium-size full-thickness rotator cuff tears. *Shoulder Elbow* 2019;11(1 Suppl):68-76. doi: 10.1177/1758573218773529, PMID 31019565
  25. Bell S, Lim YJ, Coghlan J. Long-term longitudinal follow-up of mini-open rotator cuff repair. *J Bone Joint Surg Am* 2013;95:151-7. doi: 10.2106/JBJS.K.00499, PMID 23324963