

EVALUATION OF INNER SEGMENT-OUTER SEGMENT JUNCTION INTEGRITY BY OCT IN PATIENTS OF BLUNT OCULAR TRAUMA AND THEIR CORRELATION WITH VISUAL ACUITY

KHYATI NIRAPURE¹, BIMALESH OJHA², VIKAS JAMRA³, ANKIT SOLANKI^{4*}

¹Department of Ophthalmology, Shyam Shah Medical College, Rewa, Madhya Pradesh, India. ²Department of Ophthalmology, Gandhi Medical College, Bhopal, Madhya Pradesh, India. ³Department of Ophthalmology, MGM Medical College, Indore, Madhya Pradesh, India. ⁴Department of Medicine, Bundelkhand Medical College, Sagar, Madhya Pradesh, India.

*Corresponding author: Dr. Ankit Solanki; Email: ankit7solanki@gmail.com

Received: 21 July 2023, Revised and Accepted: 28 August 2023

ABSTRACT

Objective: The aim of this study was to find the prevalence of inner segment-outer segment (IS-OS) junction changes in the foveal region in patients of blunt ocular trauma.

Methods: A cross-sectional observational study was done in department of ophthalmology in tertiary health care center, Rewa (M.P.), India from January 2020 to September 2021 with 80 patients of blunt ocular trauma. HD-5line raster with enhanced depth imaging was done for each eye using Cirrus HD optical coherence tomography machine and results were obtained.

Results: The mean age of the patients undergoing blunt ocular trauma was 36.59±16.26 years. Out of 80 patients 61 were male and 19 were female. Twenty-nine patients had posterior segment involvement out of which 25 had IS-OS junction disruption.

Conclusion: There is high prevalence of IS-OS junction changes in the foveal region in patients of blunt ocular trauma with posterior segment involvement and has a significant correlation with visual acuity.

Keywords: Inner segment-outer segment junction, Optical coherence tomography, Visual acuity, Blunt ocular trauma.

© 2023 The Authors. Published by Innovare Academic Sciences Pvt Ltd. This is an open access article under the CC BY license (<http://creativecommons.org/licenses/by/4.0/>) DOI: <http://dx.doi.org/10.22159/ajpcr.2023v16i10.49153>. Journal homepage: <https://innovareacademics.in/journals/index.php/ajpcr>

INTRODUCTION

Closed globe blunt ocular trauma is an important cause of mono ocular visual impairment. It can involve different ocular structures in a very diverse way in terms of severity. Anterior segment manifestations may be in the form of sub-conjunctival hemorrhage, corneal abrasion, traumatic hyphema, uveitis, lens subluxation/dislocation, and traumatic cataract. The posterior segment involvement may manifest as vitreous hemorrhage, choroidal rupture and hemorrhage, retinal hemorrhage, tears, detachment, or commotion retinae. Although the maximum brunt of the injury is usually borne by the anterior segment, the impact of posterior segment trauma is usually long standing and may have permanent consequences.

Optical coherence tomography (OCT) is a non-invasive, readily performed imaging modality that provides reliable, high-resolution imaging of retinal anatomy. With recent advances in technology, the new OCT machines can delineate certain lines which are integral to vision. These include from bottom upward, the retinal pigment epithelium (RPE), the cone outer segment tip (COST) line, the inner segment-outer segment (IS-OS) junction, and the external limiting membrane (ELM). These lines correspond to the photo receptor cells and so a breach in them in the foveal area is usually associated with a permanent damage to visual potential. Various studies have recently demonstrated the visual and prognostic significance of these lines in numerous diseases [1-6]. However, not many studies have been done to identify the prognostic role of these lines in blunt ocular trauma [7-9].

Aims and objectives

The objectives of this study were as follows:

1. To find the prevalence of IS-OS junction changes in the foveal region in blunt ocular trauma patients

2. To analyze the correlation of visual acuity with changes in the IS-OS junction in blunt ocular trauma patients.

METHODS

This study was carried out in the Department of Ophthalmology, Shyam Shah Medical College and associated Gandhi Memorial Hospital, Rewa (M.P.), India, from January 2020 to September 2021.

Study design

This was hospital-based cross-sectional study.

Study subjects

Inclusion criteria

- All patients of blunt trauma (Closed Globe Injury) were included in the study.

Exclusion criteria

The following criteria were excluded from the study:

- Patients <5 years
- Significant media opacity (Corneal/lenticular/vitreous) which obscured fundus visualization
- History of previous ocular surgery
- Pre-existing corneal/uveal/retinal diseases
- Associated systemic disease.

Data collection method

Detailed informed consent was taken and those patients fulfilling the study criteria were enrolled. A comprehensive ophthalmic examination was done in all patients which included best-corrected visual acuity, slit-lamp biomicroscopy, IOP measurement, gonioscopy (where possible), and dilated fundus examination with

+90D lens and indirect ophthalmoscope. Macular scan (HD 5-Line raster with enhanced depth imaging) was done for each eye using Cirrus HD OCT machine and patients were assigned into three groups, depending on the integrity of IS-OS junction according to the following parameters:

- Group 1: Integrity maintained – no line disruption
- Group 2: Integrity less maintained – disruption <100 micron
- Group 3: Integrity breached – disruption >100 micron

The variation of visual acuity with integrity of IS-OS junction was assessed and the results were analyzed to find the prognostic value of these changes in cases of blunt trauma.

Statistical analysis

The collected data were fed in computer in Microsoft Excel and the analysis was performed using the Statistical Package for the Social Sciences Version 20 for statistics. Chi-square and Fishers exact test was used to test the difference in the proportions.

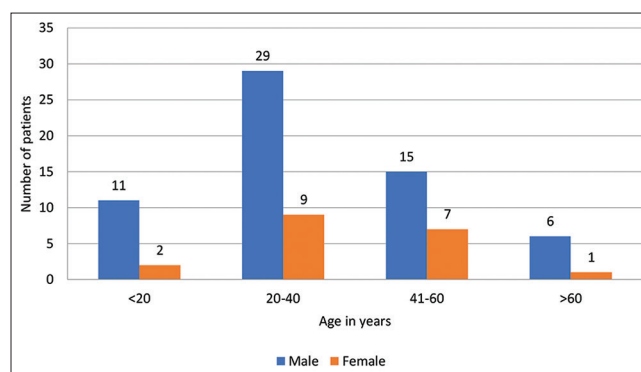
RESULTS

Majority of the study participants belonged to the age group of 20–40 years. The age of the patients ranged between 6 and 75 years with a mean age of 36.59±16.26 years. Out of 80 patients 61 were male and 19 were female. A male predominance was noted in our study with a male: female ratio of 3.2:1. Table 1 and Graphs 1 and 2 show the detailed demographic profile of the study participants.

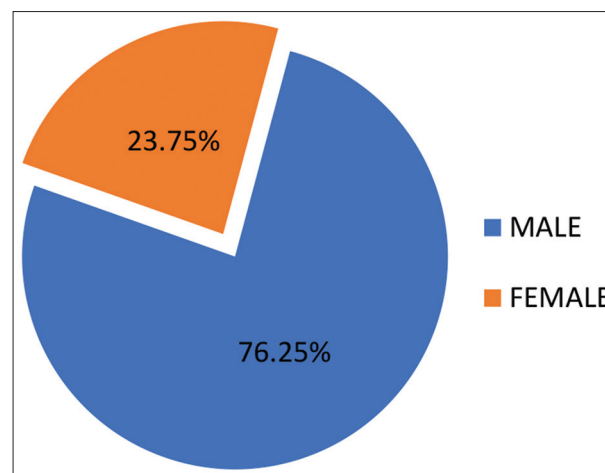
For the study purpose, all subjects underwent OCT evaluation to assess the status of the IS-OS junction following blunt ocular trauma. Depending on the appearance of the IS-OS junction on HD-Raster macular scan, the patients were grouped into three groups, with Group 1 patients having no breach in continuity of the line, Group 2 subjects having a breach in continuity of the line of <100 microns, and Group 3 cases having a disruption of line measuring greater than 100 microns. Table 2 shows the number and Graph 3 shows the percentage of study subjects in each group. Since only 29 patients in this study had posterior segment involvement, the integrity of the IS-OS junction was found to be well

preserved in most (n=55; 68.75%) patients. IS-OS junction disruption was observed in 25 patients (31.25%).

Evaluating the variation of visual acuity with this line, we found that the visual acuity corresponded well with the status of disruption of IS-OS junction. The mean logMAR visual acuity was 0.26±0.30 in eyes showing no breach in IS-OS junction continuity in contrast to 1.02±0.15 in patients having a breach and this difference was statistically significant (p=0.0004). More specifically, it was seen that visual acuity was also related to the size of the defect of IS-OS junction. For eyes having an IS-OS junction defect of less than 100 micron, the mean logMAR visual acuity was 0.97±0.16 while for those with a defect more than 100 microns, it was 1.06±0.12. Comparing these values with those for uninterrupted line for IS-OS junction, the difference was found to



Graph 1: Demographic data of study subjects



Graph 2: Gender distribution of study subjects

Table 1: Demographic data of study subjects

Age group (in years)	Male	Female	Total
<20	11	2	13
20–40	29	9	38
41–60	15	7	22
>60	6	1	7
Total	61	19	80

Table 2: Status of integrity of IS-OS junction

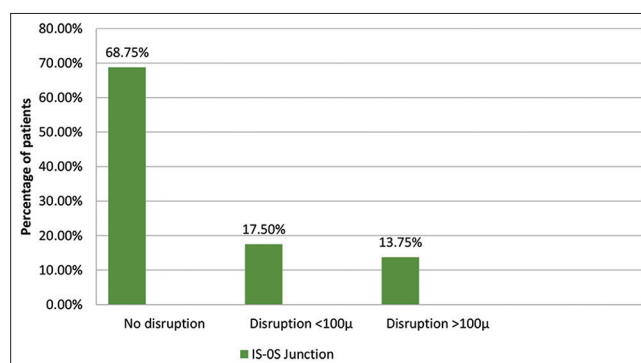
Number of Patients/group	Group 1 No line disruption	Group 2 Disruption <100 micron	Group 3 Disruption >100 micron
Number of patients	55	14	11

IS-OS: Inner segment-outer segment

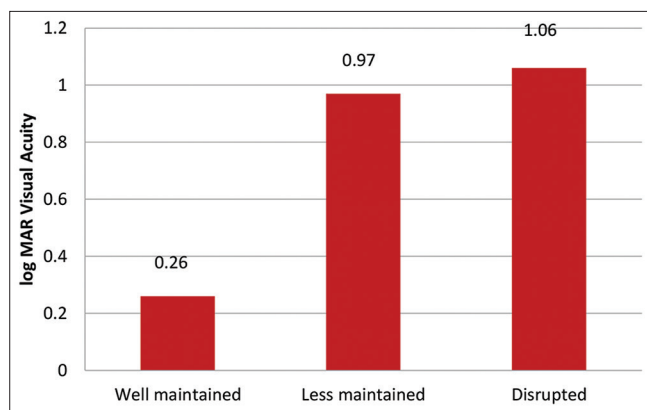
Table 3: Variation of log MAR visual acuity with integrity of IS-OS junction

LogMAR Visual acuity/group	Group 1 No line disruption	Group 2 Disruption <100 micron	Group 3 Disruption >100 micron
Mean logMAR visual acuity	0.26±0.30	0.97±0.16	1.06±0.12
p-value		0.0223	0.0034

IS-OS: Inner segment-outer segment



Graph 3: Status of integrity of IS-OS junction. IS-OS: Inner segment-outer segment



Graph 4: Variation of visual acuity with integrity of IS-OS junction. IS-OS: Inner segment-outer segment

be statistically significant ($p < 0.05$). This data is depicted in Table 3 and graphically represented in Graph 4.

DISCUSSION

Retinal anatomy and functions are now well studied with new equipments due to advanced technology. OCT is now an integral tool of ophthalmology to delineate retinal pathologies. HD OCT machines are newer machine and are helpful to get explicit resolution of various layers of retina. The four hyper-reflective horizontal lines seen on macular OCT with breach in lines show an abnormal macular function. These retinal lines include from bottom upward, the RPE, the COST line, the IS-OS junction, and the ELM. In various studies, these lines have been shown to have visual and prognostic significance in numerous diseases [10-15]. These lines are believed to correspond to the ultra-structure of the photoreceptor cells; hence, a break in the foveal area is usually associated with permanent damage to the visual functions of this area. However, the exact microscopic localization of these lines has been a matter of much debate, the recently it has been shown in studies that the IS-OS junction actually represents the ellipsoid zone of the inner segment [16]. Whatever the exact anatomical location of these lines, their break has been consistently reported to be associated with poor vision in many diseases. Post vitreoretinal surgery integrity of retina has also been shown to have significant correlation with visual acuity postoperatively [17]. After blunt trauma, some studies have been done to find out the role of these lines among those having commotio retinae [18-24]. In general, these patients reveal an increase in reflectivity/intensity of the IS-OS junction; however, some studies have also reported loss or attenuation of these lines [18,22,23]. Appearance of these lines have sometimes been reported to return to normal [19,22,24]. Visual recovery is seen to be correlated to the region of the initial disruption in these patients [18,23]. These latter results are consistent with the original findings of Sipperley *et al.*, who hypothesized that the resultant visual loss in commotio retinae may be determined by the amount of photoreceptor damage occurring during the initial trauma [25]. The study was conducted on patients with ocular trauma who had no associated general diseases and previous eye diseases. OCT was done once when the media was clear and visual acuity and OCT (with signal strength ≥ 6) were recordable. Visual acuity correlated with the amount of breach in the IS-OS junction noted on the OCT in the foveal region. Thus, it could be concluded that these lines can be used as a visual prognostic indicator in blunt trauma patients to explain about final possible visual outcome after the anterior segment injuries have settled. The factors which were important were: (i) presence of disruption of the line of vision, (ii) length of disruption, and (iii) location of the disruption (whether subfoveal or juxtafoveal). The limitations of the study were as follows: (i) Sample size < 100 , (ii) subjects were chosen for the study in a non-randomized manner, and (iii) subjects were not followed up. Hence, a larger trial for a longer duration on this topic is recommended to further confirm these findings.

CONCLUSION

The conclusions drawn from this study are as follows:

- Maximum number of participants were in the age group of 20–40 years (47.5%) and a male preponderance was seen with a male:female ratio of 3.2:1. This is attributable to the fact that young, adult males are more involved in outdoor work and activities as compared to females.
- The integrity of IS-OS junction was preserved in most cases (68.75%) as the posterior segment was involved in a smaller number of patients (36.25%).
- The mean logMAR visual acuity was better in eyes showing no breach in IS-OS junction (0.26) in contrast to decreased visual acuity in patients having a breach (0.97 in disruption $< 100 \mu$ and 1.06 in disruption $> 100 \mu$) and the difference was statistically significant.

Our study found that the status of IS-OS junction was an important factor as regards the visual acuity in cases of closed globe blunt ocular injury since this line corresponds to the photo receptor cells and a breach in it in the foveal area is usually associated with a permanent damage to visual potential. Hence, this study concludes that the integrity of IS-OS junction after closed globe blunt ocular trauma can be a significant predictor of visual acuity and, hence, can be used as a prognostic indicator in cases of closed globe blunt ocular trauma.

ETHICAL APPROVAL

The study was approved by the Institutional Ethics Committee of Armed Force Medical College, Pune, Maharashtra, India.

ACKNOWLEDGMENT

We are thankful to the whole Ophthalmology Department, SS Medical College (SSMC) and our admitted patients of Gandhi Memorial Hospital, Rewa without their support that this study would not have been possible.

AUTHORS' CONTRIBUTIONS

Khyati Nirapure - Contributed regarding conception or design of the study, developing the consent form, data collection, interpreted the results and manuscript editing; Bimalesh Ojha - statistical analysis and interpretation, Vikas Jamra- Coordination and Manuscript revision; Ankit Solanki- Review Manuscript.

CONFLICTS OF INTEREST

None declared.

FUNDING

Self.

REFERENCES

1. Huang D, Swanson EA, Lin CP, Schuman JS, Stinson WG, Chang W, *et al.* Optical coherence tomography. *Science* 1991;254:1178-81.
2. Diabetic Retinopathy Clinical Research Network Writing Committee, Bressler SB, Edwards AR, Chalam KV, Bressler NM, Glassman AR, *et al.* Reproducibility of spectral-domain optical coherence tomography retinal thickness measurements and conversion to equivalent time-domain metrics in diabetic macular edema. *JAMA Ophthalmol* 2014;132:1113-22.
3. Diabetic Retinopathy Clinical Research Network, Browning DJ, Glassman AR, Aiello LP, Beck RW, Brown DM, *et al.* Relationship between optical coherence tomography-measured central retinal thickness and visual acuity in diabetic macular edema. *Ophthalmology* 2007;114:525-36.
4. Wolf-Schnurrbusch UE, Ceklic L, Brinkmann CK, Iliev ME, Frey M, Rothenbuehler SP, *et al.* Macular thickness measurements in healthy eyes using six different optical coherence tomography instruments. *Invest Ophthalmol Vis Sci* 2009;50:3432-7.
5. Girkin CA, McGwin G Jr., Sinai MJ, Sekhar GC, Fingeret M, Wollstein G, *et al.* Variation in optic nerve and macular structure with

- age and race with spectral-domain optical coherence tomography. *Ophthalmology* 2011;118:2403-8.
6. Katz J, Tielsch JM. Lifetime prevalence of ocular injuries from the baltimore eye survey. *Arch Ophthalmol* 1993;111:1564-8.
 7. Schein OD, Hibberd P, Shingleton BJ, Kunzweiler T, Frambach DA, Seddon JM, *et al.* The spectrum and burden of ocular injury. *Ophthalmology* 1988;95:300-5.
 8. Vats S, Murthy GV, Chandra M, Gupta SK, Vashist P, Gogoi M. Epidemiological study of ocular trauma in an urban slum population in Delhi, India. *Indian J Ophthalmol* 2008;56:313-6.
 9. Dandona L, Dandona R, Srinivas M, John RK, McCarty CA, Rao GN. Ocular trauma in an urban population in Southern India: The Andhra Pradesh eye disease study. *Clin Exp Ophthalmol* 2000;28:350-6.
 10. Shen Y, Liu K, Xu X. Correlation between visual function and photoreceptor integrity in diabetic macular edema: Spectral-domain optical coherence tomography. *Curr Eye Res* 2016;3:391-9.
 11. Kwon YH, Lee DK, Kim HE, Kwon OW. Predictive findings of visual outcome in spectral domain optical coherence tomography after ranibizumab treatment in age-related macular degeneration. *Korean J Ophthalmol* 2014;28:386-92.
 12. Tortorella P, D'Ambrosio E, Iannetti L, De Marco F, La Cava M. Correlation between visual acuity, inner segment/outer segment junction, and cone outer segment tips line integrity in uveitic macular edema. *Biomed Res Int* 2015;2015:853728.
 13. Meunier I, Arndt C, Zanlonghi X, Defoort-Dhellems S, Drumare I, Mauguet-Faysse M, *et al.* Spectral-domain optical coherence tomography in hereditary retinal dystrophies. In: Liu G, editor. *Selected Topics in Optical Coherence Tomography*. England: Intech Open; 2012.
 14. Inoue M. Correlation between the morphology of the IS/OS junction and functional outcomes in patients with idiopathic epiretinal membrane. *Nihon Ganka Gakkai Zasshi* 2012;116:1029-36.
 15. Shao Q, Xia H, Heussen FM, Ouyang Y, Sun X, Fan Y. Postoperative anatomical and functional outcomes of different stages of high myopia macular hole. *BMC Ophthalmol* 2015;15:93.
 16. Spaide RF, Curcio CA. Anatomical correlates to the bands seen in the outer retina by optical coherence tomography: Literature review and model. *Retina* 2011;31:1609-19.
 17. Matsumiya W, Kusuhara S, Shimoyama T, Honda S, Tsukahara Y, Negi A. Predictive value of preoperative optical coherence tomography for visual outcome following macular hole surgery: Effects of imaging alignment. *Jpn J Ophthalmol* 2013;57:308-15.
 18. Souza-Santos F, Lavinsky D, Moraes NS, Castro AR, Cardillo JA, Farah ME, *et al.* Spectral-domain optical coherence tomography in patients with commotio retinae. *Retina* 2012;32:711-8.
 19. Oh J, Jung JH, Moon SW, Song SJ, Yu HG, Cho HY, *et al.* Commotio retinae with spectral-domain optical coherence tomography. *Retina* 2011;31:2044-9.
 20. Sony P, Venkatesh P, Gadaginamath S, Garg SP. Optical coherence tomography findings in commotio retinae. *Clin Exp Ophthalmol* 2006;34:621-3.
 21. Meyer CH, Rodrigues EB, Mennel S. Acute commotio retinae determined by cross-sectional optical coherence tomography. *Eur J Ophthalmol* 2003;13:816-8.
 22. Park JY, Nam WH, Kim SH, Jang SY, Ohn YH, Park TK. Evaluation of the central macula in commotio retinae not associated with other types of traumatic retinopathy. *Korean J Ophthalmol* 2011;25:262-7.
 23. Ahn SJ, Woo SJ, Kim KE, Jo DH, Ahn J, Park KH, *et al.* Optical coherence tomography morphologic grading of macular commotio retinae and its association with anatomic and visual outcomes. *Am J Ophthalmol* 2013;156:994-1001.e1.
 24. Saleh M, Letsch J, Bourcier T, Munsch C, Speeg-Schatz C, Gaucher D, *et al.* Long-term outcomes of acute traumatic maculopathy. *Retina* 2011;31:2037-43.
 25. Sipperley JO, Quigley HA, Gass DM. Traumatic retinopathy in primates. The explanation of commotio retinae. *Arch Ophthalmol* 1978;96:2267-73.