

## AN OBSERVATIONAL STUDY TO STANDARDIZE THE DERMOSCPIC FINDINGS OF NORMAL SCALP AND HAIRS IN MALE

RANSINGH TANWAR<sup>1</sup>, SAURABH SARDA<sup>2</sup>, DILEEP DANDOTIYA<sup>3</sup>, PRASANJEET DASH<sup>4\*</sup>, RISHI JAIN<sup>1</sup>

<sup>1</sup>Department of Dermatology, Venerology and Leprosy, GMC, Bhopal, Madhya Pradesh, India. <sup>2</sup>Department of Dermatology, Venerology and Leprosy, Dr. Ulhas Patil Medical College, Jalgon, Maharashtra. <sup>3</sup>Department of Dermatology, Venerology and Leprosy, GMC, Ratlam, Madhya Pradesh, India. <sup>4</sup>Department of Community Medicine, CIMS, Chhindwara, Madhya Pradesh, India.

\*Corresponding author: Dr. Prasanjeet Dash; E-mail: prasanjeetdash14@gmail.com

Received: 30 July 2023, Revised and Accepted: 12 September 2013

### ABSTRACT

**Objectives:** To standardize trichoscopic findings of normal hairs and scalp in male.

**Methodology:** This study was conducted over one year period with effect from 24<sup>th</sup> January 2020 to 23<sup>th</sup> January 2021 among 360 male subjects presenting in outpatient Department of Dermatology, Venereology & Leprosy, M.G.M. Medical College & M.Y. Hospital, Indore (M.P.). Examination to rule out any local dermatological disorder of scalp was done. Trichoscopic photographs were taken from frontal, right temporal, occipital and vertex area with the help of HEINE DELTA 20T digital dermatoscope

**Results:** Anisotrichosis shows significant age wise difference in temporal and occipital area. Whereas maximum numbers of subjects with anisotrichosis were present in frontal area followed by vertex scalp. Maximum numbers of subjects with white dots are present in more than 50 years age group in vertex (83.3%). Overall maximum numbers are present in vertex area (68.6%) and rest of the areas has nearly equal numbers (56%).

**Conclusion:** Comparison with standardize findings is necessary before labelling it as pathological finding, also some variables like black dots, yellow dots, red dots, scarring and hair shaft abnormality other than diameter variability are considered as absolute pathological finding and not found in healthy subjects, when present on trichoscopy they signify some hair or scalp abnormality.

**Keywords:** Trichoscopy, Standardize, Dermoscopic findings, Scalp, Anisotrichosis.

© 2023 The Authors. Published by Innovare Academic Sciences Pvt Ltd. This is an open access article under the CC BY license (<http://creativecommons.org/licenses/by/4.0/>) DOI: <http://dx.doi.org/10.22159/ajpcr.2023v16i10.49504>. Journal homepage: <https://innovareacademics.in/journals/index.php/ajpcr>

### INTRODUCTION

Trichoscopy (dermatoscopy of hairs) is a recent innovation in the field of dermatology and alternative to more time consuming and cumbersome procedures such as Pull test, Pluck test, Daily hair count, scalp biopsy, microscopic examination of hair by conventional methods by microscope which needs removal of hairs which is painful and unacceptable to patients, to replace these old modality with newer one to diagnose hair and scalp disorders by dermatoscope is known as trichoscopy [1]. It is easy non-invasive, less time consuming, and well acceptable to patients. It can also help in monitoring the disease activity, response to therapy and helps to know the prognosis and record the follow-up of patients; also, it helps to improve doctor-patient relationships. After many years of invention of dermoscope by Christophorus Kolhaus in 1663 [2], the art of dermatoscopy continuously evolved and it is started to being used for examination of hairs and scalp after its use by Kosaard and Zagarella in 1993 [3] when they after its used for diagnosis cicatricial hair disorders, 10 years later Lacarrubba *et al.* [4] first published dermoscopic features of nonscarring alopecia AA. Later in 2005, the dermoscopy was used for visualization of disease severity in androgenic alopecia and monitoring treatment efficacy [5]. In the subsequent year [6], videodermoscopic findings of various hair and scalp disorders were published. Also in 2006, "trichoscopy" became the known term for examination of scalp hair, eyebrows hairs, and eyelashes [7]. In 2007, Rakowska *et al.* showed the benefits of trichoscopy in genetic hair shaft disorders over conventional trichological examinations over pulled hair [8]. In 2007, Tosti [9] published the first atlas of dermatoscopy of hair and scalp and after that, many studies were conducted for hair and scalp disorder with defining the various sign and dermoscopic parameters of hair and scalp like anisotrichosis, vellus like hair, black dots yellow dots vascular and pigmentary pattern of scalp and hair disorders. After years of use of this modality for examination of hair and scalp disorders, there is no relevant data regarding trichoscopic variables of hairs and scalp in normal population were found. There is

much data available on trichoscopic findings of hair disorders but there is very few study available to standardize these parameters in normal scalp and hairs. Without availability of baseline parameter of normal scalp and hair, we would not be able to conclude the findings of trichoscopy as a reliable measurement of hair and scalp disorders. Hence, we are conducting our study to standardize the data on various trichoscopic parameters of the hair shaft, perifollicular, and inter follicular area of scalp at various age groups starting from 1 year to 70 years of age. Hence, to fill this data gap literature, we have conducted this observation study.

### Objectives

The objectives of the study are to standardize trichoscopic findings of normal hairs and scalp in male.

### METHODS

This cross-sectional (observational) study was conducted over 1-year period with effect from 24<sup>th</sup> January 2020 to 23<sup>th</sup> January 2021 on male subjects presenting in outpatient Department of Dermatology, Venereology, and Leprosy, M.G.M. Medical College and M.Y. Hospital, Indore (M.P.).

### Inclusion criteria

1. Male patients of 1-70-year age group who came to outpatient department.
2. Without complaints of hair related problem.

### Exclusion criteria

- 1) Subject with chronic systemic illness giving rise to telogen phase
- 2) Subject with anemia and thyroid disorder or having any congenital or acquired hair disorder
- 3) Age >70 years
- 4) Non consenting participants
- 5) Subject who have used hair dye within the past 15 days.

### Study process

This study was conducted in the Department of Dermatology, Venereology, and Leprosy in M.Y. Hospital, Indore, after approval from departmental and institutional review board and ethical committee. We recruited 360 male subjects presenting to Dermatology, Venereology, and Leprosy in M.Y. Hospital, Indore, OPD without the complaints of hair loss/thinning, and fulfilling the inclusion criteria for our study. An informed written consent was then obtained after explaining the procedure in detail. All subjects recruited were undergone through detailed history and clinical examination. Examination to rule out any local dermatological disorder of scalp was done. Trichoscopic photographs were taken from frontal, right temporal, occipital, and vertex area with the help of HEINE DELTA 20T digital dermatoscope (Figs. 1 and 2). Contact plate of dermatoscope was sterilized using 2% glutaraldehyde or methylated spirit every time before and after dermoscopy. Photographs were stored in memory card of camera attached with dermatoscope and then stored in personal computer.

### Statistical analysis

The data were entered in MS EXCEL spreadsheet and analysis was done using the Statistical Package for the Social Sciences (SPSS) version 28.0. Categorical variables were presented in number (frequency) and percentage (%) and continuous variables were presented as mean±SD. Nominal variables were compared using repeated measures of crosstab analysis using Chi-square test between various age groups. Scale variables were analyzed using Spearman's test as the normality of distribution was absent. Mean and SD were calculated using ANOVA test and P value was calculated using Kruskal-Wallis Test. A  $p < 0.05$  was considered as statistically significant.

### RESULTS

Table 1 shows that anisotrichosis shows significant age-wise difference in temporal and occipital area. Whereas maximum numbers of subjects with anisotrichosis were present in frontal area followed by vertex scalp, the highest numbers of cases are seen in the age group 1-10 years, then decreasing trends were observed in 11-30 years, again it shows increase in number after 31 years of age groups onward. The P-value for occipital and temporal area is significant  $< 0.05$ .

Chart 1 shows that the canities is seen in  $> 18\%$  of subjects in the 11-20-year age group while  $> 70\%$  of cases shows canities after 30 years of age.

Above Chart 2 shows that scaling has significant area-wise difference with vertex and frontal area having more incidence than occipital and temporal area.

Table 2 shows that the number of hair follicular units per dermoscopic field of  $20 \text{ mm}^2$  ( $4 \text{ mm} \times 5 \text{ mm}$ ) shows negative correlation with increasing age and has significant  $p < 0.05$  in frontal, occipital, and vertex area while not significant in temporal area. The number of single hair follicular units per dermoscopic field of  $20 \text{ mm}^2$  ( $4 \text{ mm} \times 5 \text{ mm}$ ) shows positive correlation with increasing age and has significant  $p < 0.05$



Fig. 1: Heine Delta 20T digital dermatoscope with DSLR camera (NIKON-D7500)



Fig. 2: Dermoscopy procedure

Table 1: Age group and area-wise distribution of anisotrichosis

Age group	Frequency (%)							
	Frontal		Temporal		Occipital		Vertex	
	Present	Absent	Present	Absent	Present	Absent	Present	Absent
1-10	34 (56.7)	26 (43.3)	35 (58.3)	25 (41.7)	35 (58.3)	25 (41.7)	34 (56.7)	26 (43.3)
11-20	26 (43.3)	34 (56.7)	22 (36.7)	38 (63.3)	35 (58.3)	25 (41.7)	26 (43.3)	34 (56.7)
21-30	27 (45.0)	33 (55.0)	15 (25.0)	45 (75.0)	18 (30.0)	42 (70.0)	21 (35.0)	39 (65.0)
31-40	34 (56.7)	26 (43.3)	25 (41.7)	35 (58.3)	17 (28.3)	43 (71.7)	25 (41.7)	35 (58.3)
41-50	34 (56.7)	26 (43.3)	29 (48.3)	31 (51.7)	29 (48.3)	31 (51.7)	28 (46.7)	32 (53.3)
>50	34 (56.7)	26 (43.3)	16 (26.7)	44 (73.3)	29 (48.3)	31 (51.7)	34 (56.7)	26 (43.3)
Total	189 (52.5)	171 (47.5)	142 (39.4)	218 (60.6)	163 (45.3)	197 (54.7)	168 (46.7)	192 (53.3)
p	0.421		<0.001		<0.001		0.110	

Table 2: Age and area-wise correlation of number of HFU, number of single HFU, and number of vellus hair

Age (in years)	Variable	Coefficient	Frontal	Temporal	Occipital	Vertex
	Number of HFU	r	-0.272	-0.080	-0.147	-0.105
		p	<0.001	0.131	0.005	0.046
	Number of single HFU	r	0.320	0.124	0.167	0.260
		p	<0.001	0.018	0.001	<0.001
	Number of vellus hair	r	-0.047	-0.149	-0.235	-0.117
		p	0.374	0.005	<0.001	0.026

r and P calculated using Spearman's test

in all four areas. The number of vellus hairs per dermoscopic field of 20 mm<sup>2</sup> (4 mm × 5 mm) shows negative correlation with increasing age having significant p<0.05, in temporal, occipital, and vertex area while not significant in frontal area.

In Table 3, significant age-wise difference was seen in mean number of total hair follicular units (19.5±2.1), single hair containing follicular units (0.63±1.0), and vellus like hairs (2.0±1.7) in occipital area as shown in table considering significant p<0.05. With maximum numbers of mean hair follicular units were present in the 1-10-year age group (20.2±1.9) while least in the >50-year age group (18.7±2.2). Maximum numbers of mean single hair follicular units were present in the 41-50-year age group (0.87±1.6) while least in the 11-20-year age group (0.4±0.9) and maximum numbers of mean vellus hair were present in the 1-10-year age group (2.9±1.7) while least in >50-year age group (1.7±1.7).

Significant age-wise difference was seen in mean number of total hair follicular units (18.4±2.2) and vellus like hairs (1.9±1.6) while single hair containing follicular units (0.94±1.2) show insignificant p value in temporal

**Table 3: Age wise distribution of mean±SD of HFU, No. of single HFU and No. of Vellus hair in occipital scalp**

Age group	No. of HFU	No. of single HFU	No. of Vellus Hair
	Mean±SD	Mean±SD	Mean±SD
1-10	20.183±1.9441	0.567±1.0635	2.917±1.6904
11-20	19.683±2.2131	0.383±0.9037	2.300±1.5104
21-30	19.267±2.2986	0.500±0.9655	1.750±1.5028
31-40	19.317±2.0042	0.617±0.9931	1.717±1.6477
41-50	19.750±1.9883	0.867±1.1567	1.800±1.7640
>50	18.733±2.2160	0.833±1.0442	1.650±1.6857
Total	19.489±2.1490	0.628±1.0317	2.022±1.6871
p-value	0.005	0.016	<0.001

SD: Standard deviation

**Table 4: Age-wise distribution of mean±SD of HFU, number of single HFU, and number of vellus hair in temporal scalp**

Age group	Mean±SD		
	Number of HFU	Number of single HFU	Number of vellus hair
1-10	19.167±2.5189	0.783±1.1213	2.450±1.7700
11-20	18.033±1.8953	0.767±1.1404	1.917±1.5436
21-30	18.150±2.6026	0.867±1.0491	1.850±1.4938
31-40	18.267±2.0158	0.950±1.2133	2.167±1.5089
41-50	18.850±2.1299	1.067±1.2604	1.683±1.5676
>50	17.850±1.9295	1.233±1.4066	1.517±1.7611
Total	18.386±2.2338	0.944±1.2069	1.931±1.6295
p	0.009	0.352	0.023

SD: Standard deviation

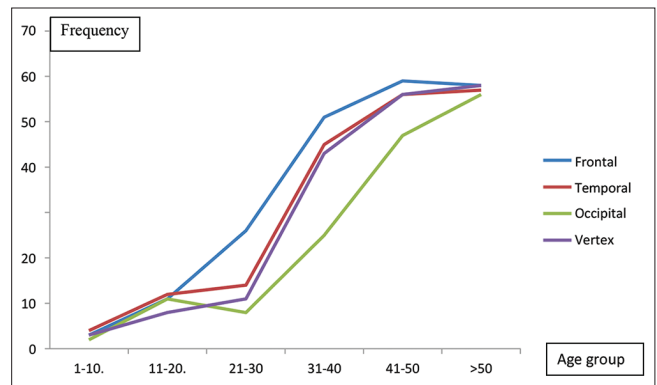
**Table 5: Age-wise distribution of mean±SD of HFU, number of single HFU, and number of vellus hair in frontal scalp**

Age group	Mean±SD		
	Number of HFU	Number of single HFU	Number of vellus hair
1-10	21.167±2.0762	0.650±1.2464	3.067±1.6961
11-20	20.450±2.1583	0.767±1.1103	2.583±1.3441
21-30	20.250±1.9798	1.033±1.1042	2.500±1.3961
31-40	19.733±2.1302	1.333±1.2975	2.183±1.5237
41-50	20.217±2.1080	1.683±1.6924	2.417±1.8067
>50	19.333±1.8746	2.017±1.6823	2.767±1.9776
Total	20.192±2.1215	1.247±1.4521	2.586±1.6516
p	<0.001	<0.001	0.038

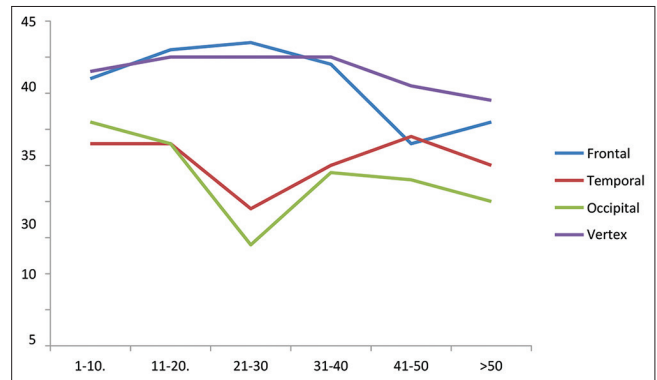
SD: Standard deviation

area as shown in Table 4 considering significant p<0.05. With maximum numbers of mean hair follicular units were present in the 1-10-year age group (19.2±2.5) while least in the >50-year age group (17.9±1.9). Maximum numbers of mean single hair follicular units were present in >50-year age group (1.2±1.4) while least in the 11-20-year age group (0.767±1.1) and maximum numbers of mean vellus hair were present in the 1-10-year age group (2.5±1.8) while least in the >50-year age group (1.5±1.8).

Significant age-wise difference was seen in mean number of total hair follicular units (20.1±2.1), single hair containing follicular units (1.2±1.4), and vellus like hairs (2.5±1.6) in frontal area as shown in



**Chart 1: Age group and area-wise trends of canities**



**Chart 2: Age group and area-wise trends of scaling**

**Table 6: Age-wise distribution of mean±SD of HFU, number of single HFU, and number of vellus hair in vertex scalp**

Age group	Mean±SD		
	Number of HFU	Number of single HFU	Number of vellus hair
1-10	21.017±2.0042	0.517±0.9828	2.833±1.6991
11-20	20.150±2.3203	0.733±1.2332	2.067±1.3761
21-30	20.667±1.9543	0.917±1.1831	2.183±1.4900
31-40	20.333±2.0225	1.250±1.2299	2.133±1.5673
41-50	20.633±1.9912	1.567±1.4540	1.783±1.8694
>50	19.850±2.3057	1.433±1.4305	2.333±1.7724
Total	20.442±2.1248	1.069±1.3091	2.222±1.6574
p	0.063	<0.001	0.013

SD: Standard deviation. No significant age-wise difference was seen in mean number of total hair follicular units (20.4±2.1) while vellus like hairs (2.2±1.7) and single hair containing follicular units (1.1±1.3) show significant p value in vertex area as shown in table considering significant p<0.05. With maximum numbers of mean hair follicular units were present in 1-10-year age group (21.0±2.0) while least in >50-year age group (19.9±2.3). Maximum numbers of mean single hair follicular units were present in 41-50-year age group (1.6±1.5) while least in 1-10-year age group (0.5±1.0) and maximum numbers of mean vellus hair were present in 1-10-year age group (2.9±1.7) while least in 41-50-year age group (1.8±1.9).

Table 5 considering significant  $p < 0.05$ . With maximum numbers of mean hair follicular units were present in the 1–10-year age group ( $21.1 \pm 2.0$ ) while least in the >50-year age group ( $19.3 \pm 1.8$ ). Maximum numbers of meansingle hair follicular units were present in the >50-year age group ( $2.0 \pm 1.6$ ) while least in the 1–10-year age group ( $0.6 \pm 1.2$ ) and maximum numbers of mean vellus hair were present in 1–10-year age group ( $3.0 \pm 1.7$ ) while least in 31–40-year age group ( $2.2 \pm 1.5$ ).

## DISCUSSION

The present study was an attempt to evaluate and standardize different parameters of hair and scalp through trichoscopic examination in the normal male population in various age groups. We recruited 360 healthy male subjects with age ranging from 1 to 70 years by dividing them equally into 6 groups. Today, trichoscopy has significantly reduced the need for scalp biopsy and other test for diagnosis and analysis of hair and scalp disorders. Trichoscopy is a term used for dermoscopic examination of hair and scalp, and it is easy, handy, non-invasive, and more accurate OPD assessment tool for diagnosis of hair and scalp disorder. It can be considered as a boon for dermatologists to monitor therapeutic effects. Trichoscopic examination of the scalp and hair is based on the findings of follicular patterns, interfollicular patterns, hair shaft characteristics, and vascular patterns.

**Anisotrichosis:** In present study, anisotrichosis is significantly seen in temporal and occipital area, while maximum hair shaft diameter variability is present in frontal area followed by vertex in 189 (52.5%) and 168 (46.7%) subjects, respectively. The highest numbers of frequency are seen in age group 1–10 years, 34 (56.7%) out of 60 subjects, this may be explained by more number of vellus like hairs which are seen in age group <10 years, while in age 30–50 years, there is increased chances of age-related androgenetic alopecia which leads to anisotrichosis. In various studies conducted at different places, hair diameter diversity is seen in nearly 100% cases of androgenetic alopecia and is considered as an important diagnostic parameter for pattern hair loss [10-12]. Hair shaft diameter heterogeneity is characterized by the simultaneous presence of hairs of different thicknesses: Vellus, thin intermediate, and thick. Anisotrichosis involving >20% of the hair of the androgen-dependent area of the scalp is considered a major diagnostic criteria for AGA. This finding is very useful for diagnosis of early stage of AGA.20.

**Number of HFU per dermoscopic field:** In present study, 16–22 hair follicular units per dermoscopic field ( $0.2 \text{ cm}^2$ ) (or 80–110/cm<sup>2</sup>) were seen, which are slightly higher than 65–85 follicular units per square centimeter in the occipital scalp reported by Jimenez *et al.* [13]. This difference may be attributed to the age dependent, ethnic, environmental, and demographic variability.

**Interfollicular pigmentation:** It is present in all age groups. As intervening area near by the hair follicles and eccrine glands opening have dark pigmentation also interfollicular pigmentation is increased with age, in dark skin phenotypes in sun exposed area and mainly frontal area. As the age advances number of hair follicles decreases leading to increasing sun exposure as shown in present study. As present study shows that it is present in 28% subjects in age group of 1–10 years which increases 80% after 50 years of age.

**Scaling:** In present study, all types of scaling were seen in 60% subjects in frontal scalp, 42.8% subjects in temporal scalp, 38.9% occipital scalp, 63.3% vertex in healthy subjects, while perifollicular scaling was described in (46%) patients of seborrheic dermatitis with white color dominating over yellow/oily scaling, perifollicular hyperkeratosis was described in 63.8% patients of LPP [14]. 87 scaling is also seen in tinea capitis, scalp psoriasis, and DLE. Thus, characterization of scale with its specific type is also important for the diagnosis of inflammatory scalp disorders as various types of scales are also seen in healthy population. Scaling in the present study is mainly seen in frontal and vertex area more than temporal and occipital area and this variability may be attributed to action of androgen on sebaceous secretion which is more in vertex and frontal scalp.

## CONCLUSION

Most of trichoscopic variable in our study show significant age and area-wise differences and present in both pathological and physiological conditions. Thus, comparison with standardize findings is necessary before labeling it as pathological finding, also some variables such as black dots, yellow dots, red dots, scarring, and hair shaft abnormality other than diameter variability are considered as absolute pathological finding and not found in healthy subjects, when present on trichoscopy they signify some hair or scalp abnormality.

## ACKNOWLEDGMENT

We are thankful to the whole Dermatology Department, MGM Medical College and our admitted patients of MY Hospital, Indore, Madhya Pradesh, without their support this study would not have been possible.

## AUTHOR'S CONTRIBUTION

Ransingh Tanwar: Contributed regarding manuscript preparation from own thesis; Saurabh Sarda: manuscript preparation; Dileep Dandotiya: Statistical analysis and interpretation; Prasanjeet Dash: Manuscript preparation; Rishi Jain: Manuscript preparation.

## CONFLICT OF INTEREST

None declared.

## FUNDING

None.

## REFERENCES

- Rakowska A, Slowinska M, Kowalska-Oledzka E, Rudnicka L. Trichoscopy in genetic hair shaft abnormalities. *J Dermatol Case Rep* 2008;2:14-20. doi: 10.3315/jdcr.2008.1009, PMID 21886705
- Faggioli P, Tamburello A, Sciascera A, Gilardi AG, Mazzone A. Nailfold videocapillaroscopy in internal medicine. *Ital J Med* 2015;9:234-42. doi: 10.4081/ijtj.2015.548
- Kossard S, Zagarella S. Spotted cicatricial alopecia in dark skin. A dermoscopic clue to fibrous tracts. *Australas J Dermatol* 1993;34:49-51. doi: 10.1111/j.1440-0960.1993.tb00856.x, PMID 8311827
- Lacarrubba F, Dall'Oglio F, Rita Nasca M, Micali G. Videodermoscopy enhances diagnostic capability in some forms of hair loss. *Am J Clin Dermatol* 2004;5:205-8. doi: 10.2165/00128071-200405030-00009, PMID 15186200
- Olszewska M, Rudnicka L. Effective treatment of female androgenic alopecia with dutasteride. *J Drugs Dermatol* 2005;4:637-40. PMID 16167423
- Ross EK, Vincenzi C, Tosti A. Videodermoscopy in the evaluation of hair and scalp disorders. *J Am Acad Dermatol* 2006;55:799-806. doi: 10.1016/j.jaad.2006.04.058, PMID 17052485
- Rudnicka L, Olszewska M, Majsterek M, Czuwara J, Slowinska M. Presence and future of dermoscopy. *Expert Rev Dermatol* 2006;1:769-72. doi: 10.1586/17469872.1.6.769
- Rakowska A, Slowinska M, Czuwara J, Olszewska M, Rudnicka L. Dermoscopy as a tool for rapid diagnosis of monilethrix. *J Drugs Dermatol* 2007;6:222-4. PMID 17373184
- Tosti A. Dermoscopy of Hair and Scalp Disorders: With Clinical and Pathological Correlations. Vol. 155. London: CRC Press; 2007.
- Inui S. Trichoscopy for common hair loss diseases: Algorithmic method for diagnosis. *J Dermatol* 2011;38:71-5. doi: 10.1111/j.1346-8138.2010.01119.x, PMID 21175759
- Kibar M, Aktan S, Bilgin M. Scalp dermatoscopic findings in androgenetic alopecia and their relations with disease severity. *Ann Dermatol* 2014;26:478-84. doi: 10.5021/ad.2014.26.4.478, PMID 25143677
- Govindarajulu SM, Srinivas RT, Kuppuswamy SK, Prem P. Trichoscopic patterns of nonscarring alopecia's. *Int J Trichology* 2020;12:99-106. doi: 10.4103/ijtj.ijtj\_1\_19, PMID 33223733
- Jimenez F, Ruifernández JM. Distribution of human hair in follicular units. A mathematical model for estimating the donor size in follicular unit transplantation. *Dermatol Surg* 1999;25:294-8. doi: 10.1046/j.1524-4725.1999.08114.x, PMID 10417585
- Rakowska A. Trichoscopy (hair and scalp videodermoscopy) in the healthy female. Method standardization and norms for measurable parameters. *J Dermatol Case Rep* 2009;3:14-9. doi: 10.3315/jdcr.2008.1021, PMID 21886722