

RARE CASE OF LIPEMIA RETINALIS IN A 24-DAY-OLD INFANT

RAJEETA BASUR*, REENA KUMARI, DINESH KUMAR BHAGAT

Department of Ophthalmology, Mata Gujri Memorial Medical College and LSK Hospital, Kishanganj, Bihar, India.

*Corresponding author: Rajeeta Basur; Email: rajeetabasur@gmail.com

Received: 08 February 2024, Revised and Accepted: 20 March 2024

ABSTRACT

We present a rare case of Lipemia Retinalis in a 24 day old Infant due Hyperlipoproteinemia type 1.

Keywords: Lipemia retinalis, Newborn Infant, Hyperlipoproteinemia

© 2024 The Authors. Published by Innovare Academic Sciences Pvt Ltd. This is an open access article under the CC BY license (<http://creativecommons.org/licenses/by/4.0/>) DOI: <http://dx.doi.org/10.22159/ajpcr.2024v17i4.50952>. Journal homepage: <https://innovareacademics.in/journals/index.php/ajpcr>

INTRODUCTION

Lipemia retinalis is an asymptomatic condition usually not affecting visual acuity. It is most commonly seen in familial hyperchylomicronemia, rarely can also be due to secondary hyperlipidemia following diabetes or acquired hypercholesterolemia [1].

CASE PRESENTATION

A 24-day-old male baby was admitted to the NICU with complaints of excessive crying for 2 days. He was the first born out of a non-consanguineous marriage, delivered by LSCS at term weighing 2.7 kg, with uneventful antenatal period. However, the parents noted abnormal repetitive limb movements since day 1 of birth. He was exclusively breastfed. There is no history of jaundice, bleeding, or rash. During sample collection, his blood was noted to be viscous and light pinkish which turned white when left in the vial for a few minutes.



Image of blood turning Milky on leaving in the vial for a few minutes.

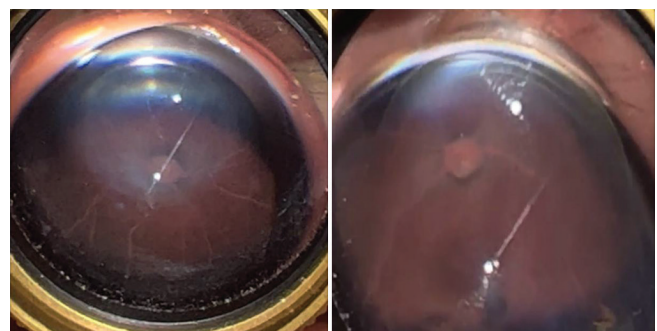
Laboratory investigation revealed negative septic screening, blood culture and normal liver function test, renal function tests, glucose, and serum electrolytes. His Hb was 35.1 g/Dl.

Lipid profile done by calorimetric method showed that serum cholesterol levels were 498.8 mg/Dl (normal <200 mg/Dl), serum triglycerides (TGs) 1180.0 mg/Dl (normal <120 mg/Dl), low-density lipoprotein (LDL) 226 mg/Dl (normal <100 mg/Dl), and very LDL 236 mg/Dl (normal 5-40 mg/Dl).

Lipid profile of both parents was normal.

On eye examination, the anterior segment of both eyes was normal.

Posterior segment examination was done with indirect ophthalmoscope, in which both eyes had pale optic discs with peripapillary atrophy, salmon pink retinal background, and creamy white retinal blood vessels. The arteries as well as veins had cream color from periphery to the disc and can be distinguished only by their size [3].



Right Eye

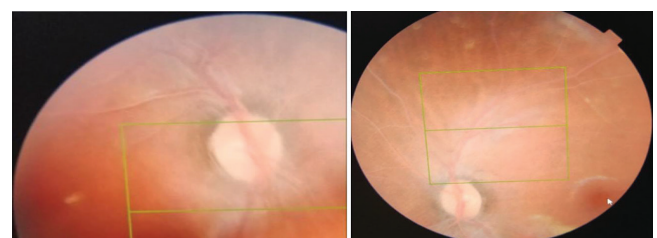
Left Eye

Genetic testing revealed that the patient was homozygous for a pathogenic variant in LPL gene associated with hyperlipoproteinemia type 1.

Breastfeeding was stopped and the baby was put on a diet of skimmed milk. Statins were administered to lower lipid levels.

Repeat ophthalmic examination was done on day 8 which showed slight improvement of lipemia retinal from grade 3 to grade 2 [2] (as we can see that vessels are less white near the disc whereas, in grade 3, vessels were white from periphery to the disc).

The appearance of blood became less milky and viscous.



Right Eye

Left Eye

DISCUSSION

The ocular findings in lipemia retinalis result from light scatter by TG-laden chylomicrons in plasma.

Chylomicrons are the largest lipoprotein macromolecules. The smaller lipoproteins do not contribute to the visible turbidity of serum. If a sample of hyperlipidemic serum is allowed to stand, chylomicrons form a milky layer. Light is not scattered by smaller lipoprotein molecules, giving a transparent appearance. Similar cases reported till now had signs of lipemia retinalis when TG levels were above 2500 mg/dL. However, in this infant, we observed lipemia retinalis when TG level was at 1180 mg/dL which makes this case report even more unique.

To the best of our knowledge, no other case of lipemia retinalis has been reported in a neonate as young as 24 days old which makes this case report unique.

CONCLUSION

Ophthalmic Examination is consistent with diagnosis of Lipemia Retinalis with genetic evaluation confirming LPL gene deficiency.

CONFLICTS OF INTEREST

Nil.

FUNDING

No financial interest.

Written informed consent of the patient's guardian was taken.

REFERENCES

1. Jain NC, Vanteri J, Shah PK, Narendran V. Lipemia retinalis in 1-month-old infant. *Oman J Ophthalmol.* 2017 Jan-Apr;10(1):50-1. doi: 10.4103/0974-620X.200698, PMID 28298868, PMCID PMC5338056
2. Shinkre ND, Usgaonkar UP. Lipemia retinalis in a 27 day old neonate: A case report. *Indian J Ophthalmol.* 2019 Jun;67(6):954-7. doi: 10.4103/ijo.IJO_1310_18, PMID 31124530, PMCID PMC6552622
3. Vinger PF, Sachs BA. Ocular manifestations of hyperlipoproteinemia. *Am J Ophthalmol.* 1970;70(4):569-73. doi: 10.1016/0002-9394(70)90890-1, PMID 5505473
4. Rayner S, Lee N, Leslie D, Thompson G. Lipaemia retinalis: A question of chylomicrons? *Eye (Lond).* 1996;10(5):603-8. doi: 10.1038/eye.1996.138, PMID 8977790