

A PROSPECTIVE STUDY OF DISPLACED MID-SHAFT CLAVICLE FRACTURES TREATED WITH INTRAMEDULLARY TITANIUM ELASTIC NAIL SYSTEMS

ANANTH A , RAVI PRAKASH* 

Department of Orthopaedics, Kurnool Medical College, Kurnool, Andhra Pradesh, India.

*Corresponding author: Ravi Prakash; Email: drravi1930@gmail.com

Received: 03 April 2024, Revised and Accepted: 29 May 2024

ABSTRACT

Objectives: Clavicle fractures are common injuries accounting for 2.6–4.0% of all fractures. It has been previously published that mid-third fractures constitute approximately 80% of all clavicle fractures. The two predominantly used procedures that are the current trend in the operative management of mid-shaft clavicle fractures are open reduction and plating and intramedullary nailing through minimal access. This study evaluated the efficacy of the titanium elastic nail system (TENS), a minimally invasive technique, in treating mid-shaft clavicle fractures.

Methods: From December 2022 to January 2024 with 24 patients who had plain radiographs showing a mid-shaft clavicle fracture, this study was conducted in our hospital which is a tertiary care facility. Patients were reviewed at 2 and 6 weeks, 3 and 6 months after surgery. Nails were removed after 6 months of surgery.

Results: The average operative time duration was 37.1 min (range: 25–60 min). 18 of the 24 patients had closed reduction while 6 patients (25%) required open reduction of their fracture. All the patients achieved clinical union at an average of 5.3 weeks (range: 4–6 weeks) and radiological union at an average of 10.47 weeks (range: 6–12 weeks). The patients were followed up postoperatively and CONSTANT and MURLEY scores were calculated at 6 weeks with an excellent CONSTANT score in 20 patients (83.3%).

Conclusion: Besides being early mobilization, minimally invasive, and requiring less time during surgery, TENS fixation offers superior cosmetic results. For this reason, the preferred course of treatment for displaced mid-shaft clavicle fractures is titanium elastic nails.

Keywords: Mid-shaft clavicle fracture, Titanium elastic nail systems, CONSTANT and MURLEY score.

© 2024 The Authors. Published by Innovare Academic Sciences Pvt Ltd. This is an open access article under the CC BY license (<http://creativecommons.org/licenses/by/4.0/>) DOI: <http://dx.doi.org/10.22159/ajpcr.2024v17i7.51040>. Journal homepage: <https://innovareacademics.in/journals/index.php/ajpcr>

INTRODUCTION

Clavicle fractures are common injuries accounting for 2.6–4.0% of all fractures [1]. It has been previously published that mid-third fractures constitute approximately 80% of all clavicle fractures. The management of adult clavicle fractures has seen significant change within the past two decades. Conventionally, mid-shaft clavicle fractures have been treated nonoperatively with the expectation of good clinical outcomes and a high rate of fracture union [2]. The two predominantly used procedures that are current trends in the operative management of mid-shaft clavicle fractures are open reduction and plating and intramedullary nailing through minimal access. The first instance of a novel method Jubel *et al.* introduced titanium elastic nail systems (TENSs), which are currently being promoted despite differing views regarding their applications [3,4]. With the aforementioned information in mind, this study was conducted to evaluate the efficacy of TENS, a minimally invasive technique, in treating mid-shaft clavicle fractures.

METHODS

From December 2022 to January 2024 with 24 patients who had plain radiographs showing a mid-shaft clavicle fracture, this study was conducted in our hospital which is a tertiary care facility and the institutional ethical review committee (IEC-KMC-GGH, dated August 29, 2022) approved the study, and each subject provided written informed consent.

The inclusion criteria of the study are clavicular mid-shaft fractures with displacement of fragments more than 2 cm on plain radiographs, clavicular length shortening more than 2 cm on plain radiography, and age more than 12 years. Exclusion criteria of the study are fractures

of more than 3 weeks, compound fractures, associated neurovascular injuries, and patients with ages <12 years.

Technique

The patient was placed in a beach chair position on a radiolucent table after receiving general or regional anesthesia. The side that is impacted is scrubbed and draped from the midline to the elbow joint. Before surgery, an image intensifier was used to scan the shoulder area for potential points of entry. Directly lateral to the sternoclavicular joint, a one-centimeter horizontal incision was created. Next, the entry point was created directly on the anterior cortex using the awl, or it could be predrilled using a 2.7 mm drill bit. T handle was used to introduce a 2–3 mm TENS nail. The endeavor is made to reduce closed under fluoroscopic guidance by manipulations. Percutaneous reduction clamps are used to aid in the reduction process. If closed approaches were not successful in reducing the fracture, a second, tiny incision was made at the fracture site to allow for direct manipulation of the fragments. To prevent irritation to the soft tissue, the nail is clipped short at the terminal, leaving sufficient length for a simple extraction later on.

Postoperatively, patients were given arm slings. Pendular exercises started on the 2nd postoperative day. After 1-week active range of movement exercises was started, however, overhead shoulder abduction was allowed only after 2 weeks. Patients were reviewed at 2 and 6 weeks, 3 and 6 months after surgery. Nails were removed after 6 months of surgery.

Outcome assessment

The affected clavicle was examined clinically and radiologically to know about implant position and fracture union. Functional outcome was

determined by the CONSTANT-MURLEY scoring system. According to this, 15 points are given to pain; 20 points are given to activity of daily living, 25 points for strength, and 40 points for range of motion. The results are based on points >55 poor, 56–70 moderate, 71–85 good, and >85 excellent.

RESULTS AND DISCUSSION

We had 24 patients in the follow-up group with 16 male and eight female patients with a mean age of 34.5 (range: 30–40 years) as shown in Tables 1 and 2.

Among these 18 patients (75%) had right clavicle fracture and six patients had on the left side as shown in Fig. 1.

All the patients were operated within 3 days following injury. The average operative time duration was 37.1 min (range: 25–60 min) (Table 3).

18 of the 24 patients had closed reduction while 6 patients (25%) required open reduction of their fracture. All the patients achieved clinical union at an average of 5.3 weeks (range: 4–6 weeks) and radiological union at an average of 10.47 weeks (range: 6–12 weeks). The patients were followed up postoperatively and CONSTANT and MURLEY scores were calculated at 6 weeks with excellent CONSTANT and MURLEY scores in 20 patients (83.3%) as shown in Table 4.

Two patients had medial prominence of the nail and discomfort but there was no skin perforation or infection and the fracture healed without any delay. One patient had a local skin infection which was resolved after a course of antibiotics. No other major complications such as nonunion, skin perforation, posterior cortex breach, and refracture were reported.

For clavicle fractures that are not displaced, the majority of orthopedic surgeons prefer to treat patients without surgery by employing strapping and sling support. Still, the best course of action for acute displaced middle-third clavicle fractures is debatable [5]. While most clavicle fractures in the middle third were treated conservatively and seemed to unit without incident, studies now reveal that increased nonunion and patient dissatisfaction rates are linked to it in the end outcome [6]. Both titanium nailing and plate osteosynthesis should theoretically offer benefits of their own. According to a biomechanical study, plate fixation produces a firmer fixation than nailing, which facilitates early recuperation [7]. Technically speaking, plate fixing is simple to execute and offers rotational control. Large wound size and implant prominence are drawbacks. The benefits of intramedullary nailing include a smaller incision, minimal periosteal stripping, and load-sharing device properties [8]. After union, titanium elastic nailing can be removed as an outpatient treatment with little dissection and a lower incidence of implant prominence [9]. Furthermore, maintaining the fracture hematoma during nailing offers the benefit of accelerating fracture healing if closed reduction is accomplished. One of its drawbacks is that it lacks rotational control. It is especially concerning when TEN protrusion causes discomfort to the implant.

In our study, the mean age of the patients with mid-clavicular fracture is found to be 34.5 years (range of 30–40) which is similar to the Abraham *et al.* [10] study where the mean age is 35 years. In other studies, like Saraf and Kasture [11], the mean age is 38.6 years and 37.5 years, respectively. From our results, displaced mid-clavicular fractures are more common in males and on the right sides. The average operative time in our study is 37.1 min, whereas the operative time in Saraf and Kasture [11] study was 34.3 min.

Postoperatively, the radiological union is obtained at an average of 10.47 weeks in our study whereas the average of 10.23 weeks and 11.83 weeks was observed in Saraf and Kasture [11], Abraham *et al.* [10] studies, respectively. At 6-month follow-up, according to the CONSTANT-MURLEY score, excellent results were observed in 83.3% of patients in our study, whereas in Saraf and Kasture [11] study, excellent

Table 1: Sex distribution

Sex	Number of patients	Percentage
Male	16	66.7
Female	8	33.3

Table 2: Age distribution

Age	Number of patients	Percentage
20–30 years	7	29.2
30–40 years	12	50
>40 years	5	20.8

Table 3: Operative time

Operative time	Number of patients	Percentage
15–30 min	8	33.3
30–45 min	10	41.7
>45 min	6	25

Table 4: CONSTANT-MURLEY scores

Grading	Score	Number of patients	Percentage
Excellent	86–100	20	83.3
Good	71–85	4	16.7
Moderate	56–70	-	-
Poor	<55	-	-

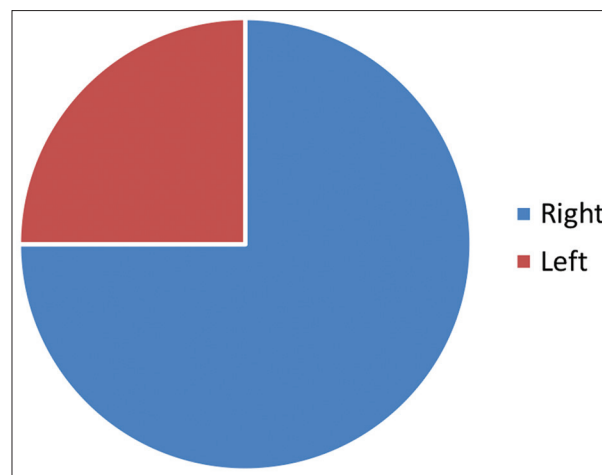


Fig. 1: Side distribution

scores were observed in 94.28 patients. Other studies Abraham *et al.* [10] show excellent scores in 70% and 97.8% of the patients.

CONCLUSION

Besides being early mobilization, minimally invasive, and requiring less time during surgery, TENS fixation offers superior cosmetic results. For this reason, the preferred course of treatment for displaced mid-shaft clavicle fractures is titanium elastic nails. When treating multi-fragmentary clavicle fractures, TENS fixation was associated with an increased risk of early postoperative discomfort and migration. Thus, plate fixation can be used to treat them.

ACKNOWLEDGMENT

We would like to express our gratitude to the orthopedic department at the government general hospital Kurnool for their valuable support throughout the study.

AUTHOR'S CONTRIBUTION

All authors participated in every aspect of the study, including conceptualization, design, data collection, data analysis, interpretation, manuscript preparation, critical review, and approval of the final version to be published.

CONFLICTS OF INTEREST

The authors confirm that they have no conflicts of interest related to this research, authorship, and publication of this article.

FUNDING

No funding from governmental, private, or nonprofit institutions was used for this study.

Limitations

The study limitations are loss of follow-up of patients, selection bias, and short period.

REFERENCES

1. Nordqvist A, Petersson C. The incidence of fractures of the clavicle. *Clin Orthop Relat Res.* 1994;300:127-32.
2. Park JS, Ko SH, Hong TH, Ryu DJ, Kwon DG, Kim MK, *et al.* Plate fixation versus titanium elastic nailing in mid-shaft clavicle fractures based on fracture classifications. *J Orthop Surg (Hong Kong).* 2020;28(3):1-11. doi: 10.1177/2309499020972204
3. Jubel A, Andermahr J, Schiffer G, Tsironis K, Rehm KE. Elastic stable intramedullary nailing of midclavicular fractures with a titanium nail. *Clin Orthop Relat Res.* 2003;408:279-85. doi: 10.1097/00003086-200303000-00037
4. Kadakia AP, Rambani R, Qamar F, McCoy S, Koch L, Venkateswaran B. Titanium elastic stable intramedullary nailing of displaced midshaft clavicle fractures: A review of 38 cases. *Int J Shoulder Surg.* 2012;6(3):82-5. doi: 10.4103/0973-6042.102557
5. Zlowodzki M, Zelle BA, Cole PA, Jeray K, McKee MD; Evidence-Based Orthopaedic Trauma Working Group. Treatment of acute midshaft clavicle fractures: Systematic review of 2144 fractures: On behalf of the Evidence-Based Orthopaedic Trauma Working Group. *J Orthop Trauma.* 2005;19(7):504-7. doi: 10.1097/01.bot.0000172287.44278.ef
6. Hill JM, McGuire MH, Crosby LA. Closed treatment of displaced middle-third fractures of the clavicle gives poor results. *J Bone Joint Surg Br.* 1997;79(4):537-9. doi: 10.1302/0301-620x.79b4.7529
7. Golish SR, Oliviero JA, Francke EI, Miller MD. A biomechanical study of plate versus intramedullary devices for midshaft clavicle fixation. *J Orthop Surg Res.* 2008 Jul 16;3:28. doi: 10.1186/1749-799X-3-28
8. Gadegone WM, Lokhande V. Screw intramedullary elastic nail fixation in midshaft clavicle fractures: A clinical outcome in 36 patients. *Indian J Orthop.* 2018;52(3):322-7. doi: 10.4103/ortho.IJOrtho_381_16
9. McKee M. Elastic stable intramedullary nailing was effective in displaced midshaft clavicular fractures. *J Bone Joint Surg Am.* 2009;91(11):2746. doi: 10.2106/JBJS.9111.ebo443
10. Abraham VT, Marimuthu C. A study on the outcome of displaced midshaft non-comminuted clavicle fractures treated with anatomical locking plate versus titanium elastic nail. *J Orthop Trauma Rehabil.* 2020:1-5. doi: 10.1177/2210491720975189
11. Saraf H, Kasture S. Treatment of displaced mid-clavicle fractures by closed titanium elastic nail. *Surg Sci.* 2016;7:49-53. doi: 10.4236/ss.2016.72006