

TO REPORT A CASE OF OCULAR ZONOTIC INFESTATION OF *DIROFILARIA REPENS*

KHUSHDEEP KAUR*, REENA KUMARI, DINESH KUMAR BHAGAT, SANJAY BOSAK

Department of Ophthalmology, Mata Gujri Memorial Medical College and L.S.K Hospital, Kishanganj, Bihar, India.

*Corresponding author: Khushdeep Kaur; Email: kaurdrkhushdeep@gmail.com

Received: 8 April 2024, Revised and Accepted: 26 May 2024

ABSTRACT

To report a case of ocular zoonotic infestation of *Dirofilaria Repens*.

Keywords: *Dirofilaria repens*, Zoonosis, Eosinophilia, Parasite.

© 2024 The Authors. Published by Innovare Academic Sciences Pvt Ltd. This is an open access article under the CC BY license (<http://creativecommons.org/licenses/by/4.0/>) DOI: <http://dx.doi.org/10.22159/ajpcr.2024v17i6.51420>. Journal homepage: <https://innovareacademics.in/journals/index.php/ajpcr>

INTRODUCTION

Dirofilaria infestation is uncommon in humans and rarely involves eyes. A parasite name *Dirofilaria* which belongs to family *Onchocercidae* of order spirudia and phylum *Nematoda* causes this disease. It is transmitted by mosquito bite to humans, as they

are reproductively inactive in humans so no systemic treatment is required.

CASE REPORT

A 42 year old male patient came to outpatient department with chief complaint of swelling in the right eye laterally associated with redness, pain and foreign body sensation for 3 days. By occupation, he was a

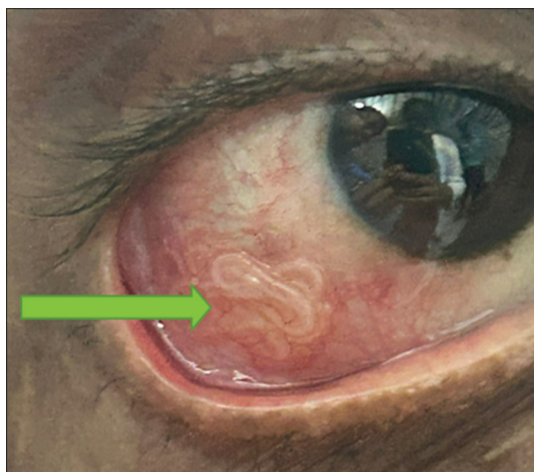

Fig. 1: On torch examination

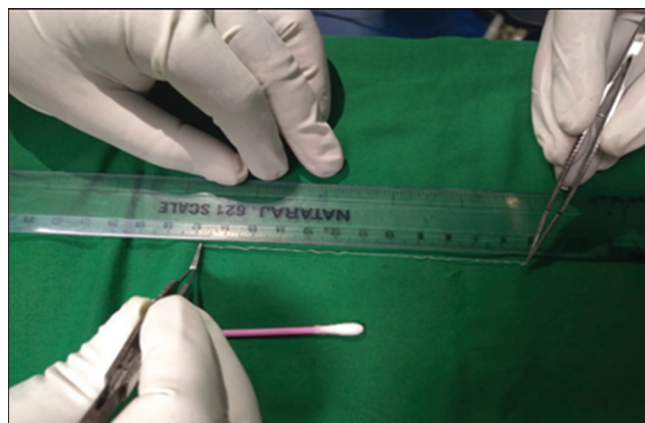


Fig. 3: Length of worm measured by scale was 12 cm

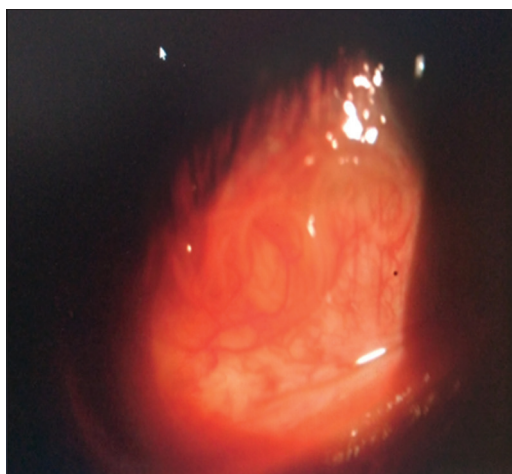


Fig. 2: On slit lamp examination

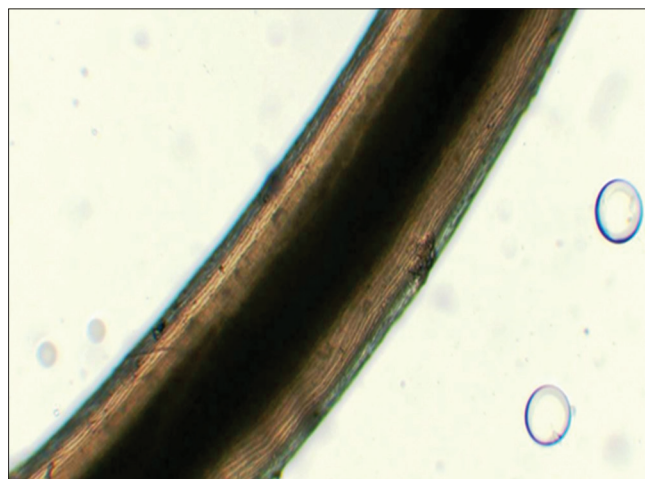


Fig. 4: Longitudinal cuticular ridges

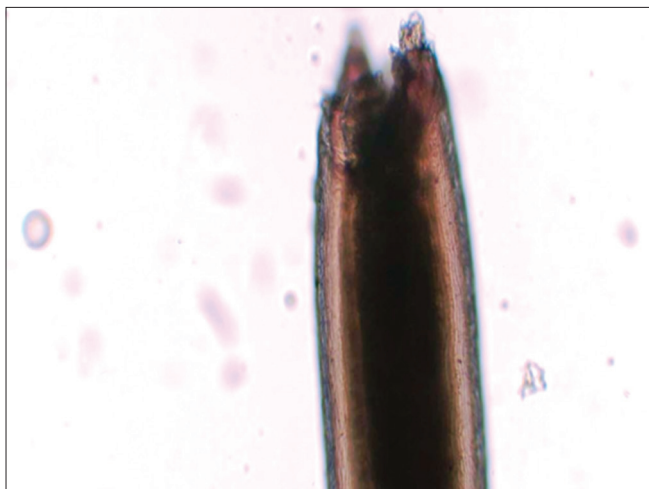

Fig. 5: Damaged anterior end of worm which was damaged during transportation and fixation process

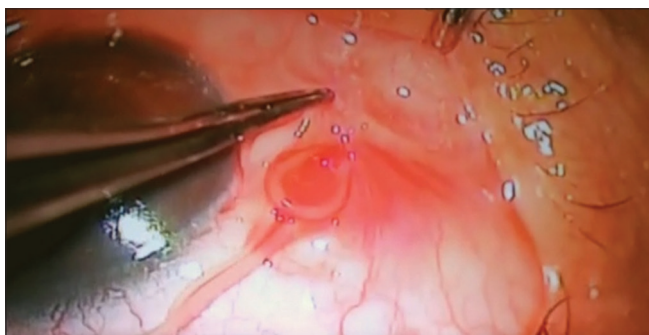

Fig. 6: Worm removed by holding with forceps

farmer with live-stock rearing and handling with street dogs. The best corrected visual acuity in both eyes was 6/6. On slit lamp examination, the right eye showed swelling, hyperemia, and moving worm under bulbar conjunctiva (Fig. 2) rest anterior segment unremarkable. Left eye anterior segment unremarkable. Both eyes posterior segment unremarkable.

Laboratory investigations revealed on peripheral blood smear normocytic and normochromic eosinophilia. Stool culture showed eggs of *strongyloides stercoralis*. Urine routine and culture were normal. Abdominal ultrasound and chest X-ray were normal. Gross microbiological examination was done and depending on the morphological features (Figs. 3-5) it was diagnosed as *Dirofilaria repens* worm. Provisional diagnosis was made of *D. repens* worm.

Treatment

Urgent removal of worm was done by making conjunctival incision with scissor and then live worm was removed by holding with forceps (Fig. 6). Procedure was done under topical anesthesia. Patient was given antibiotic and anti-inflammatory drops for 1 week and eye was quite in follow-up visits.

DISCUSSION

Dirofilaria infestation in eyes occurs rarely. Their definitive hosts are dogs, cats, raccoon, bear, and other wild animals. Mosquitoes (*Aedes*, *Culex*, *Anopheles*) are intermediate hosts. Transmission to humans occurs through mosquito bite. They are reproductively inactive in humans, so no systemic treatment is required. Humans are most commonly affected by species named *D. repens* and *Dirofilaria immitis*. In eyes *Dirofilaria* can be found subconjunctivally, or in tenon's layer, periorbital tissue (lids, orbit) [1,2] and intraocularly (anterior chamber [3], vitreous). Based on microscopic morphological features like cephalic spaces, longitudinal ridges, and total length, diagnosis was made. The longitudinal ridges are characteristic feature of *D. repens*, as these are absent in *D. immitis* [4].

CONCLUSION

Ocular infection by *Dirofilaria* is not commonly known. However, as the incidences are increasing of ocular infection, it necessitates awareness among ophthalmologists and public.

ETHICAL APPROVAL

The study was approved by the institutional ethical committee.

CONFLICT OF INTEREST

Nil.

FUNDING

No financial interest.

Written informed consent of the patient's guardian was taken.

REFERENCES

1. Melsom HA, Kurtzhals JA, Qvortrup K, Bargum R, Barfod TS, La Cour M, et al. Subconjunctival *Dirofilaria repens* infestation: A light and scanning electron microscopy study. *Open Ophthalmol J*. 2011;5:21-4. doi: 10.2174/1874364101105010021, PMID: 21738560, PMCID: PMC3104560
2. Mittal M, Sathish KR, Bhatia PG, Chidamber BS. Ocular dirofilariasis in Dubai, UAE. *Indian J Ophthalmol*. 2008 Jul-Aug;56(4):325-6. PMID: 18579995, PMCID: PMC2636165
3. Chopra R, Bhatti SM, Mohan S, Taneja N. *Dirofilaria* in the anterior chamber: A rare occurrence. *Middle East Afr J Ophthalmol*. 2012 Jul-Sep;19(3):349-51. doi: 10.4103/0974-9233.97965, PMID: 22837635, PMCID: PMC3401811
4. Sathyan P, Manikandan P, Bhaskar M, Padma S, Singh G, Appalaraju B. Subtenons infection by *Dirofilaria repens*. *Indian J Med Microbiol*. 2006 Jan;24(1):61-2. doi: 10.4103/0255-0857.19899, PMID: 16505560