

## CLINICAL PROFILE AND IMAGING FINDINGS IN PEDIATRIC PATIENTS PRESENTING WITH RECURRENT ABDOMINAL PAIN

KARTHIKEYAN ANNADURAI<sup>1\*</sup>, JULIET ANITHA SEAN MARTIN<sup>2</sup>

<sup>1</sup>Department of Pediatrics, Nalam Child Centre, Chennai, Tamil Nadu India. <sup>2</sup>Department of Pediatrics, SJ clinic, Coimbatore, Tamil Nadu India.

\*Corresponding author: Karthikeyan Annadurai; Email: kannadurai19@gmail.com

Received: 12 June 2024, Revised and Accepted: 15 July 2024

### ABSTRACT

**Objectives:** The objective of this study was to analyze clinical features and ultrasonography (USG) abnormalities in children presenting with recurrent abdominal pain (RAP).

**Methods:** This was prospective observational study conducted in the department of pediatrics of a tertiary care medical college. Children between 1 and 18 years of age were included in this study. Demographic details such as age and gender were noted. History of abdominal pain, its duration, and number of episodes in past 3 months were enquired and noted. A thorough clinical examination including per abdominal examination was done in all cases. Basic investigations such as urine and stool analysis, complete blood count, erythrocyte sedimentation rate, and C-reactive protein levels were done in all cases. USG abdomen was done in all cases and its findings were analyzed. The Statistical Package for the Social Sciences 22.0 software was used for statistical analysis and  $p < 0.05$  was taken as statistically significant.

**Results:** Among 80 pediatric patients with RAP, boys predominated (57.50%). The mean age was similar between boys and girls, with no statistically significant difference. The most affected age group was 9–12 years. The most common frequency of pain episodes was 4 times in 3 months (46.25%), with a typical episode lasting 1–10 min (27.5%). The umbilical region was the most common pain site (25.00%). Ultrasound findings showed no abnormalities in 80% of cases, with enlarged mesenteric lymph nodes being the most common abnormal finding (13.75%) on USG.

**Conclusion:** Although ultrasound often shows no abnormalities in children with RAP, it is a crucial diagnostic tool for identifying potential conditions needing further evaluation. Even normal results offer reassurance to parents by ruling out serious medical conditions.

**Keywords:** Children, Recurrent abdominal pain, Ultrasound, Mesenteric lymphadenopathy.

© 2024 The Authors. Published by Innovare Academic Sciences Pvt Ltd. This is an open access article under the CC BY license (<http://creativecommons.org/licenses/by/4.0/>) DOI: <http://dx.doi.org/10.22159/ajpcr.2024v17i8.52409>. Journal homepage: <https://innovareacademics.in/journals/index.php/ajpcr>

### INTRODUCTION

Recurrent abdominal pain (RAP) is defined, by the Appley criteria, as three or more episodes of abdominal pain severe enough to affect activities over a period of at least 3 months [1]. RAP is a significant cause of distress for children and their families. The prevalence of RAP in children is estimated to be between 10% and 20%, with a slight predominance in girls. Common causes of RAP in the pediatric age group can be broadly categorized into organic and functional disorders [2]. Organic causes include gastrointestinal conditions such as peptic ulcers, inflammatory bowel disease, and celiac disease, as well as non-gastrointestinal conditions such as urinary tract infections and gynecological issues in adolescent girls. Functional disorders, which are more common, include functional dyspepsia, irritable bowel syndrome (IBS), and abdominal migraine [3].

The clinical presentation of pediatric patients with RAP can vary widely thereby posing a challenge to treating pediatrician. In these children, the pain is usually periumbilical and non-radiating. In many cases, it is associated with other gastrointestinal symptoms such as nausea, vomiting, diarrhea, or constipation [4]. Children may also complain of non-specific symptoms such as fatigue, headache, or dizziness. Notably, a significant number of children, particularly adolescents, with RAP experience psychosocial problems such as anxiety, depression, or family dysfunction which can exacerbate or even trigger their symptoms. Although in many cases the cause of RAP is not organic, a thorough clinical history and physical examination is essential to identify any red flag sign that might suggest an organic cause. These red flags include weight loss, growth retardation,

nocturnal pain, gastrointestinal bleeding, or a positive family history of gastrointestinal diseases [5].

The approach for management of pediatric patients with RAP requires a careful evaluation to distinguish between organic and functional causes. Initial assessment involves a detailed history and physical examination. Baseline laboratory investigations, including complete blood count, erythrocyte sedimentation rate, C-reactive protein, and stool studies, can help rule out inflammatory or infectious causes [6]. Specific tests such as serological tests for *Helicobacter pylori* infection and urinary analysis may be warranted based on clinical suspicion. Imaging studies play an important role in the evaluation of RAP. Abdominal ultrasound is often the first-line imaging modality due to its non-invasive nature and ability to detect common causes of abdominal pain such as hydronephrosis, gallstones, or ovarian cysts. In selected cases further imaging with upper gastrointestinal series, abdominal computed tomography scan or magnetic resonance imaging may be indicated to evaluate for less common conditions such as malrotation, mesenteric lymphadenitis, or small bowel pathology [7].

Management of RAP in children is primarily guided by the underlying cause. In cases where an organic cause of RAP is identified, specific treatments targeting the identified condition are essential [8]. For example, children diagnosed with celiac disease require a strict gluten-free diet whereas those with inflammatory bowel disease may need immunosuppressive therapy. Functional abdominal pain disorders can be managed with a combination of reassurance, dietary modifications, and pharmacotherapy. Probiotics, antispasmodics, and fiber supplements may be useful in some cases of IBS [9].

Despite extensive research, significant gaps remain in the understanding and management of RAP in children [10]. The exact pathophysiological mechanisms underlying functional abdominal pain disorders are not fully elucidated. This study was undertaken to analyze clinical profile and imaging findings in pediatric patients presenting with RAP.

## METHODS

This was a prospective observational study conducted in the department of pediatrics of a tertiary care medical institute. Eighty pediatric patients presenting with RAP were included in this study on the basis of a predefined inclusion and exclusion criteria. The duration of study was 1 year. Sample size was calculated on the basis of pilot studies done on the topic of abdominal pain in children. Keeping the power (1-Beta error) at 80% and the confidence interval (1-Alpha error) at 95%, the minimum sample size required was 76 patients; therefore, we included 80 children presenting with RAP in this study.

Demographic details such as age, gender, and socioeconomic status of all patients were recorded. In all patients, a detailed history was obtained either from patient or guardian. Duration and number of episodes of abdominal pain particularly in past 3 months were asked for and noted. Severity of abdominal pain was assessed on the basis of history by asking whether the abdominal pain was severe enough to affect the daily activities. Appley's criteria were used for defining RAP.

The presence of respiratory issues associated with gastroesophageal reflux such as chronic cough or reactive airway disease was also asked and noted. A thorough clinical examination including per abdominal examination was done in all cases. Basic investigations such as urine and stool analysis, complete blood count, erythrocyte sedimentation rate, and C-reactive protein levels were done in all cases. Imaging studies in the form of ultrasound examination were done in all the cases. In selected cases, computed tomography was done. Clinical features and imaging findings of all cases were analyzed and final etiological diagnosis was determined.

Statistical analysis was done using the Statistical Package for the Social Sciences version 22.0 software. Quantitative data were presented as mean and standard deviation. Qualitative data were presented with incidence and percentage tables. For quantitative data, paired t-test, and for qualitative data, Chi-square test was used.  $p < 0.05$  was taken as statistically significant.

### Inclusion criteria

The following criteria were included in the study:

1. Patients having history of abdominal pain since at least 3 months and over this 3-month period, there are at least three episodes of pain that are severe enough to affect the daily activities.
2. Age group of 1 year to 18 years.
3. Parents/guardians gave written informed consent to be part of study.

### Exclusion criteria

The following criteria were excluded from the study:

1. Age <1 year or above 18 years.
2. Refusal by parents/guardians to give consent to be part of the study.
3. History of major abdominal surgery in past.
4. History of significant psychiatric disorders.
5. Pregnant adolescents, due to potential confounding factors related to pregnancy.

## RESULTS

Out of 80 pediatric patients presenting with history of RAP, there were 46 (57.50%) boys and 34 (42.50%) girls. There was a male preponderance in studied cases with M:F ratio of 1:0.73 (Fig. 1).

The analysis of the age distribution among the studied cases showed that in the 1-4 years age group, there were 9 boys (11.25%) and 7 girls (8.75%). The 5-8 years age group had 7 boys (8.75%) and 8 girls (10.00%). The 9-12 years age group had the highest representation,

with 19 boys (23.75%) and 12 girls (15.00%). In the 13-16 years age group, there were 8 boys (10.00%) and 5 girls (6.25%). The 17-18 years age group had the fewest cases, with 3 boys (3.75%) and 2 girls (2.50%). The mean age for boys was  $9.48 \pm 4.46$  years, while for girls, it was  $8.91 \pm 3.92$  years. The mean age of boys and girls was found to be comparable with no statistically significant difference ( $p = 0.5540$ ) (Table 1).

The analysis of the number of episodes of significant abdominal pain in the past 3 months among the studied cases showed that the most common frequency was 4 episodes, reported by 37 children (46.25%). This was followed by 3 episodes, experienced by 21 children (26.25%), and 5 episodes, reported by 13 children (16.25%). A smaller proportion of children, 9 (11.25%), experienced more than 5 episodes (Table 2).

The analysis of the mean duration of episodes of abdominal pain revealed that the most common duration was 1-10 min, experienced by 22 patients (27.5%). This was closely followed by durations of more than 30 min, reported by 21 patients (26.2%). Episodes lasting 21-

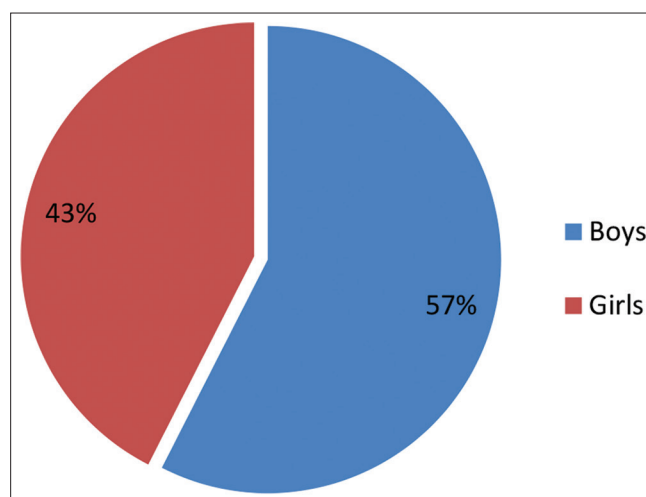


Fig. 1: Gender distribution of studied cases

Table 1: Gender-wise age distribution of children with recurrent abdominal pain

Age Group (Years)	Boys		Girls	
	Number	Percentage	Number	Percentage
1-4	9	11.25	7	8.75
5-8	7	8.75	8	10.00
9-12	19	23.75	12	15.00
13-16	8	10.00	5	6.25
17-18	3	3.75	2	2.50
Total	46	57.50	34	42.50
Mean	$9.48 \pm 4.46$		$8.91 \pm 3.92$	
Age $\pm$ Standard deviation (years)				

$P = 0.5540$  (Not significant)

Table 2: Number of episodes of significant abdominal pain in the past 3 months

Number of episodes of significant abdominal pain in last 3 months	Number	Percentage
3	21	26.25
4	37	46.25
5	13	16.25
More than 5	9	11.25
Total	80	100.00

30 min were noted by 19 patients (23.8%), while 18 patients (22.5%) reported episodes lasting 11–20 min. Mean duration of each episode of abdominal pain was 21.24±9.12 min (Table 3).

The most common site of abdominal pain was the umbilical region, accounting for 20 cases (25.00%). This was followed by the right iliac (or inguinal) region with 15 cases (18.75%) and the hypogastric (or suprapubic) region with 11 cases (13.75%). Other notable regions included the left iliac (or inguinal) region with 9 cases (11.25%), the epigastric region with 7 cases (8.75%), and both the right and left lumbar (or lateral) regions, each with 6 cases (7.50%). The right hypochondriac and left hypochondriac regions were the least common sites, each reported in 3 cases (3.75%) (Table 4).

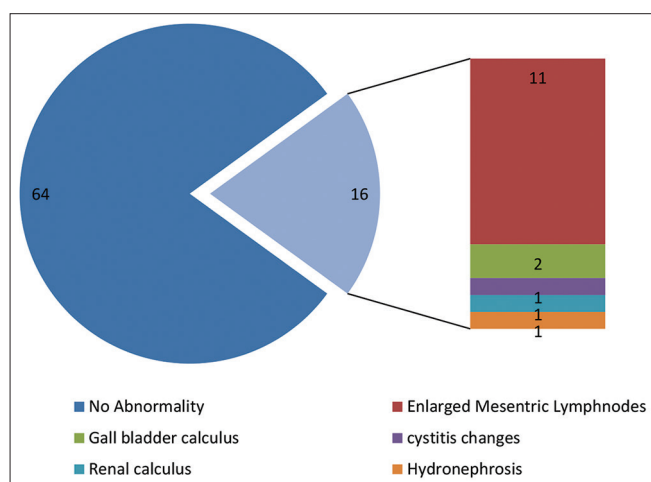
The analysis of the ultrasound findings indicated that a significant majority of the cases, 80%, showed no abnormality. Among the abnormal findings, the most common was the presence of enlarged mesenteric lymph nodes, observed in 11 (13.75%) of the cases. Gallbladder calculus was found in 2 (2.50%) of the cases. Less common findings included cystitis changes, renal calculus, and hydronephrosis, each accounting for 1.25% of the cases (Fig. 2).

**Table 3: Mean duration of episodes of abdominal pain (in minutes)**

Mean duration of episodes of abdominal pain (in minutes)	Number	Percentage
01–10	22	27.50
11–20	18	22.50
21–30	19	23.75
>30	21	26.25
Total	80	100.00
Mean Duration of episode	21.24±9.12 min	

**Table 4: Site of abdominal pain in studied cases**

Site of abdominal pain	Number	Percentage
Right hypochondriac region	3	3.75
Epigastric region	7	8.75
Left hypochondriac region	3	3.75
Right lumbar (or lateral) region	6	7.50
Umbilical region	20	25.00
Left lumbar (or lateral) region	6	7.50
Right iliac (or inguinal) region	15	18.75
Hypogastric (or suprapubic) region	11	13.75
Left iliac (or inguinal) region	9	11.25



**Fig. 2: Ultrasound abdomen findings in studied cases**

## DISCUSSION

RAP in children is a common and clinical problem accounting for a significant proportion of pediatric consultations. Despite the high prevalence, RAP presents a diagnostic challenge due to the overlap of symptoms between functional and organic causes necessitating a thorough and systematic approach to evaluation [11].

In this study, there was a male preponderance in studied cases with M:F ratio of 1:0.73. The mean age for boys was 9.48±4.46 years, while for girls, it was 8.91±3.92 years. Hirekerur and Bhagawat conducted a study to Study the profile of RAP in children examined by ultrasonography (USG) [12]. In this study, the authors found that maximum numbers (46%) of patients were from 5 to 8 years age group, greater number of boys (54%) were affected as compared to girls. Maximum (62%) patients had total of 1–5 episodes. About 30% of patients had school loss due to pain abdomen. The male preponderance reported in this study was similar to our study. However, the authors such as Devanarayana *et al.* [13] and Boey *et al.* [14] reported RAP to be more common in girls as compared to boys.

The analysis of characteristics of abdominal pain showed that the mean duration of abdominal pain was 21.24±9.12 min. The most common site of abdominal pain was the umbilical region, followed by the right iliac (or inguinal) region and the hypogastric (or suprapubic) region. Mehrotra *et al.* conducted a study to evaluate the profile of RAP in children examined by clinical examination and USG [15]. The authors prospectively studied 100 patients within age range from 1 to 16 years presenting with abdominal pain of various etiological causes. In this study, the most common site of abdominal pain was periumbilical (35%) followed by right lower, right upper, left upper, and left lower quadrant. Finding of periumbilical pain to be most common site of pain in cases of children with RAP in this study was similar to our study. Similar location of pain in cases of RAP was also reported by the authors such Quek *et al.* [16] and Balani *et al.* [17].

In this study, the most common abnormality on ultrasound examination was found to be the presence of enlarged mesenteric lymph nodes which were observed in 11 (13.75%) of the cases. The other abnormal USG findings included gallbladder calculus 2 (2.50%), cystitis changes (1.25%), renal calculus (1.25%), and hydronephrosis (1.25%). van der Meer *et al.* conducted a prospective study to investigate the diagnostic value of ultrasound in children with RAP and to estimate the clinical relevance of rare organic causes [18]. For this purpose, the authors undertook a study comprising 93 children aged 5.5–12 years, using abdominal ultrasound. The study found that only 3 patients (3.2%) had an anatomical abnormality, which was not related to their abdominal pain. Similar findings were also reported by the authors such as Yip *et al.* [19] and Manson [7].

It is important to note that most of the children presenting with RAP were not found to have any imaging abnormality on ultrasound examination of abdomen and pelvis. However, still ultrasound examination is indicated for two reasons. First, in some cases, USG may show abnormalities such as mesenteric lymphadenopathy, hydronephrosis, cystitis, and gallbladder calculus or in cases of adolescent girl's pathologies such as ovarian cyst and ovarian torsions [19]. Some of these pathologies may require further evaluation and appropriate interventions. Second, absence of any significant pathology on ultrasound will be helpful in reassuring parents about absence of any serious abdominal pathology that may require interventions.

## CONCLUSION

While ultrasound often does not reveal abnormalities in children with RAP, it remains an important diagnostic tool. In some cases, USG can help identify conditions that may require further evaluation and treatment, and even when results are normal, it provides reassurance to parents by confirming the absence of serious issues.

**CONFLICTS OF INTEREST**

None.

**REFERENCES**

1. Plunkett A, Beattie RM. Recurrent abdominal pain in childhood. *J R Soc Med.* 2005;98(3):101-6. doi: 10.1177/014107680509800304
2. McGrath PJ, Feldman W. Clinical approach to recurrent abdominal pain in children. *J Dev Behav Pediatr.* 1986;7(1):56-63. doi: 10.1097/00004703-198602000-00010
3. Altamimi EM, Al-Safadi MH. Abdominal pain-predominant functional gastrointestinal disorders in Jordanian school children. *Gastroenterology Res.* 2014;7(5-6):137-42. doi: 10.14740/gr627w
4. Bufler P, Gross M, Uhlig HH. Recurrent abdominal pain in childhood. *Dtsch Arztebl Int.* 2011;108(17):295-304. doi: 10.3238/arztebl.2011.0295
5. Motamed F, Mohsenipour R, Seifirad S, Yusefi A, Farahmand F, Khodadad A, *et al.* Red flags of organic recurrent abdominal pain in children: Study on 100 subjects. *Iran J Pediatr.* 2012;22(4):457-62.
6. Friesen C, Colombo JM, Deacy A, Schurman JV. An update on the assessment and management of pediatric abdominal pain. *Pediatric Health Med Ther.* 2021;12:373-93. doi: 10.2147/PHMT.S287719
7. Manson D. Contemporary imaging of the child with abdominal pain or distress. *Paediatr Child Health.* 2004;9(2):93-7. doi: 10.1093/pch/9.2.93
8. Miranda A, Sood M. Treatment options for chronic abdominal pain in children and adolescents. *Curr Treat Options Gastroenterol.* 2006;9(5):409-15. doi: 10.1007/BF02738530
9. Thapar N, Benninga MA, Crowell MD, Di Lorenzo C, Mack I, Nurko S, *et al.* Paediatric functional abdominal pain disorders. *Nat Rev Dis Primers.* 2020;6(1):89. doi: 10.1038/s41572-020-00222-5
10. Rajindrajith S, Zeevenhooven J, Devanarayana NM, Perera BJ, Benninga MA. Functional abdominal pain disorders in children. *Expert Rev Gastroenterol Hepatol.* 2018;12(4):369-90. doi: 10.1080/17474124.2018.1438188
11. Paul SP, Candy DC. Clinical update: Recurrent abdominal pain in children. *Community Pract.* 2013;86(11):48-51.
12. Hirekerur V, Bhagawat A. Study profile of recurrent pain abdomen in children examined by USG. *Int J Contemp Pediatr.* 2016;3:1197-9.
13. Devanarayana NM, de Silva DG, de Silva HJ. Recurrent abdominal pain syndrome in a cohort of Sri Lankan children and adolescents. *J Trop Pediatr.* 2008;54:178-83.
14. Boey CC, Yap S, Goh KL. The prevalence of recurrent abdominal pain in 11- to 16-year-old Malaysian schoolchildren. *J Paediatr Child Health.* 2000;36:114-6.
15. Mehrotra GK, Gupta A, Jain P, Mulye S. Study profile of recurrent abdominal pain in children examined by clinical examination and ultrasonography. *J Evol Med Dent Sci.* 2018;7(7):860-3. doi: 10.14260/jemds/2018/196
16. Quek SH. Recurrent abdominal pain in children: A clinical approach. *Singapore Med J.* 2015;56(3):125-32. doi: 10.11622/smedj.2015038
17. Balani B, Patwari AK, Bajaj P, Diwan N, Anand VK. Recurrent abdominal pain - A reappraisal. *Indian Pediatr.* 2000;37:876-81.
18. van der Meer SB, Forget PP, Arends JW, Kuijten RH, van Engelshoven JM. Diagnostic value of ultrasound in children with recurrent abdominal pain. *Pediatr Radiol.* 1990;20(7):501-3. doi: 10.1007/BF02011375
19. Yip WC, Ho TF, Yip YY, Chan KY. Value of abdominal sonography in the assessment of children with abdominal pain. *J Clin Ultrasound.* 1998;26(8):397-400. doi: 10.1002/(sici)1097-0096(199810)26:8<397:aid-jcu4>3.0.co;2-d