

SEIZURES WITH ANTI-SEIZURE DRUG**KEERTHANA BRATTIYA R, BHUVANESHWARI K**¹Department of Pharmacology, Government Kilpauk Medical College, Chennai, Tamil Nadu, India. ²Department of Pharmacology, PSG Institute of Medical Sciences and Research, Coimbatore, Tamil Nadu, India. Email: dazze87@gmail.com*Received: 14 July 2016, Revised and Accepted: 13 September 2017***ABSTRACT**

This case study is to report and explore the etiology of a case of refractory seizures due to overdosage of phenytoin tablets. A case report from the Department of Neurology generated through voluntary adverse drug reaction (ADR) reporting stated phenytoin overdosage leading to refractory status epilepticus which did not respond to any of the antiepileptic drugs. A 33-year-old female patient with the history of consumption 15 tablets of phenytoin and a metal ring as part of a suicidal bid a month ago, presented with unconsciousness, persistent seizures, and gangrene of fingers. Magnetic resonance imaging showed generalized atrophic changes of the cerebrum and cerebellum. Electroencephalogram suggested multifocal onset status epilepticus. The patient did not respond to standard emergency treatment of status epilepticus with known antiepileptic drugs and was treated with thiopentone infusion under mechanical ventilation, which controlled her seizures as long as she was maintained under the infusion. Causality analysis using the World Health Organization scale categorizes this ADR as "possible", as the patient is a known case of seizure disorder with additional cerebral changes. Hence, the disease could have had an influence over the toxic reaction. To conclude, seizures are a rare complication of phenytoin. Seizures can be prevented by evaluating therapeutic plasma concentration of phenytoin. In this case, the patient was on chronic treatment, and due to intentional toxicity, she progressed to a refractory state of seizures. This could have occurred because of the unique kinetic profile of phenytoin, small therapeutic index, genetic variation in drug metabolizing enzymes, and saturated sodium channels.

Keywords: Phenytoin, Refractory seizures, Small therapeutic index, Zero order kinetics.

© 2017 The Authors. Published by Innovare Academic Sciences Pvt Ltd. This is an open access article under the CC BY license (<http://creativecommons.org/licenses/by/4.0/>) DOI: <http://dx.doi.org/10.22159/ajpcr.2017.v10i12.21285>

INTRODUCTION

Phenytoin is a non-sedative antiepileptic drug that blocks the high-frequency firing of voltage-gated sodium channels and decreases the release of synaptic glutamate. It is highly plasma protein bound, and no active metabolites are formed. Phenytoin seems to be the most commonly used and studied antiepileptic agent, and its side effects and toxicity symptoms are well documented [1]. Seizures due to phenytoin have been reported in few cases. The novelty of this case report is that we have discussed about elimination kinetics in detail.

CASE REPORT

A 33-year-old patient known case of seizure disorder on treatment for 3 years was apparently alright till she consumed 15 tablets of phenytoin (100 mg) and a metal ring as she had a conflict with her mother in law. She went to bed normally. 8 hrs later, she developed confused irrelevant speech. She was able to speak and said that she consumed the tablets and the ring. A day later, she developed clonic jerky movements of bilateral upper limb and side-to-side movement of the head. The following day she became unconscious with persisting jerky movements. On the 10th day, she developed dry gangrene of bilateral fingers (left 3, 4, and 5 and right 4 and 5). The patient had continuous seizures for nearly 2 months with bilateral pupils well reacting to light with preserved doll's eye movements. The right upper limb was spastic and flexed, and deep tendon reflexes were depressed. Magnetic resonance imaging (MRI) brain showed generalized atrophic changes in the cerebrum and cerebellum. Electroencephalogram performed during seizures revealed continuous run of spike-wave discharge seen in left frontal and central leads about 3-4 Hz in frequency (status epilepticus probably multifocal onset). Color Doppler was performed for the upper limb to find the reason for gangrene, but it was normal and there were no signs of an embolus. The patient was also screened for antinuclear antibodies to rule out any autoimmune cause of encephalitis, which was negative. Blood parameters and electrolytes were normal.

The patient did not respond to phenobarbital, sodium valproate, and diazepam. Later, she was ventilated and was on thiopentone infusion during which she was seizure free for a period of time.

However, on tapering the dose of thiopentone, she had intermittent seizures during touching, suctioning, and auditory stimulus. Later, the patient was put on tracheostomy and was referred to a higher center for further management including surgery for epilepsy.

DISCUSSION

Causality analysis using the World Health Organization scale is categorized as "possible" because the patient is a known case of seizure disorders, and hence, the disease could have an influence on the reaction.

Acute phenytoin intoxication may be due to intentional or accidental consumption of phenytoin. The patient may present with varied symptoms ranging from nausea vomiting to seizures and death. In this case, it was an intentional toxicity, and the patient has progressed to a refractory state of seizures. Plasma concentration of phenytoin has a correlation with the adverse effects.

Phenytoin is a weak acid and has erratic GI absorption. Peak blood levels occur 3-12 hrs. Phenytoin metabolism is dose-dependent, and its elimination follows first-order kinetics at the low drug concentrations and zero-order kinetics at higher drug concentrations [2]. This change in kinetics reflects the saturation of metabolic pathways. Thus, very small increments in dosage may result in adverse effects.

The cause was not known for gangrene of her fingers. Gangrene [3] and death [4] have been reported earlier for accidental intraarterial administration of phenytoin but not for oral administration present, MRI reveals cerebral atrophy. Although cerebral atrophy has been reported in chronic phenytoin ingestion [5], we cannot conclusively

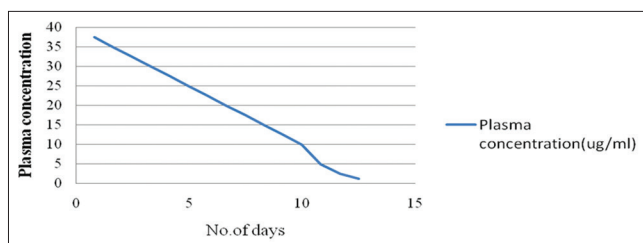


Fig. 1: A graph showing the elimination pattern assuming T_{1/2} as 20 hrs and 2.5 µg/ml eliminated per half-life under zero-order kinetics

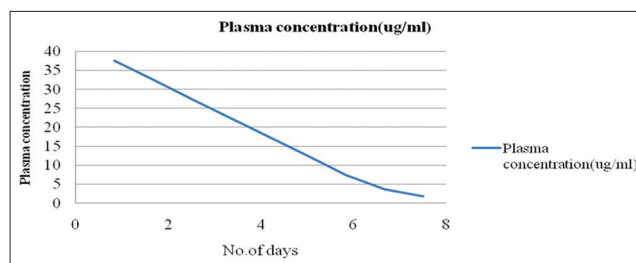


Fig. 3: A graph showing the elimination pattern assuming T_{1/2} as 20 hrs and 5 µg/ml eliminated per half-life under zero-order kinetics

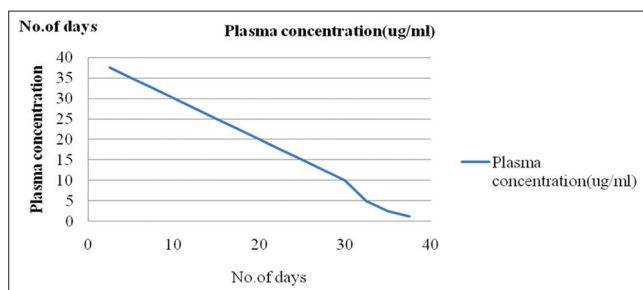


Fig. 2: A graph showing the elimination pattern assuming T_{1/2} as 60 hrs and 2.5 µg/ml eliminated per half-life under zero-order kinetics

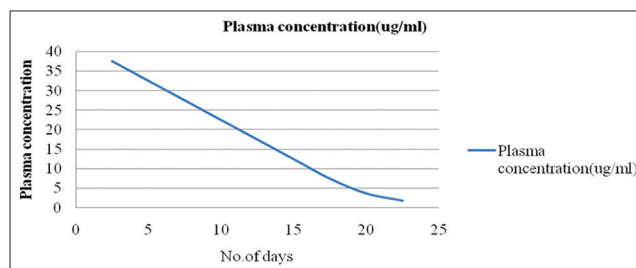


Fig. 4: A graph showing the elimination pattern assuming T_{1/2} as 60 hrs and 5 µg/ml eliminated per half-life under zero-order kinetics

prove that this is the reason for cerebral atrophy in this patient as we do not have neurological imaging taken at the initiation of the study. On the other hand, cerebral atrophy could be the reason for non-responsiveness to phenytoin as inactive cells would not respond to the drug.

Such a problem can be prevented in other patients by choosing a different antiepileptic in patients who have indications of cerebral atrophy in neurological imaging at the time of diagnosis of epilepsy.

Pharmacokinetics

In very large oral dosage, gastrointestinal absorption can be delayed even to several days [6,7]. We do not have the plasma concentration of phenytoin for this patient. Hence, roughly calculating the plasma concentration with the dose ingested by the patient (1500 mg).

Pt weight - 50 kg

Volume of distribution for phenytoin is 0.7 L/kg

For this patient 0.7*50=35 L

Assuming the drug is available 90% (i.e.,) F=0.9.

Known formula for calculating the dose is as follows:

$$\text{Dose} = \frac{\text{plasmaconcentration} * \text{volume of distribution}}{\text{Bioavailability}}$$

Rearranging

$$\text{Plasmaconcentration} = \frac{\text{Dose} * \text{Bioavailability}}{\text{Volume of distribution}}$$

By substituting,

Plasma concentration = 1500*0.9/35=37.5 mg/l or 37.5 µg/ml

T_{1/2} in therapeutic concentration is 12-36 hrs.

At higher concentrations, zero-order elimination occurs as a result of saturation of hydroxylation reaction, and apparent elimination half-life increases to 20-60 hrs [8,9].

From Fig 1,2,3,and 4 we infer that it takes 10,5,30 and 17 days respectively to reach therapeutic level of 10 micrograms per ml. Hence, from the above figures, we find that for the plasma concentration 37.5 µg/ml to reduce to the therapeutic level of 10-20 µg/ml it will take 5-30 days. Added to this as the patient had myoclonic seizures, she was started on valproate which displaces phenytoin, thereby increasing the free phenytoin concentration.

CONCLUSION

Seizures are a rare complication of phenytoin. Seizures can be prevented by evaluating therapeutic plasma concentration. In this case, the patient was on chronic treatment, and due to intentional toxicity, the patient progressed to a refractory state of seizures. This could have occurred because of the unique kinetic profile of phenytoin, small therapeutic index, and saturated the sodium channels. Another factor is the inter-patient variability of drug metabolism; certain individuals with a genetic predisposition are disposed to an increased level (slow metabolizers) [10].

ACKNOWLEDGMENT

ADR MONITORING CENTRE, Department of Pharmacology, PSG institute of medical science and research , Coimbatore 641004.

REFERENCES

1. Livanaien M, Savolainen H. Side effects of phenobarbital and phenytoin during long-term treatment of epilepsy. Acta Neurol Scand Suppl 1983;97:49-67.
2. Hussein A, Abdulgalil A, Omer F, Eltoum H, Hamad A, El-Adil O, et al. Correlation between serum level of antiepileptic drugs and their side effects. Oman Med J 2010;25(1):17-21.
3. Sintenie JB, Tuinebreijer WE, Kreis RW, Breederveld RS. Digital gangrene after accidental intra-arterial injection of phenytoin (epanutin). Eur J Surg 1992;158(5):315-6.
4. McLean CR, Cheng KS, Clifton MA. Fatal case of accidental intra-arterial phenytoin injection. Eur J Vasc Endovasc Surg 2002;23(4):378-9.

5. Chow KM, Szeto CC. Cerebral atrophy and skull thickening due to chronic phenytoin therapy. *CMAJ* 2007;176(3):321-3.
6. Chaikin P, Adir J. Unusual absorption profile of phenytoin in a massive overdose case. *J Clin Pharmacol* 1987;27(1):70-3.
7. Craig S. Phenytoin poisoning. *Neurocrit Care* 2005;3(2):161-70.
8. Chua HC, Venketasubramanian N, Tjia H, Chan SP. Elimination of phenytoin in toxic overdose. *Clin Neurol Neurosurg* 2000;102(1):6-8.
9. McNamara JO. Pharmacotherapy of epilepsies. In: Brunton LL, Lazo JS, Parker KL, editors. *Goodman and Gilman's The Pharmacological Basis of Therapeutics*. 11th ed. New York: McGraw-Hill; 2005. p. 501-25.
10. Koch-Weser J. The serum level approach to individualization of drug dosage. *Eur J Clin Pharmacol* 1975;9(1):1-8.