

HISTOMORPHOMETRY OF THE THYROID GLAND IN RAT AFTER LITHIUM ADMINISTRATIONDALVINDER SINGH^{1*}, MAHINDRA NAGAR², RAM PRAKASH²¹Department of Anatomy, Faculty of Dentistry, Jamia Millia Islamia, Delhi - 110 025, India. ²Department of Anatomy, University College of Medical Sciences & Guru Teg Bahadur Hospital, Delhi - 110 095, India. Email: dsingh@jmi.ac.in

Received: 30 September 2014, Revised and Accepted: 10 November 2014

ABSTRACT

Objectives: Lithium carbonate is being used for various psychiatric and non-psychiatric illness and has been recently observed to produce goiter and in some cases thyrotoxicosis. Most of these are based on clinical and laboratory observations. The present study was undertaken to observe the histomorphological changes in the thyroid gland after administration of lithium carbonate in rats.

Methods: Adult Wistar rats (150-250 g) were administered 40 mg/kg body weight/day lithium carbonate by intraperitoneal injection for 30 days. Controls were maintained. Fifteen hours after the last injection, the animals were sacrificed. Thyroids were removed and processed for routine histological studies.

Results: The size of the follicles was increased and showed an abundance of colloid. Statistically significant decrease in the epithelial cell size was also observed.

Conclusion: The present study is probably suggestive of development of hypothyroidism after chronic administration of lithium carbonate in albino rats. Hence, it is advised that patients on lithium therapy should be periodically evaluated for thyroid function.

Keywords: Thyroid gland, Lithium, Rat.

INTRODUCTION

The ancient Greeks as a treatment of "ill humor and excitement" reputedly used natural spring water containing lithium. But it was not until 1949 (Cade) [1] that an effect on mania was observed. In recent years, lithium carbonate is tremendously being used in various psychiatric disorders such as mania, depression, aggression, schizophrenia, alcoholism, prophylaxis of affective disorders as well as in non-psychiatric disorders i.e., pain, premenstrual tension, and leukopenia. Adverse effects such as nausea, diarrhea, and fine tremors - minor or transient are well-known. But in the last decade, conflicting observations of its effect on thyroid have been reported. Review of literature revealed a long-term treatment with lithium carbonate may produce goiter, with or without hypothyroidism or hypothyroidism without goiter [2-5]. It has also been found to cause thyrotoxicosis in some cases [6-8]. Most of these studies are based on clinical observations. Stimulated by these contradictory results, the present study is an attempt to study the histomorphometric features of the thyroid gland in rat after long-term lithium carbonate administration.

METHODS

The study was conducted in thirty adult inbred albino Wistar rats (150-250 g) of either sex. The animals were divided into three groups of ten animals each. They were housed in similar lighting conditions and fed on laboratory chow and water *ad libitum*. The animal procedures were performed in accordance with Guidelines for Ethical Conduct in the Care and Use of Animals. The experimental rats received 40 mg/kg body weight/day intraperitoneal injection of lithium carbonate in normal saline for 30 days. The controls received equal quantity of vehicle by the same route. Third group of animal was taken as normal. All animals were perfused fifteen hours after the last injection; thyroids removed and processed for routine paraffin sections. Histomorphometric studies were done by Abercrombie's method on every third haematoxylin and eosin stained section. The long and short diameters of follicles at right angles to each other, extending from the basement membrane of one side to the basement membrane of the other side passing through the center of the follicle, were measured.

In each follicle, the height and breadth of four epithelial cells present diagonally opposite to each other, with a clearly visible nucleolus were measured. The results were tabulated and statistically analyzed.

Observations

During the course of the experiment, it was observed that the lithium carbonate-treated rats were generally lethargic, and they developed polyuria from day 5 of the treatment. The thyroid gland was smooth surfaced and encapsulated as seen in control and experimental animals. Grossly no nodular enlargement or abnormal lobulation of the gland was observed. No significant difference was observed in mean thyroid weight between experimental and control group (Fig. 1).

Follicles, the functional unit of the thyroid gland, were embedded in stroma consisting collagen and reticular fibers with fusiform shaped fibroblasts, having an elongated darkly stained nucleus. The follicles were ovoid to spherical in shape. The mean long diameter observed was $77.77 \pm 12.50 \mu$ in normal animals, and $83.55 \pm 4.42 \mu$ in control animals. While in lithium carbonate treated rats, the mean long diameters of follicles were measured to be $94.39 \pm 29.99 \mu$. The mean short diameter was 73.37 ± 9.02 and $71.47 \pm 8.50 \mu$ in normal and control groups, respectively, whereas it was $96.85 \pm 6.34 \mu$ in lithium carbonate treated group. There was a significant increase in the size of the follicles in the experimental group (Table 1). The follicular colloid showed no vacuolation, and the amount of colloid appeared to have increased and reached the luminal surface of the lining cells. The stroma was found to be thinned out with no change in the vascularity of the gland in the experimental animals (Fig. 2).

The follicles in normal and control groups were found to be lined by simple cuboidal epithelium measuring $7.62 \pm 0.17 \mu \times 6.46 \pm 0.13 \mu$ and $7.51 \pm 0.21 \mu \times 6.48 \pm 0.16 \mu$ in both groups, respectively (Fig. 3). In experimental group, a large number of follicles were found to be lined with low cuboidal epithelium measuring $6.23 \pm 0.16 \mu \times 5.94 \pm 0.27 \mu$. A statistically significant decrease in the height and breadth of the follicular lining cells in the experimental group was observed as compared to normal and control groups (Table 1).

Table 1: Comparison of the groups for parameters of epithelial cells and follicle

Group	Epithelial cell mean±SD in micron (μ)		p-value (one-way ANOVA)	Significance (Turkey test at 5% level)	Follicle mean±SD in microns (μ)		p-value (one-way ANOVA)	Significance (Turkey test at 5% level)
	Height	Breadth			Long diameter	Short diameter		
Normal	7.62±0.17	6.46±0.13	0.000	Experimental group is significantly different from normal and control groups	77.77±12.50	73.37±9.02	0.000	Experimental group is significantly different from normal and control groups
Control	7.51±0.21	6.48±0.16			83.55±4.42	71.47±8.50		
Experimental	6.23±0.16	5.94±0.27			94.39±29.99	96.85±6.34		

SD: Standard deviation

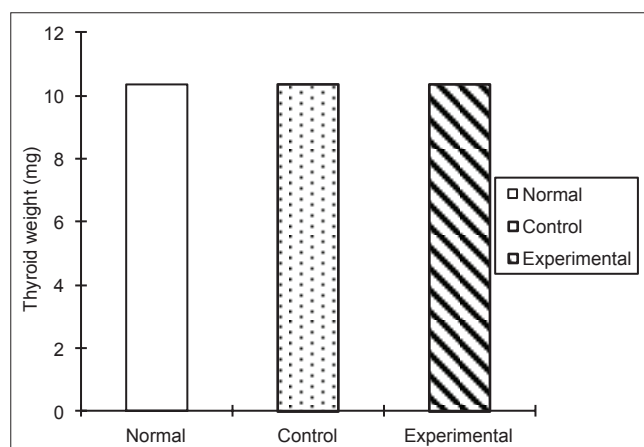


Fig. 1: Comparison of mean thyroid weight (mg) in normal, control, and experimental group

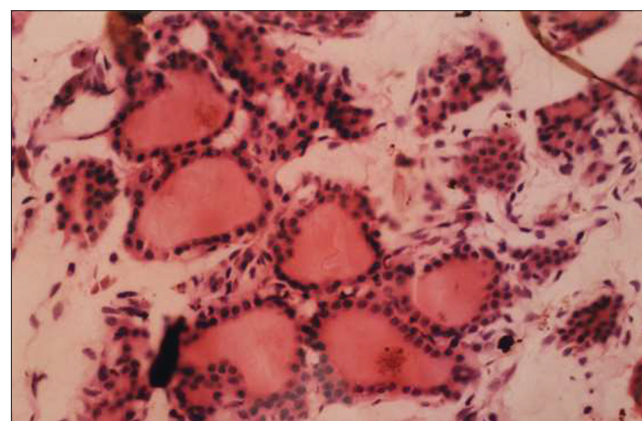


Fig. 3: Photomicrograph of a transverse section of the thyroid gland in a rat of control Group (H and E, ×400)

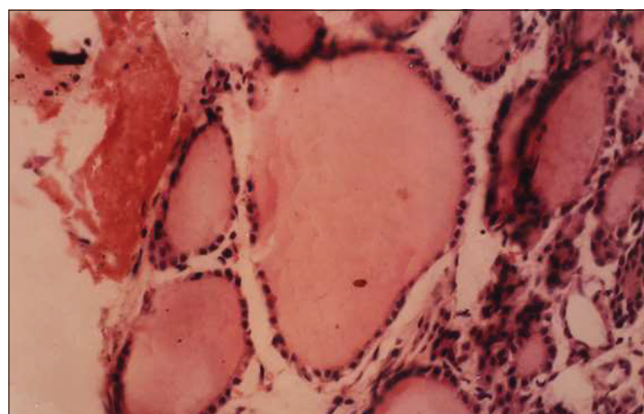


Fig. 2: Photomicrograph of a transverse section of the thyroid gland in an experimental rat showing enlarged follicles lined with flattened epithelial cells (H and E, × 400)

DISCUSSION

Lithium was given in the form of carbonate salt as recommended for lithium therapy. The pharmacological properties, of lithium salts, are attached solely to the lithium ions and being a metallic ion it is neither catabolized nor is it protein bound. Its distribution volume approximates concentration volume to the body water volume but concentration in the thyroid is several folds higher than the plasma concentration [9,10]. Polyuria, which was apparent from day 5 in lithium-treated rats, is in accordance with Schreiber *et al.* (1971) and Chatterjee *et al.* (1990) [11,4] who also used "rat" as an experimental model, to observe endocrine changes following chronic lithium treatment. This has been attributed due to a reduction in the renal concentrating ability [12]. In fact, Jacobsen *et al.* (1982) [13] have demonstrated a morphological alteration in the collecting tubules of the kidney accompanying early functional alteration, polyuria. These

findings are supported by observations of Hestbech *et al.* (1977) [14] who observed that high renal concentration of lithium resulted in various chronic renal lesions.

The thyroid did not show any gross enlargement in its size in the experimental and the control animals. Schreiber *et al.* (1971) [11], Mizukami *et al.* (1995) [8], Aydin *et al.* (1996) [2] observed an increase in the weight of the thyroid gland in lithium-treated rats, which may be due to the difference in the doses used. The observations of the present study are favorably comparable to the observations of Dhawan *et al.* (1985) [16] who reported no statistically significant difference in the thyroid weight after chronic administration of lithium carbonate in Wistar rat.

The thyroid is unique in having a histological organization that provides for an extracellular storage of its product in the lumen of cyst-like follicles. In the present work, similar follicles were seen with a very little stroma in between them. In the thyroid gland of experimental rats sacrificed after the 30 day of lithium carbonate injection, a large number of follicles were found to have increased dimensions in comparison to the normal and control groups. The follicular colloid showed no vacuolation, and the amount of colloid appeared to have increased and reached almost to the luminal surface of the lining cells. This was similar to the findings of Schreiber *et al.* (1971) [11], Chatterjee *et al.* [4], Mizukami *et al.* (1995) [8]. Lithium probably behaves like iodine and gets accumulated in the thyroid gland [17]. According to Transbøl *et al.* (1978) [18], lithium inhibits organic iodine binding and thyroid hormone release, as a result of which functional and morphological alterations in the thyroid are observed.

The follicles in the rats were found to be lined by simple cuboidal epithelial cells with basal nucleus. There was a statistically significant decrease in the height and breadth of the follicular lining cells in the experimental group. Earlier workers like Schreiber *et al.* (1971), Chatterjee *et al.* (1990) [11,4] also observed a reduction in the epithelial cell size after chronic lithium treatment.

It is speculated that abundance of colloid in the intrafollicular space coexisting with reduction in the epithelial height is suggestive of decreased utilization of stored hormones and consequently inactivity of the gland, probably an indication of hypothyroidism. This view is supported by Dhawan *et al.* (1985) [16], who observed a decrease of circulating levels of thyroxine and triiodothyronine in rat subjected to chronic lithium treatment. Candy (1972), Shopsin *et al.* (1973), Brownlie *et al.* (1976), Lindstedt *et al.* (1977) [19-22] also observed hypothyroidism on estimation of serum thyroxine and triiodothyronine, after chronic treatment with lithium carbonate, in patients suffering from manic depressive disorders.

CONCLUSION

The present study is probably suggestive of development of hypothyroidism after chronic administration of lithium carbonate in albino rats. This study, therefore, emphasizes the careful use of lithium carbonate. In addition, it is advised that patients on lithium therapy should be periodically evaluated for thyroid function.

REFERENCES

1. Cade JF. Lithium salts in the treatment of psychotic excitement. *Med J Aust* 1949;2(10):349-52.
2. Aydin I, Aslan I, Bahceci M, Aydin M. Morphologic and functional alterations of the thyroid gland in rabbits treated with lithium. *Horm Metab Res* 1996;28(7):323-5.
3. Bschor T, Bauer M. Thyroid gland function in lithium treatment. *Nervenarzt* 1998;69(3):189-95.
4. Chatterjee S, Roden K, Banerji TK. Morphological changes in some endocrine organs in rats following chronic lithium treatment. *Anat Anz* 1990;170(1):31-7.
5. Yassa R, Saunders A, Nastase C, Camille Y. Lithium-induced thyroid disorders: A prevalence study. *J Clin Psychiatry* 1988;49(1):14-6.
6. Todd J, Jerram TC. Thyrotoxicosis during lithium treatment. *Br J Clin Pract* 1978;32(7):201-3.
7. Kontozoglou T, Mambo N. The histopathologic features of lithium-associated thyroiditis. *Hum Pathol* 1983;14(8):737-9.
8. Mizukami Y, Michigishi T, Nonomura A, Nakamura S, Noguchi M, Takazakura E. Histological features of the thyroid gland in a patient with lithium induced thyrotoxicosis. *J Clin Pathol* 1995;48:582-4.
9. Shou M. Biology and pharmacology of the lithium ion. *Pharmacol Rev* 1957;9:17-58.
10. Corbett CE. Uso de litio. In: Koogan G, editor. *Farmacodinamica*. 7th ed. Rio de Janeiro, RJ: 1982. p. 23.
11. Schreiber V, Roháčová J, Pribyl T. Endocrine changes after chronic lithium carbonate administration in rats. *Physiol Bohemoslov* 1971;20(3):249-54.
12. Hansen HE, Pedersen EB, Amdisen A. Renal function and plasma aldosterone during acute lithium intoxication. *Acta Med Scand* 1979;205(7):593-7.
13. Jacobsen NO, Olesen OV, Thomsen K, Ottosen PD, Olsen S. Early changes in renal distal convoluted tubules and collecting ducts of lithium-treated rats: Light microscopy, enzyme histochemistry, and 3H-thymidine autoradiography. *Lab Invest* 1982;46(3):298-305.
14. Hestbech J, Hansen HE, Amdisen A, Olsen S. Chronic renal lesions following long-term treatment with lithium. *Kidney Int* 1977;12(3):205-13.
15. Heltné CE, Ollerich DA. Morphometric and electron microscopic studies of goiter induced by lithium in the rat. *Am J Anat* 1973;136(3):297-303.
16. Dhawan D, Sharma R, Sharma RR, Dash RJ. Serum thyroxine and triiodothyronine concentrations in rats receiving lithium carbonate. *Horm Metab Res* 1985;17(2):109-10.
17. Berens SC, Wolff J, Murphy DL. Lithium concentration by the thyroid. *Endocrinology* 1970;87(5):1085-7.
18. Transbøl I, Christiansen C, Baastrup PC. Endocrine effects of lithium. I. Hypothyroidism, its prevalence in long-term treated patients. *Acta Endocrinol (Copenh)* 1978;87(4):759-67.
19. Candy J. Severe hypothyroidism – An early complication of lithium therapy. *Br Med J* 1972;3(5821):277.
20. Shopsin B, Shenkman L, Blum M, Hollander CS. Iodine and lithium-induced hypothyroidism. Documentation of synergism. *Am J Med* 1973;55(5):695-9.
21. Brownlie BE, Chambers ST, Sadler WA, Donald RA. Lithium associated thyroid disease – A report of 14 cases of hypothyroidism and 4 cases of thyrotoxicosis. *Aust N Z J Med* 1976;6(3):223-9.
22. Lindstedt G, Nilsson LA, Wälinder J, Skott A, Ohman R. On the prevalence, diagnosis and management of lithium-induced hypothyroidism in psychiatric patients. *Br J Psychiatry* 1977;130:452-8.