

## EVALUATION OF HEPATOPROTECTIVE AND ANTIOXIDANT ACTIVITY OF *AVICENNIA ALBA* (BLUME) ON PARACETAMOL-INDUCED HEPATOTOXICITY IN RATS

DINESH KUMAR G<sup>1\*</sup>, JAYASEELAN T<sup>1</sup>, SENTHIL J<sup>2</sup>, MANI P<sup>3</sup>

<sup>1</sup>Department of Zoology and Biotechnology, A.V.V.M. Sri Pushpam College, Thanjavur, Tamil Nadu, India. <sup>2</sup>Department of Medicinal Plant Biotechnology, Sharmila Institute of Medicinal Products Research Academy, Thanjavur, Tamil Nadu, India. <sup>3</sup>Department of Biotechnology, Annai College of Arts and Science, Kumbakonam, Tamil Nadu, India. Email: dineshkumar:june28@gmail.com

Received: 19 May 2016, Revised and Accepted: 23 May 2016

### ABSTRACT

**Objective:** To study the hepatoprotective activity of ethanolic extracts of *Avicennia alba* leaves against paracetamol-induced liver damage in rats.

**Methods:** Hepatotoxicity was induced by paracetamol, and the biochemical parameters such as serum aspartate aminotransferase (AST), alkaline phosphatase (ALP), alanine aminotransferase (ALT), and total bilirubin (serum bilirubin); and the antioxidant such as superoxide dismutase, catalase, glutathione (GSH) peroxidase, GSH, vitamin C and E, and thiobarbituric acid reactive substances were recorded, and histopathological changes in liver were studied along with silymarin as standard hepatoprotective agents.

**Results:** The phytochemical investigation of the extracts showed the presence of alkaloids, flavonoids, tannins, terpenoids, proteins, and steroids. Treatment with herbal extract to paracetamol administered rats caused a significant reduction in the values of AST, ALP, ALT, and total bilirubin ( $p < 0.05$ ) almost comparable to silymarin. The hepatoprotective was confirmed by histopathological examination of the liver tissue of control and treated animals.

**Conclusion:** From the results, it can be concluded that *A. alba* leaves possess hepatoprotective effect against paracetamol-induced liver damage in rats.

**Keywords:** Liver, *Avicennia alba*, Hepatoprotective and antioxidant activities.

### INTRODUCTION

Liver is an essential organ regulating significant metabolic functions and homeostasis within the body. Liver damage caused by toxic drugs and certain chemicals have been recognized as a toxicological problem [1]. Hepatotoxicity is one of the very general ailments resulting into serious debilities ranging from severe metabolic disorders to even mortality. A number of drugs and chemical agents that are used on a usual basis cause cellular as well as metabolic liver injury [2].

Paracetamol is universally used as an antipyretic and analgesic. It is considered as safe in its therapeutic doses, but overdose toxicity of paracetamol causes poisonings that lead to liver damage. It exerts hepatotoxic effects in a dose-dependent manner [3,4]. *Avicennia alba* (Blume) of the family Avicenniaceae is a mangrove tree growing at the river mouth in the tidal forests, widely distributed all over the tropical and subtropical regions of the world. It is an evergreen bush or small tree that can grow up to 30 m tall but is typically much smaller. It is used in Indian system of medicine for the treatment of numerous diseases such as asthma, scabies, paralysis, rheumatism, and snake-bites, skin disease, and ulcer [5]. Present day drugs, which are mainly based on synthetic chemical compounds, have harmful side effects and toxicity on the human system. This has triggered off broad research and development in the ground of herbal medicine. In fact, there is a growing demand for herbal medicine in most of the developed and developing countries of the world today [6]. Herbs play a major role in managing various liver disorders along with other system associated diseases. The use of natural remedies for the treatment of liver diseases has a long history and herbal plants, and their derivatives are still used all over the world in one form or the other for this purpose. Scientific assessment of plants has often shown that dynamic principles in these are responsible for therapeutic success. A huge number of therapeutic medicinal plants have been tested and found to contain active principles with curative properties against a variety of diseases. Hence, the present

study is carried out to evaluate the hepatoprotective and antioxidant activity of the medicinal plant, *A. alba* (Blume) on paracetamol-induced hepatotoxicity in rats.

### METHODS

#### Collection, identification, and authentication of selected plant

Fresh, healthy, and young leaves of *A. alba* were collected from Muthupet, Thiruvavur district, Tamil Nadu, India, and authenticated by professionals in the Department of Botany, St. Joseph's College, Tiruchirappalli, India. The voucher specimen number of the plant is TRK 001.

#### Preparation of plant extracts

The leaves were cleaned and dried in shade for 7 days and then ground well to fine powder. About 500 g of dry powder was extracted with ethanol (80%) at 70°C by continuous hot percolation using Soxhlet apparatus. The extraction was continued for 24 hrs, and the ethanolic extract was then filtered and kept in hot air oven at 40°C for 24 hrs to evaporate the ethanol from it. A dark brown residue was obtained. The residue was kept separately in airtight containers and stored in a deep freezer.

#### Phytochemical analysis tests

Phytochemical analysis of ethanolic extract of *A. alba* leaves for secondary metabolites such as alkaloids, flavonoids, carbohydrates, proteins, phenols, saponins, tannins, terpenoids, phytosterols, and phlobatannins was done using standard methods [7].

#### Animals

Healthy, matured male albino Wistar rats weighing 170-210 g were used for the present study. They were kept in plastic animal cages at animal house maintained at standard temperature and humidity with 12 hrs light and dark cycle. The animals were fed with standard pellet

diet and water. The animals are handled according to good laboratory practice. After 1 week of acclimatization, the animals were used for further research experiments. The ethical clearance was obtained from the Institutional Animal Ethical Committee as per the Indian CPCSEA guidelines (CPCSEA/265).

#### Groupings and experimental design

The animals were divided into four groups. Each group contains six animals.

Group I: Normal control (n=6, the animals were given distilled water only).

Group II: Hepatotoxic control (n=6, the animals were given paracetamol [2 g/kg po] single dose for 7 days).

Group III: Treatment group (n=6, the animals were given paracetamol [2 g/kg po] single dose and *A. alba* extract (500 mg/kg po) simultaneously for 7 days).

Group IV: Treatment group (n=6, the animals were given paracetamol [2 g/kg po] single dose and silymarin [100 mg/kg po] simultaneously for 7 days).

At the end of the drug treatment period, all the animals were anesthetized by application of light chloroform, and blood samples were collected from a group of animals from dorsal aorta by heparinized syringe in vacutainer tubes. Plasma was separated from the collected blood by centrifugation of 3000 rpm for 5 minutes. Separate blood samples were collected from another group of anesthetized animals in glass test tubes and allowed to coagulate for 30 minutes. Serum was separated by centrifugation at 3000 rpm for 2 minutes. Plasma and serum samples were kept at -20°C for biochemical analysis.

Finally, the animals were sacrificed by cervical decapitation. The perfused liver of each animal was dissected out and washed with isotonic solution and then homogenized to get 11% solution of tissue homogenate in Tris-HCl buffer (10 mm, pH 8.0). This homogenate was used for the determination of various parameters.

#### Acute toxicity study

The acute toxicity study was carried out as per the guidelines set by OECD-423, received from Committee for the Purpose of Control and Supervision of Experiments on Animals, Ministry of Social Justice and Empowerment, Government of India [8]. The ethanolic extract was orally administered to adult Wistar albino rats. The groups were continuously observed for mortality and behavioral changes during the first 24 hrs and then daily for a fortnight. The oral lethal dose, 50% was found to be more than 3000 mg/kg.

#### Evaluation of antioxidants

The enzymatic antioxidants such as superoxide dismutase (SOD), catalase (CAT), and glutathione (GSH) peroxidase (GPx) [9-11] and the non-enzymatic antioxidants such as GSH, vitamin E, vitamin C, and thiobarbituric acid reactive substances (TBARS) [12-15] are evaluated.

#### Evaluation of effect on biochemical variables

The clear serum obtained after centrifugation was used for the estimation of serum alanine aminotransferase (ALT), aspartate aminotransferase (AST), alkaline phosphatase (ALP), and total serum bilirubin (SB) [16-18].

#### Histopathological studies

The abdomen of the sacrificed animals was cut open to remove the liver. The volume (LV), weight (LW), and appearance of the liver was observed. The normal saline was used to wash the liver and fixed in Bouin's solution (mixture of 25 ml of 40% formaldehyde, 75 ml of saturated picric acid, and 5 ml of glacial acetic acid) for 12 hrs, then embedded in paraffin using conventional methods and cut into 5 µm thick sections and stained using hematoxylin-eosin dye and finally mounted in diphenylxylene. The compound microscope was used to observe the histopathological changes in liver architecture and their microphotographs were taken [19].

#### Statistical analysis

The data were statistically analyzed, and all values were expressed as mean±standard error of mean. The data were also analyzed by one-way ANOVA using SPSS software. p<0.05 was considered significant.

### RESULTS

#### Qualitative phytochemical analysis

The qualitative phytochemical analysis of ethanolic extracts of *A. alba* leaves revealed the presence of alkaloids, flavonoids, steroids, cardiac glycosides, anthraquinones, tannins, and terpenoids (Table 1).

#### Enzymatic antioxidant activities

##### SOD

Table 2 shows a significant decrease in the activity of liver SOD in paracetamol intoxicated rat. The therapeutic treatment with *A. alba* 500 mg/kg significantly improved the level of SOD in plasma. This result indicates that *A. alba* promoted the hepatoprotection by elevating free radical scavenging activity. Similar results were also observed in silymarin treated rats.

##### CAT

Table 2 shows the inhibition (decrease) of CAT activity in paracetamol-induced rats due to the improved generation of reactive free radicals, which can create an oxidative stress in the cells. The administration of *A. alba* 500 mg/kg dose inversed the CAT activity in the blood plasma, which protected rats from the free radical-induced oxidative stress. This results support that the antioxidant properties of the *A. alba* were excellent as compared with the standard drug silymarin.

##### GPx

Table 2 reveals the decrease in levels of GPx activity in plasma during paracetamol intoxication. Treatment with *A. alba* significant dose 500 mg/kg significantly increased the level GPx to normal level. The significant effect of *A. alba* extract is equivalent to standard drug silymarin showed increase in the GPx level in the paracetamol intoxicated rats.

#### Non-enzymatic antioxidant activities

##### GSH

Acetaldehyde, the toxic metabolite of paracetamol depresses the plasma GSH level by conjugating with the sulphhydryl groups of GSH. The GSH depletion in hepatic mitochondria is considered the most important sensitizing mechanism in the pathogenesis of paracetamol liver injury. Treatment with *A. alba* 500 mg/kg dose had significantly improved the level of GSH in plasma (Table 3).

##### Vitamin C and E

Table 3 shows the decreased level of these vitamins in paracetamol intoxicated rats. This may be due to the high level of oxidative stress during the intoxication. The reduced form of GSH substrate (GSH) is required for the regeneration of vitamin C, which in turn necessary for the regeneration of vitamin E. The ascorbic acid functions as an aqueous phase antioxidant. Treatment with *A. alba* 500 mg/kg dose on

Table 1: Qualitative phytochemical analysis

S.No	Phytochemicals	Appearance	Results
1.	Alkaloids	Pale precipitate	+
2.	Flavonoids	Dirty brown color	+
3.	Cardiac glycosides	Brown ring formation	+
4.	Steroids	Violet to blue color	+
5.	Terpenoids	Reddish brown color	+
6.	Tannins	Yellow precipitate	+
7.	Anthraquinones	Red color	+
8.	Saponins	Absence of honeycomb like froth	-

paracetamol intoxicated rats significantly increased the level of vitamin E and C through the influence of GSH regeneration. Thus, the herbal compound exerts a beneficial effect in regenerating the GSH through the recycling mechanism of these vitamins. The herbal extract has a potent effect in GSH regeneration similar to standard drug silymarin.

#### TBARS

Table 3 shows the levels of TBARS in liver tissues of paracetamol intoxicated rats were significantly elevated when compared to the level of TBARS in control animals. The administration of herbal drug *A. alba* at the therapeutic doses 500 mg/kg showed maximum reduction in TBARS level. The standard hepatoprotective drug silymarin maintained the decreased lipid peroxidation level to the normal limits in the serum. The results indicate that *A. alba* has very good hepatoprotective effect in liver damage.

#### Liver marker enzymes

Table 4 shows the serum levels of AST, ALP, ALT, and total bilirubin, which have been used as biochemical markers for the early acute hepatic damages. Increased activities of AST, ALP, ALT, and total bilirubin in liver serum after paracetamol intoxication compared with those of normal rat indicate hepatocellular damage and leakage of cytosolic contents into the systemic circulation. Moreover, the elevated levels of serum AST, ALP, ALT, and total bilirubin were significantly reduced ( $p < 0.05$ ) in the groups treated with *A. alba* (at a dose of 500 mg/kg). The results demonstrated that the administration of *A. alba* could decrease the levels of AST, ALP, ALT, and total bilirubin in serums of paracetamol treated rat liver. Silymarin also reduced all measured serum biochemical activities toward normalization.

#### Histopathological studies

In histopathological studies, the normal control group showed a normal lobular architecture of the liver. Whereas, in the paracetamol-induced group, the hepatocytic necrosis and inflammation were observed in the centrilobular region with portal triaditis. The *A. alba* treated group showed minimal inflammation with reasonable portal triaditis and

normal lobular architecture. Silymarin treated group showed normal hepatocytes and their lobular architecture was also normal (Fig. 1).

#### DISCUSSION

The liver complication is still a universal health problem. Unfortunately, conventional or synthetic drugs used in the healing of liver disease are scanty and sometimes can have serious side effect. It has been reported earlier that when paracetamol is taken in excess of dose, it produce hepatic necrosis and liver injury. Due to the absence of modern medicine for liver protection, there are a number of medicinal preparations in Ayurveda recommended for the treatment of liver problems. Nowadays, the focus is on systematic scientific research methodology and to evaluate the traditional herbal medicines to overcome the severe adverse side effects of synthetic agents that are claimed to possess hepatoprotective activity [20]. Liver marker enzymes such as

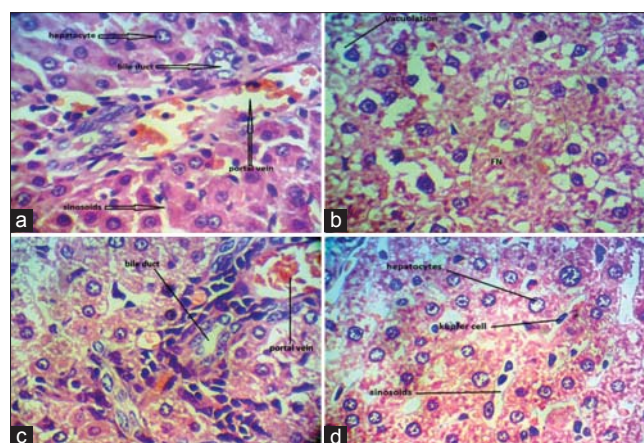


Fig. 1: Histopathological studies, (a) control, (b) paracetamol-induced group, (c) paracetamol + *Avicennia alba* 500 mg/kg extract, (d) paracetamol + silymarin 100 mg/kg po

Table 2: Effect of *A. alba* on enzymatic antioxidants of control and experimental rats against paracetamol-induced toxicity

Group	Treatment	SOD (U/mg protein)	CAT (U/mg protein)	GPx (U/mg protein)
Group I	Control	46.8±3.5	18.1±1.9	75.6±5.2
Group II	Paracetamol 2 g/kg (po)	19.3±2.1	9.7±1.4	36.2±6.2
Group III	Paracetamol+ <i>A. alba</i> 500 mg/kg	42±3.6**	16.5±0.82**	70.01±5.4**
Group IV	Paracetamol+Silymarin 100 mg/kg	44.12±3.12***	17.01±0.12***	73.12±4.12***

Values are given as mean±SEM (n=6 rats). \* $p < 0.05$  versus control, \*\* $p < 0.005$  versus control. SEM: Standard error of mean, *A. alba*: *Avicennia alba*, SOD: Superoxide dismutase, CAT: Catalase, GPx: Glutathione peroxidase

Table 3: Effect of *A. alba* on non-enzymatic antioxidants of control and experimental rats against paracetamol-induced toxicity

Group	Treatment	GSH (Lmol/g)	Vitamin E (mg/g)	Vitamin C (mg/g)	TBARS (nmol/mg protein×10 <sup>-6</sup> )
Group I	Control	35.4±1.4	4.13±0.21	1.57±0.03	123±1.12
Group II	Paracetamol 2 g/kg (po)	18.4±0.9	2.22±0.14	0.62±0.02	308±1.23
Group III	Paracetamol+ <i>A. alba</i> 500 mg/kg	33.0±2.1**	3.77±0.15**	1.38±0.07**	176±1.47**
Group IV	Paracetamol+Silymarin 100 mg/kg	34.18±2.4***	3.99±0.15***	1.44±0.04***	87±1.39***

Values are given as mean±SEM (n=6 rats). \* $p < 0.05$  versus control, \*\* $p < 0.005$  versus control. SEM: Standard error of mean, *A. alba*: *Avicennia alba*, GSH: Glutathione, TBARS: Thiobarbituric acid reactive substances

Table 4: Effect of *A. alba* on liver function marker enzymes of control and experimental rats against paracetamol-induced toxicity

Group	Treatment	AST (IU/L)	ALT (IU/L)	ALP (IU/L)	SB (mg/dL)
Group I	Control	138±18	64±11	201±58	0.05±0.03
Group II	Paracetamol 2 g/kg (po)	576±193	747±201	344±93	0.23±0.09
Group III	Paracetamol+ <i>A. alba</i> 500 mg/kg	201±114**	160±121**	195±31***	0.05±0.05*
Group IV	Paracetamol+Silymarin 100 mg/kg	190±55***	151±116***	202±24**	0.05±0.05*

Values are given as mean±SEM (n=6 rats). \* $p < 0.05$  versus control, \*\* $p < 0.005$  versus control. SEM: Standard error of mean, *A. alba*: *Avicennia alba*, AST: Aspartate aminotransferase, ALP: Alkaline phosphatase, ALT: Alanine aminotransferase, SB: Serum bilirubin



ALT, AST, ALP, and bilirubin are considered to be very sensitive and reliable for measuring hepatotoxicity as well as hepatoprotective effect of various compounds. Hepatic necrosis induced by ibuprofen usually associated with elevated levels of liver marker enzymes is due to the loss of functional integrity of the cell membrane and cellular leakage in liver [21]. Assessment of liver function can be made by estimating the actions of serum ALT, AST, ALP, and ACP, which are enzymes originally present at more concentration in the cytoplasm. These enzymes leak into the bloodstream during hepatopathy, which confirms the extent of liver damage [22]. In this present investigation, the level of these enzymes are elevated in the group II, paracetamol treated rats corresponded to the wide-ranging liver damage induced by the toxin. The reduced concentrations of ALT, AST, and ALP were observed in the group administered with ethanolic leaves extract of *A. alba* remarkably prevented paracetamol-induced hepatotoxicity and control the level of marker enzymes.

SB is one of the best sensitive tests for the diagnosis of hepatic diseases. Hyperbilirubinemia was observed due to excessive heme destruction and obstruction of the biliary tract. As a result of blockage of the biliary tract, there is a strong inhibition of the conjugation reaction. This leads to the release of non-conjugated bilirubin from damaged and dead hepatocytes [23]. In the present study, the oral administration of ethanolic leaves extract of *A. alba* treated groups shows decreased level of bilirubin when compared to paracetamol-induced rats. Hence, this study reveals that leaves of *A. alba* have a potent hepatoprotective activity. The enzymatic antioxidant is the nature protector against lipid peroxidation. SOD, CAT, and GPx enzymes are important scavengers of hydrogen peroxide and superoxide ion. These enzymes prevent generation of hydroxyl radical and protect the cellular constituents from oxidative damage [24]. It was also observed that the ethanolic leaves extract of *A. alba* significantly increased the hepatic SOD, CAT, and GPx activity in paracetamol-induced liver damage in rats. This show *A. alba* can reduce reactive free radicals that might lessen oxidative damage to the tissues and improve the activities of the hepatic antioxidant enzyme.

The non-enzymatic antioxidant, GSH is one of the most abundant tripeptides present in the liver. Its functions are mainly concerned with the removal of free radical species such as hydrogen peroxide, superoxide radicals, alkoxy radicals, and maintenance of membrane protein thiols and as a substrate for GPx and GST [25]. In the present investigation, the decreased level of vitamin C, vitamin E, and GSH has been associated with an enhanced lipid peroxidation in paracetamol-treated rats. Administration of *A. alba* leaves extracts significantly increased the level of vitamin C, vitamin E, and GSH in a dose-dependent manner when compared to normal drug silymarin. The histopathological observations in paracetamol-induced rats showed severe necrosis, with the disappearance of nuclei. This could be due to the formation of highly reactive radicals because of oxidative threat caused by paracetamol. All these changes were very much reduced histopathologically in rats treated with *A. alba*.

## CONCLUSION

The study results demonstrated that *A. alba* has a potent hepatoprotective action on paracetamol-induced oxidative stress and liver toxicity in the rat. The hepatoprotective effect of *A. alba* can be correlated directly with its ability to reduce levels of serum enzymes and enhance antioxidant defiance status. The findings of this study suggest that *A. alba* can be used as a safe, cheap, effective alternative chemopreventive and a protective agent in the management of liver diseases.

## ACKNOWLEDGMENT

The authors are very grateful to the Secretary, Correspondent and the Principal of A.V.V.M. Sri Pushpam College (Autonomous), Poondi - 613 503, Thanjavur (Dt.) and also thankful to Mr. R. J. Antony Raj, the Chairman, SIMPRA Research Institute for providing the excellent

infrastructure and necessary facilities. We are also very grateful to University Grants Commission (UGC), Government of India, New Delhi, for providing financial assistance in the form of Rajiv Gandhi National Fellowship, which buttressed me to perform my work comfortably.

## REFERENCES

1. Patel RK, Patel MM, Patel MP, Kanzaria NR, Vaghela KR, Patel NJ. Hepatoprotective activity of *Moringa oleifera* Lam. Fruit on isolated rat hepatocytes. *Phcog Mag* 2008;4:118-23.
2. Meyer SA, Kulkarni AP. Hepatotoxicity. In: Introduction to Biochemical Toxicology. 3<sup>rd</sup> ed. New York: John Wiley and Sons; 2001. p. 487-90.
3. Kelava T, Cavar I, Culo F. Influence of small doses of various drug vehicles on acetaminophen-induced liver injury. *Can J Physiol Pharmacol* 2010;88(10):960-7.
4. El-Agamy DS, Makled MN, Gamil NM. Protective effects of BML-111 against acetaminophen-induced acute liver injury in mice. *J Physiol Biochem* 2014;70(1):141-9.
5. Field C. Journey among Mangroves. Okinawa, Japan: International Society for Mangrove Ecosystems; 1995. p. 70.
6. Handa SS, Sharma A, Chakarborty KK. Natural Products and plants as liver protecting drugs. *Fitoterapia* 1986;57(5):307-52.
7. Harborne JB. *Phytochemical Methods*. London: Chapman and Hall Ltd.; 1973. p. 49-188.
8. Organisation for Economic Co-operation and Development. OECD guideline for testing of chemicals. Acute oral toxicity-acute toxic class method. OECD Guidelines for the Testing of Chemicals. Health effects 2010; 1(4): 1-14.
9. Kakkar P, Das B, Viswanathan PN. A modified spectrophotometric assay of superoxide dismutase. *Indian J Biochem Biophys* 1984;21(2):130-2.
10. Sinha AK. Colorimetric assay of catalase. *Anal Biochem* 1972;47(2):389-94.
11. Rotruck JT, Pope AL, Ganther HE, Swanson AB, Hafeman DG, Hoekstra WG. Selenium: Biochemical role as a component of glutathione peroxidase. *Science* 1973;179(4073):588-90.
12. Ellman GL. Tissue sulfhydryl groups. *Arch Biochem Biophys* 1959;82(1):70-7.
13. Omaye ST, Turnbull JD, Sauberlich HE. Selected methods for the determination of ascorbic acid in animal cells, tissues, and fluids. *Methods Enzymol* 1979;62:3-11.
14. Baker H, Frankel O, De Angelis B, Feingold S. Plasma  $\alpha$ -tocopherol in man at various time intervals after ingesting free or acetylated tocopherol. *Nutr Rep Int* 1980;21:531-6.
15. Niehaus WG Jr, Samuelsson B. Formation of malonaldehyde from phospholipid arachidonate during microsomal lipid peroxidation. *Eur J Biochem* 1968;6(1):126-30.
16. Reitman S, Frankel S. A colorimetric method for the determination of serum glutamic oxalacetic and glutamic pyruvic transaminases. *Am J Clin Pathol* 1957;28(1):56-63.
17. King EJ, Armstrong AR. A convenient method for determining serum and bile phosphatase activity. *Can Med Assoc J* 1934;31(4):56-63.
18. Malloy HT, Evelyn EA. The determination of bilirubin with photoelectric calorimeter. *J Biol Chem* 1937;119:481-5.
19. Galighor AE, Kozloff EN. *Essential of Practical Micro Technique*. New York: Lea & Febiger; 1976. p. 210.
20. Chatterjee TK. Medicinal plants with hepatoprotective properties. In: *Herbal Options*. 3<sup>rd</sup> ed. Calcutta: Calcutta Books & Allied (P) Ltd.; 2000. p. 135.
21. Shah M. Evaluation of the effect of aqueous extract from powders of root, stem, leaves and whole plant of *Phyllanthus debilis* against CCl<sub>4</sub> induced rat liver dysfunction. *Indian Drugs* 2002;39:333-7.
22. Nkosi CZ, Opoku AR, Terblanche SE. Effect of pumpkin seed (*Cucurbita pepo*) protein isolate on the activity levels of certain plasma enzymes in CCl<sub>4</sub>-induced liver injury in low-protein fed rats. *Phytother Res* 2005;19(3):341-5.
23. Wolf A, Trendelenburg CF, Diez-Fernandez C, Prieto P, Houy S, Trommer WE, et al. Cyclosporine A-induced oxidative stress in rat hepatocytes. *J Pharmacol Exp Ther* 1997;280(3):1328-34.
24. Scott MD, Lubin BH, Zuo L, Kuypers FA. Erythrocyte defense against hydrogen peroxide: Preeminent importance of catalase. *J Lab Clin Med* 1991;118(1):7-16.
25. Prakash J, Gupta SK, Kochupillai V, Singh N, Gupta YK, Joshi S. Chemopreventive activity of *Withania somnifera* in experimentally induced fibrosarcoma tumours in Swiss albino mice. *Phytother Res* 2001;15(3):240-4.