

Case Study

SARCINA VENTRICULI-RELATED GASTRITIS: A RARE CASE OF GASTRIC INFECTION IN A PATIENT WITH DELAYED GASTRIC EMPTYING

PRIYA KUMARI¹, MONICA DASH², PRADEEP KUMAR MOHAPATRA³, PRAGNYA PARAMITA MISHRA^{1*}

^{1,2}Department of Pathology, Hitech Medical College, Rourkela, Odisha, India, ³Chief Medical Officer, Ispat General Hospital, SAIL, Rourkela
*Corresponding author: Pragnya Paramita Mishra; *Email: pparamita1982@gmail.com

Received: 15 Sep 2024, Revised and Accepted: 25 Oct 2024

ABSTRACT

Sarcina ventriculi (SV), which is also called *Clostridium ventriculi*, is a rare, non-motile, aerobic, Gram-positive coccus that breaks down carbohydrates through fermentation. It thrives in acidic environments, making the human stomach a suitable habitat, particularly in conditions associated with gastric stasis. SV belongs to the Clostridiaceae family. Recent studies have implicated *Sarcina ventriculi* in severe gastrointestinal conditions, including emphysematous gastritis, pyloric stenosis, gastroparesis, gastric outlet obstruction, gastric perforation, and gastric adenocarcinoma. Increased awareness of this organism and further studies are essential to understanding its role in human disease.

Keywords: Gastric ulcer, Gastritis, Perforation, *Sarcina ventriculi*

© 2024 The Authors. Published by Innovare Academic Sciences Pvt Ltd. This is an open access article under the CC BY license (<https://creativecommons.org/licenses/by/4.0/>)
DOI: <https://dx.doi.org/10.22159/ijcpr.2024v16i6.5092> Journal homepage: <https://innovareacademics.in/journals/index.php/ijcpr>

INTRODUCTION

The bacterium *Sarcina ventriculi* derived its name from the Latin word "Sarcina," meaning "package," due to its characteristic formation in groups of four or eight, its basophilic staining, and its refractive properties under light microscopy. It is an anaerobic, Gram-positive coccus, also known as *Clostridium ventriculi* [1]. It was first identified as a human pathogen in 1842 by John Goodsir [2], and it was first isolated in 1911 using strict anaerobic techniques from the stomachs of infected individuals. *Sarcina* has also been reported in the feces of healthy humans consuming a predominantly vegetarian diet [3]. Recent reports have shown an association between *Sarcina* in the stomach and chronic nausea, dyspepsia, abdominal pain, and gastric ulcers [4]. SV may rarely be responsible for emphysematous gastritis, a condition that can lead to gastric perforation. Patients infected with *Sarcina* have been found to have frothy vomitus, termed "sarcinate vomit" [5]. It is most

frequently recognized as a pathogen that affects animals. The pathogenic role of SV in humans remains unclear and is debated.

CASE REPORT

We report a case of *Sarcina* associated with gastritis in a 90-year-old male who had been suffering from vomiting, abdominal pain, anorexia, regurgitation, and delayed gastric emptying for two years. Routine hemogram was normal. Patient was subjected to ultrasonography of abdomen and pelvis, which was also normal. Then upper gastrointestinal (GI) endoscopy was done, which revealed thickened mucosal folds in the antrum, a growth in the duodenum (D1), Grade D gastroesophageal reflux disease (GERD), and gastric outlet obstruction. An endoscopic gastric biopsy was performed. Histopathological examination revealed small spherical microorganisms in a tetrad arrangement (fig. 1 and 2) within the inflammatory exudate. There was no evidence of metaplasia, dysplasia, or malignancy in the histopathologic sections studied.

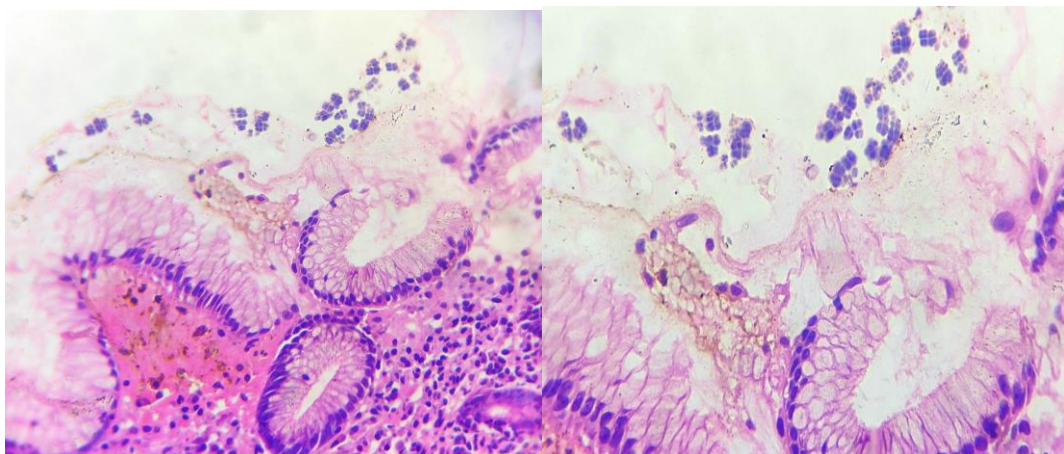


Fig. 1-2: Show foveolar mucosa with sarcina

DISCUSSION

Sarcina ventriculi is unique for its characteristic tetrad packet formation, a key identifying feature under microscopy. Gastritis

caused by *Sarcina ventriculi* is believed to result from its ability to produce carbon dioxide, leading to the formation of gas pockets within the gastric wall. This gas production can cause the mucosa to stretch and potentially rupture, resulting in emphysematous

gastritis-a rare but life-threatening condition characterized by the presence of gas within the stomach wall.

The clinical presentation of *Sarcina ventriculi*-associated gastritis can vary, ranging from mild dyspepsia to severe abdominal pain and vomiting. This variability often mimics other gastric disorders, complicating the diagnosis. Diagnosis is typically made via histopathological examination of gastric biopsies, where the distinctive morphology of the bacteria is observed. *Sarcina ventriculi* has also been found in individuals consuming a predominantly vegetarian diet and is associated with gastric ulcers and fungal yeast forms.

CONCLUSION

Sarcina ventriculi is likely underreported, as it may not be easily detected on routine biopsy stains. A review of reported cases, including ours, suggests that *Sarcina* is more frequently an innocent bystander rather than a pathogenic organism. Pathologists should be aware of this unusual organism and its uncertain significance. Treatment generally involves broad-spectrum antibiotics, although the optimal therapeutic approach remains uncertain due to the rarity of the condition. In cases of gastric outlet obstruction or other underlying conditions, surgical intervention may be necessary. The clinical relevance of *Sarcina ventriculi* in gastritis underscores the need for increased awareness among clinicians, particularly in patients with known risk factors for gastric stasis. Further research is required to establish clear guidelines for the management of this potentially serious infection.

FUNDING

Nil

AUTHORS CONTRIBUTIONS

All authors have contributed equally

CONFLICTS OF INTERESTS

There are no conflicts of interest

REFERENCES

1. Al Rasheed MR, Senseng CG. *Sarcina ventriculi*: review of the Literature. Arch Pathol Lab Med. 2016 Dec;140(12):1441-5. doi: [10.5858/arpa.2016-0028-RS](https://doi.org/10.5858/arpa.2016-0028-RS), PMID [27922772](https://pubmed.ncbi.nlm.nih.gov/27922772/).
2. Goodsir J, Wilson G. History of a case in which a fluid periodically ejected from the stomach contained vegetable organisms of an undescribed form. Edinb Med Surg J. 1842 Apr 1;57(151):430-43. PMID [30330668](https://pubmed.ncbi.nlm.nih.gov/30330668/), PMID [PMC5791290](https://pubmed.ncbi.nlm.nih.gov/PMC5791290/).
3. Crowther JS. *Sarcina ventriculi* in human faeces. J Med Microbiol. 1971;4(3):343-50. doi: [10.1099/00222615-4-3-343](https://doi.org/10.1099/00222615-4-3-343), PMID [5116255](https://pubmed.ncbi.nlm.nih.gov/5116255/).
4. Lam Himlin D, Tsiatis AC, Montgomery E, Pai RK, Brown JA, Razavi M. *Sarcina* organisms in the gastrointestinal tract: a clinicopathologic and molecular study. Am J Surg Pathol. 2011;35(11):1700-5. doi: [10.1097/PAS.0b013e31822911e6](https://doi.org/10.1097/PAS.0b013e31822911e6), PMID [21997690](https://pubmed.ncbi.nlm.nih.gov/21997690/).
5. Ferrier D. The constant occurrence of *Sarcina ventriculi* (Goodsir) in the blood of man and the lower animals: with remarks on the nature of Sarcinuous vomiting. Br Med J. 1872 Jan 27;1(578):98-9. doi: [10.1136/bmj.1.578.98](https://doi.org/10.1136/bmj.1.578.98), PMID [20746505](https://pubmed.ncbi.nlm.nih.gov/20746505/), PMID [PMC2297174](https://pubmed.ncbi.nlm.nih.gov/PMC2297174/).