

**PROTECTIVE EFFECT OF ABUTILON INDICUM L. (MALVACEAE) AGAINST ACETAMINOPHEN INDUCED NEPHROTOXICITY IN RATS**

**USHAKIRAN REDDY.T\*, MOHANA LAKSHMI. S, ASHOK KUMAR C. K, PRATHYUSHA. S, ANDSATEESH KUMAR. D**

Department of Pharmacognosy, SreeVidyanikethan College of Pharmacy, Tirupati- Andhra Pradesh, India, Email: usha.cognosy@gmail.com

*Received: 31 July 2013, Revised and Accepted: 31 August 2013*

**ABSTRACT**

Acetaminophen overdose can cause nephrotoxicity with oxidative stress as one of the possible mechanisms. The effects of ethanolic extract of Abutilon Indicum [200 mg per kg of body weight (mg/kg) and 400 mg/kg] on Acetaminophen induced nephrotoxicity were evaluated. Rats were divided into five groups containing 6 rats each. The control group received distilled water while other groups were treated with extract alone (400 mg/kg), Acetaminophen alone (750 mg/kg), 750 mg/kg Acetaminophen+200 mg/kg extract (Acetaminophen+ 200-extract), and 750 mg/kg Acetaminophen+400 mg/kg extract (Acetaminophen+400-extract), respectively, for seven consecutive days. The EEAI was given orally concurrent with oral administration of Acetaminophen Treatment with EEAI at doses of 200 and 400 mg/kg prevented the Acetaminophen-induced nephrotoxicity and oxidative impairments of the kidney, as evidenced by a significantly reduced ( $P < 0.05$ ) level of Serum creatinine, BUN, serum alkaline phosphatase, Serum uric acid, serum total proteins and total cholesterol. The nephroprotective effects of EEAI were confirmed by a reduced intensity of renal cellular damage, as evidenced by histological findings. Moreover, EEAI administered at 400 mg/kg was found to show greater protective effects than that at 200 mg/kg. In conclusion, EEAI has a protective role against Acetaminophen-induced nephrotoxicity and the process is probably mediated through its antioxidant properties.

**Keywords:** Cisplatin, nephrotoxicity, Abutilon indicum

**INTRODUCTION**

Acetaminophen (APAP), also known as paracetamol, is most widely used in the world as an analgesic and antipyretic agents belonging to the Para amino phenol class of non steroidal anti inflammatory drugs (NSAIDS) and is considered to be safe at therapeutic doses.<sup>1</sup> It is the most commonly reported toxic ingestion in the United States.<sup>2</sup> APAP is known to cause hepatic necrosis and renal failure in both humans and animals when administered in over doses.<sup>3</sup> Renal damage and acute renal failure can occur even in the absence of liver injury.<sup>4</sup> Renal insufficiency occurs in approximately 1–2% of patients with acetaminophen over dose.<sup>5</sup> Renal toxicity in acetaminophen poisoning has been attributed to cytochrome P-450 mixed function oxidase isoenzymes present in the kidney, although other mechanisms have been elucidated, including the role of prostaglandin. Acetaminophen over dose consequently leads to renal damage.<sup>6-8</sup>

Acetaminophen under goes deacetylation to p-aminophenol and bind to kidney proteins which is distributed to mitochondria, microsomes, cytosol and associated proteins DNA, mitochondrial enzymes and Glucose-6-phosphatase. Renal tubular damage and acute renal failure can occur even in absence of liver injury<sup>9</sup> and can even lead to fatality in humans and experimental animals. Acetaminophen is metabolized in both the liver and kidney. Nephrotoxicity may occur independently of hepatotoxicity depending on the balance of metabolism and glutathione stores within the kidney.<sup>10</sup> Acetaminophen given in increasing doses to male Wistar rats depleted glutathione stores in the liver and kidneys, large amounts of oxidative radio labeled metabolite bound to a hepatic and kidney protein then lead to a dose dependent acute hepatic and renal necrosis.<sup>11</sup> Tubular cell loss is a characteristic feature of both acute renal failure and chronic renal disease and is observed when cell death predominates over mitosis. Apoptosis is an acute form of cell death that offers the opportunity for therapeutic intervention.<sup>12</sup> Thus, our study is carried on screening program to evaluate the protective potentials of natural compounds. The objective of the present study is to determine the protective

effect of Abutilon indicum L. (Malvaceae) in Acetaminophen induced renal injury in rats.

**Materials and methods**

**Plant material**

The plant Abutilon indicum L. (Malvaceae) is widely distributed throughout South India. Abutilon indicum L. was collected from Tirumalahills, Tirupati, India in the month of December and it was identified and authenticated. The taxonomical identification and authentication was done by Dr. K. MadhavaChetty, Assistant Professor, Department of Botany, S.V. University, Tirupati. About 500 g of dried powder of Abutilon indicum was successively extracted with petroleum ether (60-80°C) for 8 hrs. to remove the fatty matter. The defatted marc was then subjected to soxhlet extraction with 95% ethanol to obtain ethanolic extract. After complete exhaustion of the drug it was filtered and the filtrate was concentrated on water bath (45°C) to remove the solvent and to get a sticky brown coloured extract i.e. ethanolic extract of Abutilon indicum. Aqueous extract was prepared by macerating the dried drug powder in double distilled water. The extract was concentrated in a water bath and stored in desiccators.

**Animals:** Adult Albino Wistar rats weighing about 150-180 g of either sex were procured from the animal house of SreeVidyanikethan College of Pharmacy, Tirupati. The animals were maintained in a well-ventilated animal house approved by Committee For The Purpose of Control and Supervision of Experiments on Animals (CPCSEA), with 12:12 hour light/dark cycle in propylene cages with  $27 \pm 2$  °C temperature. The animals were given standard pellet.

**Acute oral toxicity study:** The study was followed by using OECD-423 (Acute Toxic Class Method). Adult Wistar rats weighing 150-180g were used for the study. The starting dose level of EEAI was 2000mg/kg body weight p. o. volume was administered to overnight fasted rats with ad libitum. Food was withheld for further 3- 4 hours after administration of EEAI and observed for signs for toxicity. The

body weight of the rats before and after administration were noted that changes in skin and fur, eyes, mucous membranes, respiratory,

circulatory, autonomic and central nervous system and motor activity and behavior pattern were observed and also sign of tremors, convulsions, salivation, diarrhea, lethargy, sleep and coma were noted.

### Nephroprotective study

Method: Five groups of six rats in each were fasted and deprived of water for eighteen hours prior to the experiment. The first group of animals serving as control, received 2% v/v aqueous tween 80 solution (5ml/kg, p.o); the second group received 2% v/v aqueous tween 80 solution (5ml/kg, p.o) along with 750 mg/kg via the oral route of acetaminophen; the third group received cystone (5ml/kg, p.o); the fourth, fifth groups received the EEAI at the doses of 200 mg/kg and 400 mg/kg body weight orally daily for seven days respectively (Table 1). On the seventh day, paracetamol suspension was given by oral route, in a dose of 750 mg/kg body weight to all rats except the rats in group-I. The biochemical parameters were estimated 24 hrs following the last dose (Adeneyeet al., 2008)

**Table 1: Experimental design**

Groups	Treatment
Group I	2% v/v aqueous tween 80 solution (5ml/kg, p.o) [Control group]
Group II	2% v/v aqueous tween 80 solution (5ml/kg, p.o) + 750 mg/kg, p.o of acetaminophen
Group III	Cystone (5ml/kg, p.o) [Standard]
Group IV	200 mg/kg EEAI suspended in 2% v/v aqueous tween 80 solution, p.o + 750 mg/kg, p.o of acetaminophen
Group V	400 mg/kg EEAI suspended in 2% v/v aqueous tween 80 solution, p.o + 750 mg/kg, p.o of acetaminophen

Biochemical analysis: Blood samples were collected by cardiac puncture under diethyletheranaesthesia, using 21 gauge (21 G) mounted on a 5ml syringe (Hindusthan syringes and medical devices ltd, Faridabad, India.). Serum samples were analyzed for creatinine, blood urea nitrogen (BUN), uric acid, total protein, albumin, alkaline phosphatase, total cholesterol.13

Histopathological analysis: After the animals were sacrificed, the kidney samples were excised from the control and treated groups of animals and washed them with normal saline. They were fixed in 10% buffered formalin for 24 h and embedded in paraffin wax. Cross- sections of the kidney tissue (5-6µm thick) were prepared and stained with haematoxylin-eosin dye. The sections were evaluated by microscopical examination.14

Statistical analysis: Values are expressed as mean  $\pm$  SEM. Statistical analysis was performed by one-way analysis of variance (ANOVA) followed by Duncan's Multiple Range Test (DMRT). The values were considered statistically significant if the P- value is less than 0.05.15

### RESULTS AND DISCUSSION

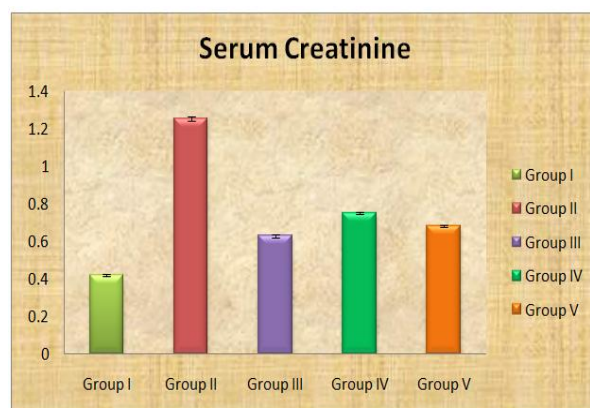
Acetaminophen is an effective, well tolerated, over-the-counter analgesic and antipyretic drug alternative to aspirin. Over doses or prolonged use is commonly associated with hepatotoxicity and nephrotoxicity in humans and in experimental animals.16-18 Acetaminophen nephrotoxicity results from the toxic effects of its reactive intermediate metabolite, N-acetyl-para-amino-benzoquinoneimine (NAPQI), which arylates proteins in the S3 segment of proximal tubule, initiating cell death of renal tubular cells.19 These drug induced nephrotoxicities are often associated with marked elevations in serum creatinine, blood urea nitrogen,

uric acid, total proteins, total cholesterol, alkaline phosphatase, albumin and acute tubular necrosis. Serum analysis for creatinine, blood urea nitrogen, uric acid, total proteins, total cholesterol, alkaline phosphatase, and albumin were analyzed after acetaminophen-induced toxicity and the protective potential of Abutilon indicum extract in rats. The histopathology study for kidney was also carried out to assess the protective effect of Abutilon indicum.

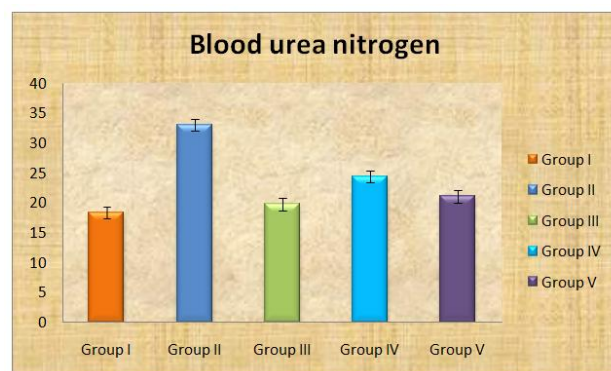
**Table 2: Effect of EEAI on serum parameters with/without acetaminophen treatment**

Treatment	Creatinine (mg/dl)	Blood urea nitrogen (mg/dl)	Uric acid (mg/dl)	Total protein (g/dl)	Total cholesterol (mg/dl)	Alkaline phosphate (IU)	Albumin (g/dl)
Group I	0.42 $\pm$ 0.01	18.35 $\pm$ 0.32	0.65 $\pm$ 0.04	5.8 $\pm$ 0.03	120.94 $\pm$ 0.13	73.5 $\pm$ 0.07	3.9 $\pm$ 0.02
Group II	1.25 $\pm$ 0.01	33.06 $\pm$ 0.4	3.4 $\pm$ 0.08	10.6 $\pm$ 0.25	152 $\pm$ 0.38	132.4 $\pm$ 0.02	7.45 $\pm$ 0.07
Group III	0.63 $\pm$ 0.02	19.75 $\pm$ 0.12	0.95 $\pm$ 0.03	6.8 $\pm$ 0.03	100.4 $\pm$ 0.6	84 $\pm$ 0.10	4.05 $\pm$ 0.09
Group IV	0.75 $\pm$ 0.02	24.42 $\pm$ 0.09	1.35 $\pm$ 0.02	7.02 $\pm$ 0.09	103.24 $\pm$ 0.5	89 $\pm$ 0.07	4.65 $\pm$ 0.1
Group V	0.68 $\pm$ 0.02	21.05 $\pm$ 0.07	1.14 $\pm$ 0.06	6.95 $\pm$ 0.04	101.52 $\pm$ 0.74	86.4 $\pm$ 0.04	4.43 $\pm$ 0.03

Values are expressed as mean  $\pm$  SEM of six different samples; P<0.05 compared with control by Duncan's Multiple Range Test (DMRT)



**Fig 1: Effect of EEAI on serum creatinine levels in acetaminophen induced nephrotoxic rats**



**Fig 2: Effect of EEAI on blood urea nitrogen levels in acetaminophen induced nephrotoxic rats**



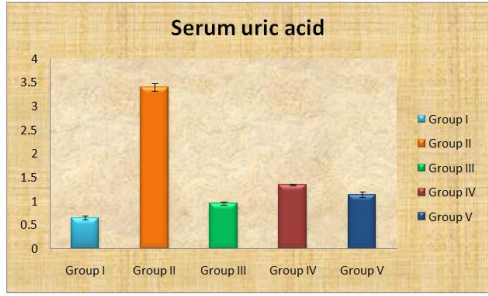


Fig 3: Effect of EEAI on serum uric acid levels in acetaminophen induced nephrotoxic rats

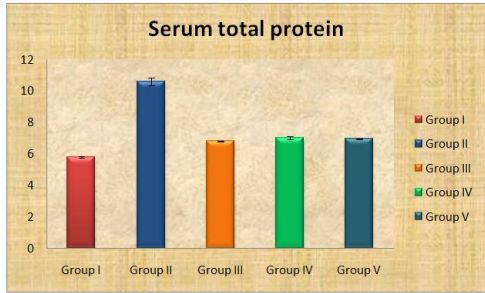


Fig 4: Effect of EEAI on serum total protein levels in acetaminophen induced nephrotoxic rats

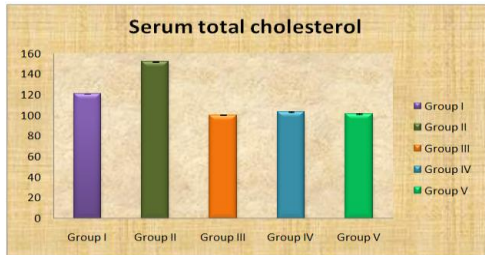


Fig 5: Effect of EEAI on serum total cholesterol levels in acetaminophen induced nephrotoxic rats

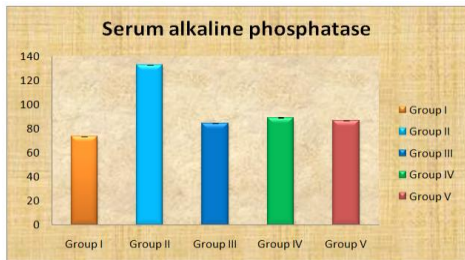


Fig 6: Effect of EEAI on serum alkaline phosphatase levels in acetaminophen induced nephrotoxic rats

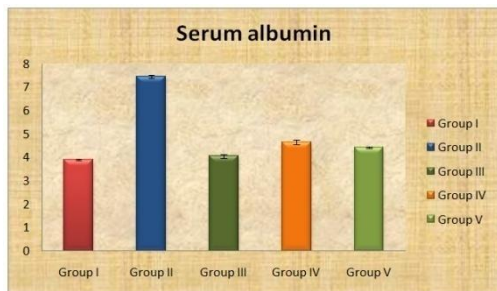

Fig 7: Effect of EEAI on serum albumin levels in acetaminophen induced nephrotoxic rats

Histopathological studies of the kidney in acetaminophen induced nephrotoxic rats

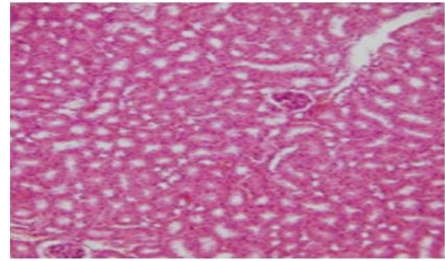


Fig 8: Histopathology of rat kidney in control group (10X)

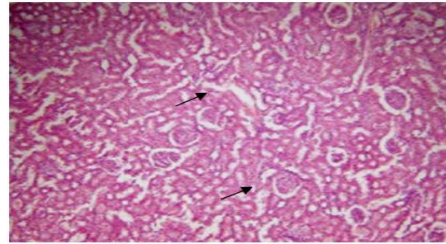


Fig 9: Histopathology of rat kidney in acetaminophen treated group (750mg/kg) (10X)

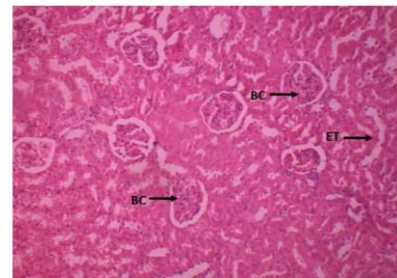


Fig 10: Histopathology of rat kidney in standard (cystone) (5ml/kg) (10X)

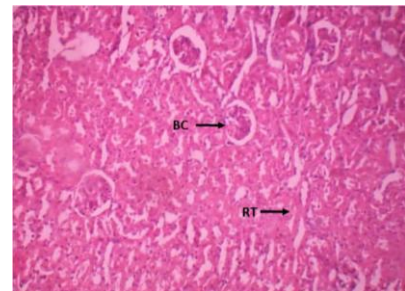


Fig 11: Histopathology of rat kidney in EEAI (200mg/kg) + acetaminophen treated group (10X)

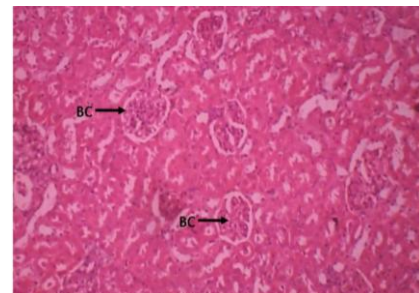


Fig 12: Histopathology of rat kidney in EEAI (400mg/kg) + acetaminophen treated group (10X)

The effect of graded oral dose of EEAI on serum creatinine concentrations, blood urea nitrogen, Serum uric acid, serum total proteins, total cholesterol, Serum alkaline phosphatase and serum albumin in acetaminophen-nephrotoxic rats for 7 days shows that single oral administration of 750mg/kg of acetaminophen suspension on the 7th day induced significant ( $p < 0.05$ ) rise in serum creatinine concentrations, blood urea nitrogen, Serum uric acid, serum total proteins, total cholesterol, Serum alkaline phosphatase and serum albumin in the acetaminophen treated rats (group II rats). However, elevations in all these parameters were significantly ( $p < 0.05$ ) attenuated by EEAI pretreatments, in dose related fashion. The biochemical alterations of acetaminophen nephrotoxicity were associated with multiple focal tubulonephritis with marked lymphocytic infiltration on histology when compared to normal renal architecture. However, EEAI pretreatment significantly improved the renal lesion.

APAP induced renal damage is consistent with acute tubular necrosis. In the present study, the results of histopathological examination showed a clear evidence of nephrotoxicity following the administration of APAP in an overdose. Acute tubular necrosis was the most relevant histopathological change. These results are in agreement with those of the previous investigation describing the renal histological alterations following the administration of APAP in an overdose. 20-21 EEAI pre-treatment ameliorated the APAP induced histopathological renal changes.

### CONCLUSION

The administration of Ethanol extract of *Abutilon Indicum* was found to have protective effects against Acetaminophen induced nephrotoxicity, as evidenced by the biochemical status and histological findings. The most remarkable effects were observed when the Ethanol extract of *Abutilon Indicum* was delivered at 400 mg/kg as compared to a lower dose of 200 mg/kg of the extract. This indicates that the amount of antioxidant compounds present in Ethanol extract of *Abutilon Indicum* contributes significantly to its antioxidant property. Together, the absence of renal damage and supportive evidence of its antioxidant properties may suggest the potential applications of Ethanol extract of *Abutilon Indicum* as an alternative antidote against Acetaminophen induced nephrotoxicity.

### REFERENCES

- Deshpande V., Varsha M.J., Kadam V.J. In-vitro anti-arthritis activity of *Abutilon indicum* (L.) Sweet. *Journal of Pharmacy Research* 2009; 2(4):644-645.
- Yasmin S, Kashmiri MA, Asghar MN, Ahmad M, Mohy-ud-Din A., Antioxidant potential and radical scavenging effects of various extracts from *Abutilon indicum* and *Abutilon muticum*. *Pharm Biol.* 2010;48(3):282-9.
- Trumper, L-Monastualo LA, Elias MM. Probencid protects against -in vivo acetaminophen induced nephrotoxicity in male wistar rats. *J-pharmacol.Exp:therapeut.* 1998; 283: 606-610.
- Tripathi P, Chauhan NS, Patel JR., Anti-inflammatory activity of *Abutilon indicum* extract. *Nat Prod Res.* 2011 Oct 14.
- Soejarto D.D, Fong H.H.S, Tan G.T, Zhang H.J, Ma C.Y, Franzblau S.G. Ethnobotany/ethnopharmacology and mass bioprospecting: Issues on intellectual property and benefit sharing. *J. Ethnopharmacol.* 2005;100(1-2):15-22.
- Seetharam YN., Gururaj Chalgeri, Ramachandra Setty and Bheemachar. Hypoglycemic activity of *Abutilon indicum* on albino rats. *Fitoterapia* 2002;73:156-159.
- Aamdal S, Fodstad O, Pihl A. Sodium thiosulfate fails to increase the therapeutic index of intravenously administered cis-diamminedichloroplatinum(II) in mice bearing murine and human tumors. *Cancer Chemotherapy Pharmacol.* 1988; 21: 129-133.
- Abdul RA, Gopalakrishnan G, Venkatesan P, Geetha K. Isolation and *Abutilon indicum* (Linn.) Sweet. *Parasitology Research* 2008;102(5): 981-988.
- Abraham. P. Vitamin C may be beneficial the prevention of paracetamol-induced renal damage. *Clin. Exp. Nephrol.* 2005;9: 24-30.
- E. Porchezian, Ansari S.H. Hepatoprotective activity of *Abutilon indicum* on experimental liver damage in rats. *Phytomedicine: International Journal of Phytotherapy & Phytopharmacology* 2005; 12: 62-64.
- Fausser A.A, Fellhauer M, Hoffman M, Link H, Scilmok G, Gralla R. J. Guidelines for anti-emetic therapy: acute emesis. *Eur J Cancer* 1999; 35:361-370.
- Gaind KN, Chopra KS., Phytochemical investigation of *Abutilon indicum*; *Planta Med.* 1976; 30(2):174-88.
- Khorsandi L, Orazizadeh M., Protective effect of *Curcuma longa* extract on acetaminophen induced nephrotoxicity in mice DARU 2008; 16(3): 155-159.
- Lachman J, Pronek D, Hejtmanekova A, Dudjak J, Pivek V & Faitova K. Total polyphenol and main flavonoid antioxidants in different onion (*Allium cepa* L) varieties. *Horticultural Science* 2003; 30(4):142-147.
- Orchezian E., Anasri S.H. Hepatoprotective activity of *Abutilon indicum* on experimental liver damage in rats. *Phytomedicine* 2005;12:62-64.
- Padma V.R., Senthil K. Antimycotic activity of the component of *Abutilon indicum* (Malvaceae). *Drug Invention Today* 2009;1(2):137-139.
- Patwardhan B, Hooper M. Ayurveda and future drug development. *Int. J. Alternative Complement. Med.* 1992;10: 9-11.
- Patwardhan B. Ethnopharmacology and drug discovery. *J. Ethnopharmacol.* 2005;100(1-2): 50-52.
- Rajalakshmi P.V., K. Kalaiselvi Senthil. Direct Hplc Analysis of Quercetin in Exudates of *Abutilon Indicum* (Linn). *Malvaceae. Journal of Pharmaceutical Science and Technology.* 2009;1(2): 80-83.
- Ganga suresh P, R Ganesana, M Dharmalingama, S Baskar a, P. Senthilkumar. Evaluation of Wound Healing Activity of *Abutilon indicum* Linn in Wistar Albino Rats. *Int J Biol Med Res.* 2011; 2(4):908-91.
- Ghaisas MM, Navghare VV, Takawale AR, Zope VS, Phanse MA. Antidiabetic and Nephroprotective effect of *Tectonagrandis* Linn. In Alloxan induced Diabetes. *Ars Pharm.* 2010; 51(4):195-206.