

## MITIGATING EFFECTS OF *ZINGIBER OFFICINALE* AGAINST REPRODUCTIVE TOXICITY INDUCED BY DICHLORVOS IN MALE RATS

BHAWANA SHARMA<sup>1</sup>, PRIYANKA SHARMA<sup>1</sup>, S. C. JOSHI<sup>1\*</sup>

<sup>1</sup>Reproductive Toxicology Unit, Department of Zoology, University of Rajasthan, Jaipur 302004, India  
Email: s\_c\_joshi2003@rediffmail.com

Received: 26 Nov 2016 Revised and Accepted: 20 Mar 2017

### ABSTRACT

**Objective:** Aim of this study was to evaluate the effect of *Zingiber officinale* in mitigating oxidative damage and reproductive toxicity in the testis, induced by chronic dichlorvos administration in male Wistar rats.

**Methods:** Twenty-four adult male Wistar rats were divided into 4 groups of 6 rats in each group. Group I received olive oil (1 ml/kg bwt/day) and served as control group, while Group II was administered dichlorvos (20 mg/kg bwt/day) and Group III and IV received a combination of dichlorvos (20 mg/kg bwt) and *Zingiber officinale* (ginger) extract (100 and 200 mg/kg bwt) for 45 d. At the end of the treatment period, the rats were sacrificed under light ether anesthesia.

**Results:** The weight of the reproductive organs and serum FSH, LH and testosterone levels were assayed. Lipid peroxidation (indexed by MDA) and antioxidant enzymes glutathione, superoxide dismutase, catalase were also analysed. Dichlorvos treatment significantly ( $P \leq 0.05$ ) decreased the weight of testis and epididymis as well as the serum levels of FSH, LH and testosterone. There was a highly significant ( $P \leq 0.01$ ) decrease in the activities of glutathione, superoxide dismutase and catalase as well as significantly ( $P \leq 0.05$ ) increases in lipid peroxidation activity. However, extract of *Zingiber officinale* also attenuates significantly ( $P \leq 0.05$ ) ( $P \leq 0.01$ ) the hormonal level and antioxidant enzyme activity in the dichlorvos exposed animals.

**Conclusion:** Co-administration of aqueous extract of *Zingiber officinale* with dichlorvos showed the protective effect and significantly increases the reproductive organs weight and enhances serum hormones level along with increased antioxidants activities and reduced lipid peroxidation. This indicates that *Zingiber officinale* mitigates reproductive toxicity and oxidative damage induced by dichlorvos exposure due to its antioxidant activity in the testes.

**Keywords:** Dichlorvos, *Zingiber officinale*, Androgenic, Antioxidants and Lipid peroxidation

© 2017 The Authors. Published by Innovare Academic Sciences Pvt Ltd. This is an open access article under the CC BY license (<http://creativecommons.org/licenses/by/4.0/>)  
DOI: <http://dx.doi.org/10.22159/ijpps.2017v9i5.16346>

### INTRODUCTION

Environmental pollution from pesticides is an imperative issue that attracts widespread public concern [1], due to the prevalent use of pesticide in agriculture and in public health programs [2]. Pesticides are the general term for insecticides, fungicides, herbicides, acaricides, rodenticides, etc [3]. They are widely used in agriculture, industry and for public health purposes. Unfortunately, pesticides are toxic to a greater or lesser extent towards non-target organisms, including humans. Organophosphate (OP) pesticides are among the most widely used synthetic chemicals for controlling a wide variety of pests. These compounds manifest their toxicity by the inhibition of acetylcholinesterase (AChE) activity in the target tissues and/or neuropathy target esterase (NTE), which acts on the central and peripheral nervous system [4].

Dichlorvos (2, 2 dichlorovinyl dimethyl phosphate; DDVP), is a household and agricultural pesticide used for the protection of grains and stored products, traded under names such as *Sniper*, *Nuvan* and *Ota-piapia* [5]. It's also used to treat external parasitic infections in livestock, farmed fish and domestic animals [6]. Dichlorvos is reported to cause toxicity of brain [7], pancreas [8], kidney and spleen [9], the reproductive system [10] and immune system [11].

Many studies have implicated that induction of oxidative damage as the central mechanism of toxicity [12-14]. Pesticides are known to increase the production of reactive oxygen species (ROS), which in turn, generating reactive oxygen species (ROS) and supporting oxidative stress in different tissues [15]. Organophosphorus insecticides (OPs) may also induce oxidative stress leading to the generation of free radicals and alteration in the antioxidant system in the host. The mechanism associated with both acute and chronic

dichlorvos poisoning is the oxidative stress [16]. The antioxidant machinery is composed of enzymatic and non-enzymatic components [17]. The antioxidant enzyme defence system is made up of free radical scavengers like glutathione (GSH), glutathione peroxidase (GPx), glutathione reductase (GR) and glutathione-S-transferase (GST) as well as superoxide dismutase (SOD) and catalase (CAT) [18]. The antioxidant enzymes like SOD, Catalase and GSH have been shown to be significantly affected by pesticides including dichlorvos [19].

Excess production of ROS can cause oxidative damage of DNA, proteins and lipids. Endogenous enzymatic superoxide dismutase (SOD), catalase (CAT) and non-enzymatic glutathione (GSH) antioxidants detoxify these ROS and protect cells [20]. Due to continuous exposure of pesticides, the level of these endogenous antioxidants decreases, leading to apoptosis. Under this circumstance, therefore, there is the need to supply the body with exogenous antioxidants.

Many phytochemicals have been found to play a crucial role as dynamic antioxidants and antimicrobials [21]. A number of medicinal plants have been described to acquire reactive oxygen species (ROS) scavenging and cytoprotective properties [22].

*Zingiber officinale* (Ginger) has been shown to possess many pharmacological and physiological activities such as antioxidants, anti-inflammatory, anti-carcinogenic, analgesic, antiemetic, cardioprotective and gastroprotective effects, which account for its usefulness in traditional medicine for a number of disorders [23]. It contains a host of compounds which includes acid resins, vitamin C compounds [folic acid, choline, inositol and pantothenic acid], vitamin B3 and B6, gingerol, a sesquiterpene, volatile oils and bio-trace elements [Ca, Mg, K and P] [24]. This medicinal herb is

exceptional for oral therapy as it is effective, non-toxic and without serious side effects. Ginger extracts scavenge hydroxyl radicals and superoxide anion and reduce oxidative stress [25].

Thus the present study was undertaken to evaluate the protective role of *Zingiber officinale* on reproductive toxicity and oxidative stress in the testes induced by dichlorvos pesticide in male wistar rats.

## MATERIALS AND METHODS

### Animals and animal treatment

Healthy adult twenty-four male albino rats (*Rattus norvegicus*, Wistar Strain) (weight approximate 150-200 g) with proven fertility were used for the experimentation. The animals were housed individually in plastic cages, maintaining at a room temperature (21-24 °C±3 °C) in the uniform light-dark cycle (14:10:L: D). The animals were maintained on standard pellet diet procured from Ashirwad Industries, Chandigarh (India). They were given clean water *ad libitum*. Animals were quarantined for 10 d before the beginning of the experiments. The guidelines for care and use of animals for scientific research [26] were strictly followed throughout the course of the investigation. The experimental protocol has the approval of the Institutional Animal Ethics Committee (IAEC). (UDZ-13/ 18.12.13)

### Chemicals and reagents

Technical grade dichlorvos (2, 2-dichlorovinyl dimethyl phosphate) obtained from Sudarshan crop, ltd., Jaipur (Raj.) (India) was used for experimentation. The insecticide was dissolved in olive oil and administered to animals through oral intubations. All other chemicals used in the study were of analytical grade.

### Plant material

Fresh ginger rhizome was collected from the local market of Jaipur, Rajasthan, India and authenticated at the Herbarium, Department of Botany, University of Rajasthan, Jaipur in comparison with the preexisting voucher specimen (RUBL 211509). Rhizomes (underground stem) of *Zingiber officinale* were washed thoroughly shed dried and powdered. Shed dried rhizome of ginger was extracted with distil-water for 36-48 h by soxhlet extraction method. The extract was filtered and then water was separated under reduced pressure to obtain a solid mass. Olive oil was used as a vehicle for the pesticides and distilled water for ginger.

### Experimental design

Male adult albino rats (Wistar strain) weighing 150-200g were used in the present study. After acclimatization, the rats were assigned randomly to four groups, each with 6 rats, as follow:

**Group I (G1):** Control rats were given normal diet and olive oil for 45 d.

**Group II (G2):** Dichlorvos (20 mg/kg bwt) for 45 d.

**Group III (G3):** Dichlorvos (20 mg/kg bwt) followed by *Zingiber officinale* extract (100 mg/kg bwt) for 45 d.

**Group IV (G4):** Dichlorvos (20 mg/kg bwt) followed by *Zingiber officinale* extract (200 mg/kg bwt) for 45 d.

At the end of the study, animals were killed. Testes and other reproductive organs were dissected out and washed with 0.9% NaCl and stored at -4 °C for further processing.

### Fertility test

The mating exposure test of all the animals was performed. They cohabited with normal pro-estrous females in the ratio of 1:3. The vaginal plug and presence of sperms in the vaginal smear were checked for positive mating. Females were separated and resultant pregnancies were noted when dams gave birth [27].

### Body and organ weight measurements

The body weight has been recorded on the initial day of the experiment and also on the day of sacrifice (46<sup>th</sup> d), both the control and experimental groups, by using automatic balance. Blood was collected in sterile tubes by cardiac puncture for haematological studies and serum was separated for serological studies. The

similarly weight of different reproductive organs (testis, seminal vesicle, prostate and epididymis) was also recorded.

### Sperm dynamics

#### Sperm motility

Sperm was collected as quickly as possible after a rat was dissected. The cauda epididymis was cut by surgical blades into 1 mm pieces approximately in 1 ml phosphate buffer saline solution at 37 °C. The solution was pipette several times in order to homogenise the sperm suspension and one drop of the suspension was placed on a slide, covered by cover slips and evaluated by using phase contrast microscope. Sperm motility was categorised into "motile" or "immotile". Results were recorded as a percentage of sperm motility [28].

#### Sperm density

The sperm density of testes and cauda epididymis was determined by Prasad *et al.* (1972). The testes and epididymis were removed immediately after anesthesia. Testicular and epididymal fluid with spermatozoa were diluted with physiological saline (0.9% NaCl) and placed on a Neubauer's chamber slide. The sperm cell suspension was pipetted several times to make a homogenous cell suspension and examined within five minutes after their isolation from testes and epididymis. The results were determined by counting both motile and immotile sperms in at least ten separate and randomly selected fields. Testicular and epididymal sperm suspension were evaluated as million sperm cells per ml of suspension by using phase contrast microscope and the sperm was counted manually.

#### Oxidative stress and antioxidant parameters in tests

Lipid peroxidation (LPO) [29], Catalase (CAT) [30], Glutathione (GSH) [31] and Superoxide dismutase (SOD) [32] were assessed by standard methods.

#### Hormonal analysis

Levels of testosterone, FSH and LH were determined in serum of male rats by Radioimmunoassay (RIA) technique by a LKB gamma Counter [33].

#### Statistical analysis

The data were analyzed statistically by using ANOVA and the significance of differences was set at  $P \leq 0.05$  (significant) and  $P \leq 0.01$  (highly significant) levels.

## RESULTS

### Body and organs weights

Tests and other reproductive organs weight of experimental male rats are presented in table 1. A significant ( $P \leq 0.05$ ) decrease in the testes weight was observed in the group that treated with dichlorvos alone (G2) as compared to the control group (G1). Similarly, the weight of other reproductive organs (epididymis, prostate and seminal vesicles) was also reduced significantly in the group treated with dichlorvos.

However, a highly significant ( $P \leq 0.01$ ) increase in testes and other reproductive organs weight were noted in *Z. officinale* treated group at both dose levels (20 mg/kg bwt of dichlorvos+100 and 200 mg/kg bwt of *Z. officinale* extract) (Group G3 and G4) as compared to the control rats.

### Sperm parameters

A severe impairment of sperm motility in cauda epididymis was observed (fig. 1). The sperm density in the testes and cauda epididymis were significantly reduced ( $P \leq 0.01$ ) after treatment with dichlorvos compared with their respective controls (fig. 2, 3). Whereas, co-administration of ginger with dichlorvos attenuates the decrease in sperm density and motility when compared with the dichlorvos treated rats, with the sperm count and motility reaching closer to the control values. There were significant increases ( $P \leq 0.01$ ) in sperm density and motility with co-administration of *Z. officinale* and dichlorvos when compared with dichlorvos treated group.

Table 1: Reproductive organ weight of control and other experimental rats for 45 d

Treatment	Group	Reproductive organ weight (mg/100 g body weight)			
		Testes	Epididymis	Prostate	Seminal vesicle
Group I Control (Olive oil only)	G1	1164.94 ±4.45	521.34 ±5.61	355.79 ±9.07	422.54 ±3.79
Group II 20 mg/kg. bwt of dichlorvos	G2	959.84* ±8.01	441.24* ±13.65	266.83 <sup>ns</sup> ±5.75	309.12 <sup>ns</sup> ±3.54
Group III 20 mg/kg. bwt of dichlorvos+100 mg/kg. bwt of <i>Zingiber officinale</i>	G3	1074.92** ±13.71	479.57** ±10.67	298.52* ±11.28	368.14** ±8.62
Group IV 20 mg/kg. bwt of dichlorvos+200 mg/kg. bwt of <i>Zingiber officinale</i>	G4	1111.68**±18.79	508.02** ±9.23	320.36** ±10.52	402.14** ±9.31

(Group II compared with Group I; Group III and IV compared with Group II), (mean±SEM of 6 Animals), ns = non-significant, \* = significant (P≤0.05), \*\* = highly significant (P≤0.01)

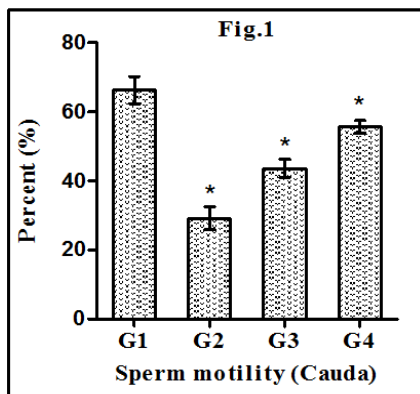


Fig. 1: Shows the percentage of sperm motility in cauda epididymis

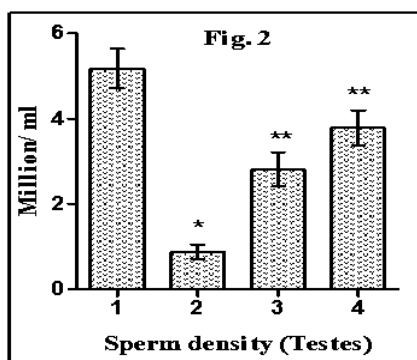


Fig. 2: Shows the value of sperm density in testes. There is statistical significance: ns = non-significant, \* = significant (P≤0.05), \*\* = highly significant (P≤0.01) in the group of dichlorvos exposure treated with *Zingiber officinale* (G3 and G4) as compare to dichlorvos exposure only group (G2)

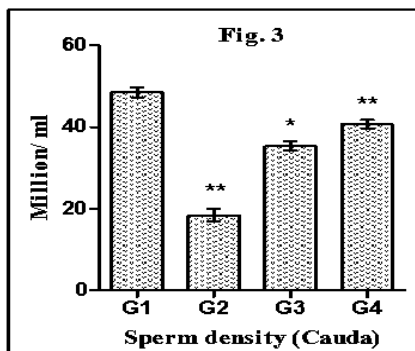


Fig. 3: Shows the value of sperm density in cauda epididymis

Control rats showed 100% positive fertility by mating exposure test. The rats administered with dichlorvos at 20 mg/kg. b. wt./day dose level showed 80% negative fertility whereas co-administration of *Z. officinale* with dichlorvos exhibited 70% and 80% positive fertility as compared to control group (fig. 4).

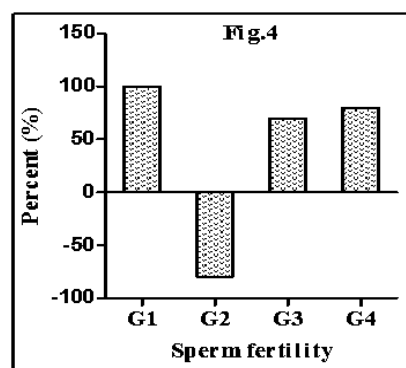


Fig. 4: Shows the percentage of fertility rate. There is statistical significance: \* = significant (P≤0.05), \*\* = highly significant (P≤0.01) in the group of dichlorvos exposure treated with *Zingiber officinale* (G3 and G4) as compare to dichlorvos exposure only group (G2)

Antioxidant and oxidative stress parameters analysis

The effects of dichlorvos and *Z. Officinale* extract on antioxidant parameters are presented in fig. 5,6,7,8.

Changes in lipid peroxidation level

The exposure to dichlorvos alone induced lipid peroxidation of the testicular membrane as revealed by a significant (P≤0.05) increase in MDA at 20 mg/kg bwt of dose level. Treatment with *Z. officinale* succeeds highly significantly (P≤0.01) to prevent lipid peroxidation of the membrane induced by combined exposure to dichlorvos and ginger at both dose levels (fig. 5).

Changes in GSH levels

The GSH level decreased highly significantly (P≤0.01) in the rats treated with dichlorvos. Aqueous extracts of *Z. officinale* administered with dichlorvos significantly (P≤0.05) improved the content of GSH levels in the blood to restoring the level closer to those in control animals (fig. 6).

Changes in SOD activity

One of the major factors in the protection from superoxide anions is SOD, which dismutates superoxide to hydrogen peroxide. Dichlorvos exposure at the dose of 20 mg/kg bwt induced a highly significant (P≤0.01) decrease in the activity of SOD in comparison to the control group. Animals co-treated with dichlorvos and ginger extract restored the level of SOD closer to untreated normal animals at the both dose level respectively (20 mg/kg bwt of dichlorvos+100 and 200 mg/kg bwt of *Z. Officinale* extract) (fig. 7).

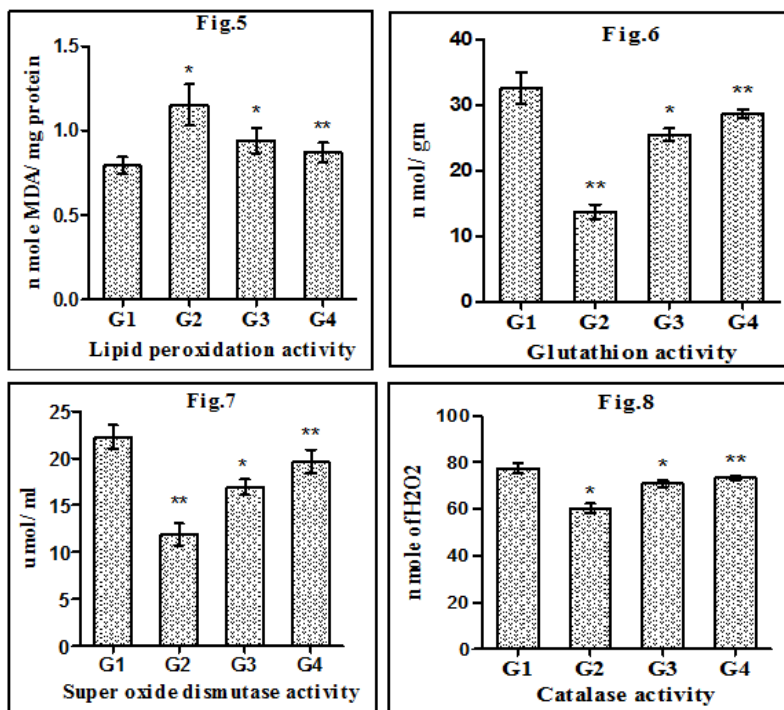


Fig. 5, 6, 7, 8: Shows the level of LPO (MDA concentration), Glutathione, superoxide dismutase and catalase activity in testes. There is statistical significance: \* = significant (P≤0.05), \*\* = highly significant (P≤0.01) in the group of dichlorvos exposure treated with *Zingiber officinale* (G3 and G4) as compare to dichlorvos exposure only group (G2)

**Changes in catalase activity**

Catalase is responsible for the catalytic decomposition of H<sub>2</sub>O<sub>2</sub> to oxygen and water. There was significant (P≤0.05) decrease in the catalase activities in dichlorvos treated in comparison with control group.

Simultaneous administration of *Z. officinale* elevated highly significantly (P≤0.01) to reverse the decline in activity of CAT in the rats co-exposed to dichlorvos and *Z. officinale* at both dose levels (20 mg/kg bwt of dichlorvos+100 and 200 mg/kg bwt of *Z. officinale* extract) (fig. 8).

**Hormonal analysis**

Data presented in fig. 9, 10, 11 showed highly significant (P≤0.01) decrease in serum testosterone, FSH and LH concentration in rats treated with dichlorvos compared to control. While, *Z. officinale* extract treatment increased the testosterone, FSH and LH levels significantly (P≤0.05) at the dose-dependent manner. This extract mitigated the toxic effects of dichlorvos treated group on this parameter. Dichlorvos administration alone lowered the level of testosterone, FSH and LH levels, but a combination of dichlorvos and *Z. officinale* extract recovered the testosterone, FSH and LH levels.

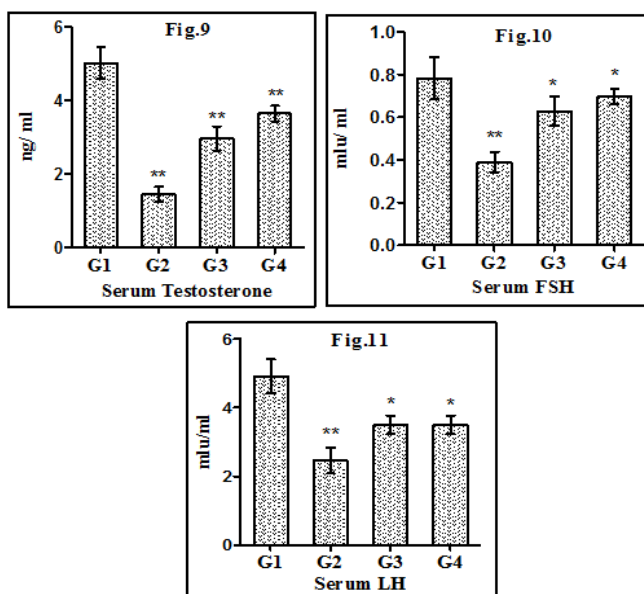


Fig. 9, 10, 11: Shows the level of testosterone, FSH and LH hormone in serum. There is statistical significance: \* = significant (P≤0.05), \*\* = highly significant (P≤0.01) in the group of dichlorvos exposure treated with *Zingiber officinale* (G3 and G4) as compare to dichlorvos exposure only group (G2)

## DISCUSSION

The present study explained that reproductive toxicity and oxidative damage were observed after the oral administration of 20 mg/kg bwt of dichlorvos for 45 d. The reduced weight of testes may be due to elongated spermatids, loss of germ cells, reduced tubular size, spermatogenic arrest and inhibition of steroid synthesis by Leydig cells [34]. The decreased testes weight in the dichlorvos treated rats clearly indicated that the dichlorvos induced a structural and functional alteration in the sex organs and the decrease in testicular mass was consistent with elimination of germ cells [35]. The reduction in weight of accessory sex organs may be due to low availability of androgens or antiandrogenic activity of dichlorvos [36]. Co-administration of dichlorvos and ginger extract in both groups (G3 and G4) clearly restored the reproductive organ indices towards its androgenic activity [37, 38].

Our results revealed that treatment of rats with dichlorvos significantly reduced the sperm count and motility. The decreased density (count) and sperm motility after oral administration of dichlorvos may be due to androgen insufficiency, which caused impairment in testicular function by altering the activities of the enzymes responsible for spermatogenesis [39]. The 80% negative fertility may be attributed to lack of forward progression and reduction in density of spermatozoa and altered biochemical milieu of cauda epididymis [40]. The decreased fertility in the dichlorvos treated rats has been attributed to impairment in sperm motility and viability [41]. *Zingiber officinale* has been previously shown to stimulate spermatogenesis [42]. In our study co-treatment with dichlorvos and *Z. officinale* attenuated spermatogenic/testicular damage induced by dichlorvos treatment as shown by the return of sperm density, motility and fertility toward normal control values.

Oxidative stress refers to disrupted redox equilibrium between the production of free radicals and the ability of cells to protect the damage caused by reactive oxygen species. Defence against oxidative stress are maintained by using several mechanisms which include antioxidant machinery [43].

Lipid peroxidation (LPO) is the parameter most often employed for testing oxidative damage in the human body. LPO, as revealed by enhanced MDA levels in tissues, represents one of the most common reactions of free radical attack on biological membranes resulting from the disturbance of the oxidant/antioxidant balance in the biological system [44, 45]. MDA is the most abundant aldehyde arising from lipid peroxidation [46] and hence is used as an index of oxidative damage in tissues. The elevated MDA concentration indicates an ongoing oxidative damage to the testicular tissues.

Higher MDA levels due to dichlorvos in the present study indicated that damage to the biological membranes from an increase in free radicals and ROS generated during the dichlorvos metabolism in the body. Simultaneous administration of the extracts of *Z. officinale* exerted protective effects on MDA levels in co-exposed dichlorvos and *Z. officinale* rats.

In present study reduction in tissue glutathione (GSH) levels may be a result of increased oxidative stress by the treatment of a high dose of pesticide [47]. Animals co-treated with dichlorvos and ginger extract showed a significantly elevated level of GSH. It is possible that extract might have reduced the extent of oxidative stress, leading to lesser GSH degradation or increase in the biosynthesis of GSH [48].

Dichlorvos caused a significant decrease in the activities of SOD and CAT. Antioxidant enzymes, mainly SOD (Superoxide dismutase) is the first line of defence against free radical-induced oxidative stress. SOD is responsible for the catalytic dismutation of highly reactive and potentially toxic superoxide radicals to hydrogen peroxide [49-51]. CAT is responsible for the catalytic decomposition of hydrogen peroxide to molecular oxygen and water [52]. Dichlorvos treatment resulted in a significant decrease in the levels of SOD and catalase (CAT) activity in testicular tissue of rat in comparison with the control group, which can reduce the protection against oxidative stress [53-55]. There was an inhibition of lipid peroxidative damage evidenced by reduced MDA level, elevation of

SOD and catalase activities in the rats co-treated with dichlorvos and *Z. officinale* extract. This finding is consistent with previous findings that ginger significantly lowered lipid peroxidation [56] by maintaining the activities of the antioxidant enzymes; SOD and CAT in the rat testes [57].

Antioxidant levels in the testes of rats co-treated with dichlorvos and *Zingiber officinale* shows a normal range not significantly different from that obtain in the control rats. This shows the beneficial role of *Z. officinale* in the treatment of oxidative stress [58]. Oxidative stress results when the endogenous antioxidants have been overwhelmed by the amount of free radical generation. Therefore, the increase in the exogenous supply of antioxidants by *Z. officinale* in this study is an indication of improvement of reproductive capacity to cope with free radicals.

Testosterone is the principal androgen of the testes and it is essential for sperm production and maintenance of accessory sex organs [59]. Reduction in the serum testosterone clearly demonstrated the inhibitory effect of dichlorvos on the secretion of pituitary gonadotropins (FSH and LH) and in turn on testosterone biosynthesis [60]. The low level of testosterone arrests spermatogenesis in the testes [61, 62] and reduction in the FSH and LH affects the development and function of testes and inhibit the development of seminiferous tubule [63]. Co-treatment with dichlorvos and *Z. officinale* effectively ameliorate dichlorvos toxicity in adult male albino rats by significantly raising serum testosterone, LH and FSH levels. *Zingiber officinale* has been previously shown to stimulate spermatogenesis. The restoration of testosterone, LH, and FSH levels to normal after co-administration with dichlorvos and *Z. officinale* might have stimulated the production of quantitatively and structurally normal sperms.

## CONCLUSION

The present study has shown that chronic dichlorvos exposure causes reproductive toxicity and oxidative changes in the testes. Therefore, we speculate that some of the deficits in male reproductive parameters that have been previously associated with chronic dichlorvos exposure may be partly due to this oxidative damage. Therefore it is concluded that *Zingiber officinale* played the vital role in combating the deleterious effect of dichlorvos and therefore may likely reduce adverse male reproductive performance outcome associated with dichlorvos exposure. Hence, *Z. officinale* may be the best antidote against dichlorvos induced toxicity.

## ACKNOWLEDGEMENT

The authors are thankful to the Head, Department of Zoology, University of Rajasthan, Jaipur and Coordinator of CAS (Centre for advance Studies) for providing necessary facilities.

## ABBREVIATION

*Z. officinale*, *Zingiber officinale*; SOD, Superoxide dismutase; CAT, Catalase; LPO, Lipid peroxidation; GSH, Glutathione; MDA, Malondialdehyde; ROS, Reactive oxygen species; FSH, Follicle stimulating hormone; LH, Luteinizing hormone.

## CONFLICT OF INTERESTS

All authors state that there is no conflict of interest with the work done in this study.

## REFERENCES

1. John S, Kale M, Rathore N, Bhatnagar D. Protective effect of vitamin E in dimethoate and malathion induced oxidative stress in rat erythrocytes. J Nut Biochem 2001;12:500-4.
2. Celik I, Suzek H. Effects of subacute exposure of dichlorvos at sublethal dosages on erythrocytes and tissue antioxidant defence systems and lipid peroxidation in rats. Ecotoxicol Environ Saf 2009;72:905-8.
3. Hamid S, Sharm S, Razdan S. Carbaryl, a pesticide causes "Reproductive Toxicity" in Albino Rats. J Clin Exp Pathol 2012;2:126.
4. Verma RS, Mehta A, Srivastava N. Comparative studies on chlorpyrifos and methyl parathion-induced oxidative stress in

- different parts of rat brain: attenuation by antioxidant vitamins. *Pestic Biochem Physiol* 2009;95:152-8.
5. Olatunde O, Fabian VE, Bukola SA, Sheu R, Effiong EA, Ganiyu OA. Histological changes in liver and lungs of rats exposed to dichlorvos before and after vitamin supplementation. *Eur J Anat* 2012;16:190-8.
  6. Erdogan O, Atamanalp M, Sisman T, Akasaki E, Alak G. Effects of 2, 2-Dichlorovinyl dimethyl phosphate (DDVP) on Hsp70 gene expression in rainbow trout. *Israeli J Aquaculture-Bamidgeh* 2007;59:230-4.
  7. Diwivedi N, Bhutia YD, Kumar V, Yadav P, Kushwaha P, Swarnkar H, *et al.* Effects of combined exposure to dichlorvos and monocrotophos on blood and brain biochemical variables in rats. *Hum Exp Toxicol* 2010;29:121-9.
  8. Hagar HH, Fahmy AH. A biochemical, histochemical, and ultrastructural evaluation of the effect of dimethoate intoxication on rat pancreas. *Toxicol Lett* 2002;133:161-70.
  9. Verma RS, Srivastava N. Effect of chlorpyrifos on thiobarbituric acid reactive substances scavenging enzyme and glutathione in rat tissues. *Indian J Biochem Biophys* 2003;40:423-8.
  10. Joshi SC, Mathur R, Gajraj A, Sharma T. Influence of methyl parathion on reproductive parameters in male rats. *Environ Toxicol Pharmacol* 2003;14:91-8.
  11. Neishabouri EZ, Hassan ZM, Azizi E, Ostad SN. Evaluation of immunotoxicity induced by diazinon in C57bl/6 mice. *Toxicology* 2004;196:173-9.
  12. Celik I, Suzek H. Effects of subacute exposure of dichlorvos at sublethal dosages on erythrocytes and tissue antioxidant defence systems and lipid peroxidation in rats. *Ecotoxicol Environ Saf* 2009;72:905-8.
  13. Kalender S, Uzun FG, Durak D, Demir F, Kalender Y. Malathion induced hepatotoxicity in rats: the effects of Vit. C and E. *Food Chem Toxicol* 2010;48:633-38.
  14. Ambali SF, Shuaibu K, Edeh R, Orijei BC, Shittu M. Hyperglycemia induced by subchronic co-administration of chlorpyrifos and lead in Wistar rats: Role of pancreatic lipoperoxidation and alleviating the effect of vitamin C. *Biol Med* 2011;3:6-14.
  15. Heikal TM, El-Sherbiny M, Hassan SA, Arafa A, Ghanem HZ. Antioxidant effect of selenium on hepatotoxicity induced by chlorpyrifos in male rats. *Int J Pharm Sci* 2012b;4:603-9.
  16. Mogda K, Mansour Afaf AI, El-Kashoury MA, Koretem KM. Oxidative and biochemical alterations induced by profenofos insecticide in rats. *Nat Sci* 2009;7:1-15.
  17. Khan M, Kour G. Subacute oral toxicity of CPF and the protective effect of green tea extract. *Pest Biochem Phys* 2007;89:118-23.
  18. Aly AH, Debbab A, Kjer J, Proksch P. Fungal endophytes from higher plants: a prolific source of phytochemicals and other bioactive natural products. *Fungal Divers* 2010;41:1-16.
  19. Sekiwa Y, Kubota K, Kobayashi A. Isolation of novel glucosides related to gingerdiol from ginger and their antioxidative activities. *J Agric Food Chem* 2000;48:373-7.
  20. Sharma P, Singh R. Dichlorvos and lindane induced oxidative stress in rat brain: protective effects of ginger. *Pharmacogn Res* 2012;4:27-32.
  21. Mishra A, Kumar S, Bhargava A, Sharma B, Pandey AK. Studies on *in vitro* antioxidant and antistaphylococcal activities of some important medicinal plants. *Cell Mol Biol* 2011;57:16-25.
  22. Anilakumar KR, Saritha V, Khanum F, Bawa AS. Ameliorative effect of ajwain extract on hexachlorocyclohexane-induced lipid peroxidation in rat liver. *Food Chem Toxicol* 2009;47:279-82.
  23. Kubra IR, Rao LJM. Effect of microwave drying on the phytochemical composition of volatiles of ginger. *Int J Food Sci Technol* 2012;47:53-60.
  24. Ernst E, Pittler MH. Efficacy of ginger for nausea and vomiting: a systematic review of randomised clinical trials. *Br J Anaesth* 2000;84:367-71.
  25. Ahmed MA, Ahmed S. The protective effect of ginger (*Zingiber officinale*) against adriamycin-induced hepatotoxicity in rats: a histological study. *Life Sci* 2013;10:1412-22.
  26. Indian National Science Academy (INSA). Guidelines for the care and use of animals in scientific research reported by Indian National Science Academy, New Delhi; 2000.
  27. Ratnasooriya WD, Dharmasiri MG. Effects of *Terminalia catappa* seeds on sexual behaviour and fertility of male rats. *Asian J Androl* 2000;2:213-9.
  28. Prasad MRN, Chinoy NJ, Kadam KM. Changes in succinate dehydrogenase levels in the rat epididymis under normal and altered physiologic conditions. *Fertil Steril* 1972;23:186-90.
  29. Ohokawa H, Oshishi N, Yagi K. Assay for lipid peroxidation in animal tissues by the thiobarbituric acid reaction. *Anal Biochem* 1979;75:351-8.
  30. Clairborne A. Catalase activity. In: Greenwald RA. ed. *CRC Handbook of methods for oxygen radical research*. Boca Raton FL, USA: CRC Press; 1985. p. 283-4.
  31. Carlberg I, Mannervik B. Purification and characterization of the flavoenzyme glutathione reductase from rat liver. *J Biol Chem* 1975;250:5475-80.
  32. Das K, Samanta L, Chainy GBN. A modified spectrophotometric assay of superoxide dismutase using nitrite formation by superoxide radicals. *Indian J Biochem Biophys* 2000;37:201-4.
  33. Belanger A, Caron S, Picard V. Simultaneous radioimmunoassay of progestins, androgens and estrogens in rat testis. *J Steroid Biochem* 1980;13:185-90.
  34. Joshi SC, Tibrewal P, Sharma A, Sharma P. Evaluation of testicular toxicity of butachlor (a chloroacetanilide herbicide) in rats. *J Adv Sci Res* 2012;3:45-50.
  35. Sarkar M, Chaudhuri GR, Chattopadhyay A, Biswas NM. Effect of sodium arsenite on spermatogenesis, plasma gonadotrophins and testosterone in rats. *Asian J Androl* 2003;1:27-31.
  36. Bian Q, Qian J, Xu L, Chen J, Song L, Wang X. The toxic effects of 4-tert-octylphenol on the reproductive system of male rats. *Food Chem Toxicol* 2006;44:1355-61.
  37. Kamtchouing P, Fandio GYM, Dimo T, Jastra HB. Evaluation of androgenic activities of *Zingiber officinale* and *Pentadiplandra brazzeana* in male rats. *Asian J Androl* 2002;4:299-301.
  38. Jana K, Jana S, Samanta PK. Effect of chronic exposure to sodium arsenite on hypothalamopituitary-testicular activities in adult rats: possible an estrogenic mode of action. *Reprod Biol Endocrinol* 2006;4:91-6.
  39. Morakinyo AO, Achema PU, Adegoke OA. Effect of *Zingiber officinale* (ginger) on sodium arsenite-induced reproductive toxicity in Male Rats. *Afr J Biomed* 2010;13:39-45.
  40. Joshi SC, Sharma A, Chaturvedi M. Antifertility potential of some medicinal plants in males: an overview. *Int J Pharm Pharm Sci* 2011;3:204-17.
  41. Nwanjo HU, Iroagba IN, Nnatuanya IN, Eze NA. Antifertility activity of dihydro artemisinin in male albino rats. *Int J Endocrinol* 2007;4:3.
  42. Rasyidah TI, Suhana S, Nur-Hidayah H, Kaswandi MA, Noah RM. Evaluation of antioxidant activity of *Zingiber officinale* (Ginger) on formalin-induced testicular toxicity in rats. *J Med Bioeng* 2014;3:149-53.
  43. Sanocka D, Kurpisz M. Reactive oxygen species and sperm cells. *Reprod Biol Endocrinol* 2004;2:12.
  44. Hussein MSH, Abdou KHA, Mahmoud ASH, Abd-El-Rahman W. Toxic interaction of pyrethroid (Katron) and sodium fluoride on reproductive performance of male albino rats. *Assiut Vet Med J* 2008;54:219-41.
  45. Devi R, Boruah DC, Sharma DK, Kotoky J. Leaf extract of *Clerodendron colebrookianum* inhibits intrinsic hypercholesterolemia and extrinsic lipid peroxidation. *Int J Pharm Tech Res* 2011;3:960-7.
  46. Verma RS, Srivastava N. Effect of chlorpyrifos on thiobarbituric acid reactive substances, scavenging enzymes and glutathione in rat tissues. *Indian J Biochem Biophys* 2003;40:423-8.
  47. Olorunnisola OS, Bradley G, Afolayan AJ. Protective effect of *T. violacea* rhizome extract against hypercholesterolemia-induced oxidative stress in wistar Rats. *Molecules* 2012;17:6033-45.
  48. Prasanna GS, Purnima A. Protective effect of leaf extract of *Trichiliaconnaroides* on hypercholesterolemia-induced oxidative stress. *Int J Pharmacol* 2011;7:106-12.
  49. Shivarajashankara YM, Shivashankara AR, Bhat PG, Rao SH. Effect of fluoride intoxication on lipid peroxidation and antioxidant systems in rats. *Fluoride* 2001;34:108-13.

50. Yousef MI, Awad TI, Mohamad EH. Deltamethrin-induced oxidative damage and biochemical alterations in rat and its attenuation by vitamin E. *Toxicology* 2006;227:240-7.
51. Kant V, Srivastava AK, Verma PK, Raina R, Pankaj NK. Negligible ameliorative effect of aluminum sulphate on oxidative stress parameters in goats during subacute fluoride intoxication. *Fluoride* 2009;42:117-20.
52. Lee KW, Jeong YJ, Lim BJ, Chang YK, Lee SJ, Na KR, Shin YT, *et al.* Sildenafil I attenuates renal injury in an experimental model of rat cisplatin-induced nephrotoxicity. *Toxicology* 2009;257:137-43.
53. Ahmed MM, Zaki NI. Assessment the ameliorative effect of pomegranate and rutin on chlorpyrifos-ethyl-induced oxidative stress in rats. *Nat Sci* 2009;7:49-61.
54. Kose A, Gunay N, Kose B, Ocak AR, Erel O, Demiryurek AT. Effects of atropine and pralidoxime pretreatment on serum and cardiac oxidative stress parameters in acute dichlorvos toxicity in rats. *Pest Biochem Physiol* 2010;97:249-55.
55. Khalifa FK, Fatma A, Khalil-Heba A, Barakat-Marwa M, Hassan. Protective role of wheat germ and grape seed oils in CPF induced oxidative stress, biochemical and histological alterations in liver of rats. *Austral J Basic Appl Sci* 2011;5:54-66.
56. Morakinyo AO, Adeniyi OS, Arikawe AP. Effects of *Zingiber officinale* on reproductive functions in male rats. *Afr J Biomed Res* 2008;11:329-33.
57. Ahmed RS, Seth V, Banerjee BD. Influence of dietary ginger on antioxidant defence system in rat: comparison with ascorbic acid. *Indian J Exp Biol* 2000;38:604-6.
58. Sikka SC. Role of oxidative stress and antioxidants in andrology and assisted reproductive technology. *J Androl* 2004;25:5-18.
59. McLachlan RI, O'Donnell L, Meachem SJ, Stanton PG, De Kretser DM, Pratis K, *et al.* Identification of specific sites of hormonal regulation in spermatogenesis in rats, monkeys, and man. *Recent Prog Horm Res* 2002;57:149-79.
60. Whirledge S, Cidlowski JA. Glucocorticoids, stress, and fertility. *Minerva Endocrinol* 2010;35:109-25.
61. Kavlock R, Cumming A. Mode of action: inhibition of androgen receptor function vinclozolin, induced malformation in reproductive development. *Crit Rev Toxicol* 2005;35:721-6.
62. Reddy PS, Pushpalatha T, Reddy PS. Reduction in spermatogenesis and steroidogenesis in mice after fentin and fenbutalin administration. *Toxicol Lett* 2006;166:53-9.
63. Pareek TK, Joshi AR, Sanyal A, Dighe RR. Insights into male germ cell apoptosis due to depletion of gonadotrophin caused by GnRH antagonists. *Apoptosis* 2007;12:1085-100.

#### How to cite this article

- Bhawana Sharma, Priyanka Sharma, SC Joshi. Mitigating effects of *Zingiber officinale* against reproductive toxicity induced by dichlorvos in male rats. *Int J Pharm Pharm Sci* 2017;9(5):107-113.