

Original Article

**IN SITU ANTIBACTERIAL ACTIVITY OF KAEMPFERIA PANDURATA (ROXB.) RHIZOMES
AGAINST STAPHYLOCOCCUS AUREUS**

ELIN YULINAH SUKANDAR, IRDA FIDRIANNY, ANNISA KAMIL

School of Pharmacy, Pharmacology and Clinical Pharmacy Research Group, Bandung Institute of Technology, Ganesha 10, Bandung, Indonesia.
Email: ichakamil67@gmail.com

Received: 09 Nov 2014 Revised and Accepted: 02 Dec 2014

ABSTRACT

Objective: The aim of this study was to evaluate *in situ* antibacterial activity of topical preparations (ointment and cream) of ethanolic extract of fingerroot (*Kaempferia pandurata*) rhizomes against skin infection caused by *Staphylococcus aureus* in rabbits and determine the safety of topical preparations.

Methods: Skin infection in rabbits was induced by injecting the suspension of *S. aureus* bacteria intracutaneously on the back of rabbits. *In situ* antibacterial activity test was performed by giving the ointment and cream of 3% ethanolic extract of *Kaempferia pandurata* rhizomes, and 3% oxytetracycline hydrochloride ointment as standard antibiotic on the back of rabbits that had been injected by *S. aureus*. Furthermore, test preparations were given for 30 days. The observed parameters were diameter of erythema, edema thickness, and diameter of pus. Those parameters were calculated as the total score. Dermal and ocular irritation tests were carried out in order to assess the safety of topical preparations.

Results: *In situ* antibacterial activity test showed a total score of ointment of oxytetracycline HCl 3%, cream and ointment of 3% ethanolic extract was lower and significantly different ($P < 0.05$) with positive control. Macroscopically, skin infection on rabbits that were topically treated with ointment of oxytetracycline HCl 3%, cream and ointment of 3% ethanolic extract significantly healed earlier than positive control.

Conclusion: Cream and ointment of 3% ethanolic extract of *Kaempferia pandurata* rhizomes had *in situ* antibacterial activity against skin infection caused by *S. aureus* in rabbits. Cream of 3% ethanolic extract of fingerroot rhizomes had the strongest *in situ* antibacterial activity that was comparable with ointment of oxytetracycline HCl 3%. Ointment and cream of 3% ethanolic extract of fingerroot did not irritate the skin and eyes of rabbits.

Keywords: Antibacterial, Skin infection, *Staphylococcus aureus*, *Kaempferia pandurata*, *In situ*.

INTRODUCTION

Bacterial skin infections or pyoderma are common in most developing countries, including in Indonesia. The prevalence of skin diseases in developing countries is 10-70%. Low level of hygiene, including difficulties to get clean water, hot and humid climate, and overcrowding population are etiologic factors for bacterial skin infections [1]. One of the pathogenic bacteria that cause infections in humans, namely *Staphylococcus aureus*. *S. aureus* is one of the main causes of bacterial skin and soft tissue infections in the world. The prevalence of skin infections caused by *S. aureus* is high especially in nosocomial infections [2]. Skin infections caused by *S. aureus* are boils, impetigo, and wound infection that if left untreated can extend to other parts of the body and cause dangerous bacteremia.

Skin infectious disease is still a health problem in Indonesia, particularly among the low income society. Price of antibiotics that is relatively expensive is an obstacle for them to treat skin infections. Therefore, some of them using traditional medicine from plants. High prevalence of bacterial skin infections in low income society, the development of strains of *S. aureus* that is resistant to antibiotics, and treatment of skin infections with topical antibiotics which are relatively expensive, encourages scientists to search for new antimicrobial agents that are cheaper and effective. One alternative approach is to develop traditional medicine from medicinal plants into phytopharmaceuticals for treating bacterial skin infections. Up to now, there has been no phytopharmaceutical preparation to cure skin infections in Indonesia. There are some plants which have traditionally been used to treat skin infectious disease. One of medicinal plants that have potent antibacterial activity is *Kaempferia pandurata*.

Kaempferia pandurata or fingerroot is a ginger species that grows in Southeast Asia, Sri Lanka, India, and Southern Cina [3]. This species belongs to the family Zingiberaceae. The fresh rhizomes are utilized

to treat inflammatory disease, such as dermatitis, swelling, wounds, dry cough and cold, tooth and gum disease, dental caries, diarrhoea, dysentery, and as a diuretic [4,5]. Previous research reported that the rhizome ethanolic extract of fingerroot had *in vitro* antibacterial activity against *Staphylococcus aureus* with minimum inhibitory concentration (MIC) 4-16 $\mu\text{g/mL}$ [6].

Research on fingerroot rhizome is still around to testing *in vitro* antimicrobial activity of extract and isolates. However, *in situ* antibacterial activity of fingerroot rhizomes against *S. aureus* skin infections in rabbits model has not been investigated. There were no data regarding the skin infections healing effect of fingerroot rhizomes, and to confirm their traditional uses as a remedy for skin disease. This research will evaluate *in situ* antibacterial activity of topical preparations of rhizome ethanolic extract of fingerroot against skin infection caused by *S. aureus* in rabbits model and determine the safety of topical preparations. The benefit expected from this study is to get the raw material for phytopharmaceuticals from plants in Indonesia and to encourage the development of phytopharmaceutical preparations of fingerroot rhizome, especially for treatment of minor skin infections caused by *S. aureus* that can be used as a cheaper alternative medicine which safe and effective.

MATERIALS AND METHODS

Materials

Mueller Hinton Agar (MHA) and Mueller Hinton Broth (MHB) (Oxoid Ltd., Hampshire, England) were used as growth media for bacteria. Ointment of oxytetracycline HCl 3% as standard antibiotic was purchased from Kimia Farma, Indonesia.

Plant collection and identification

Fresh rhizomes of *Kaempferia pandurata* were collected from the garden in Tanjungkerta village, Sumedang, Indonesia. Determination

of plant was performed in Bandungense Herbarium [7-10], School of Life Sciences and Technology, Bandung Institute of Technology. Fresh rhizome was sorted, washed, chopped, and dried using oven (WTB binder) with temperature 40-45°C for several days. Dried rhizome then be grounded into a fine powder.

Chemicals

All the chemicals used throughout this study were of technical grade. Ethanol 96%, yellow soft petrolatum, liquid paraffin, cetostearyl alcohol, and cetomacrogol 1000 were obtained from School of Pharmacy, Bandung Institute of Technology.

Test microorganism and culture

Test microorganism was *Staphylococcus aureus* that was obtained from the culture collection of School of Pharmacy, Bandung Institute of Technology. *S. aureus* was cultured aerobically in MHA and MHB medium.

Preparation of extract

The crude drug of fingerroot rhizomes extracted by reflux using ethanol 96% as solvent. The ethanol extract was filtered by filter paper (Whatman No. 1) and concentrated by rotary evaporator (Buchi R-125) to obtain viscous extract. The viscous extract was stored at room temperature protected from sunlight.

Phytochemical screening of rhizome ethanolic extract

The rhizome ethanolic extract of fingerroot were subjected to preliminary phytochemical screening for plant constituents, including examination of alkaloid, flavonoid, quinone, tannin, saponin, and steroid/triterpenoid [11].

Determination the susceptibility of bacteria

In vitro susceptibility tests were performed in a 96-well microtiter plate to determine minimum inhibitory concentrations (MICs) of rhizome ethanolic extract of fingerroot and tetracycline HCl against *S. aureus* using standard Broth microdilution methods with an inoculum of 5×10^5 CFU/mL, according to the guidelines of CLSI standard M7-A8 [12]. The MIC was defined as the lowest concentration of antimicrobial agent that resulted in the complete inhibition of visible growth.

Minimum bactericidal concentrations (MBCs) were established for each test sample. Briefly, medium (approximately 100 μ L) from each well showing no visible growth was spread onto MHA plates. Plates were incubated at 37°C for 24 hours or until growth was seen in the growth-positive control plates. MBC was defined as the lowest concentration of antimicrobial agent at which all bacteria in the culture are killed or the lowest concentration of drug that kills 99.9% of the total initially viable cells [13].

Topical preparation of ethanolic extract of fingerroot rhizome

Topical preparations were ointment and cream of 3% ethanolic extract of fingerroot rhizome. Three grams of viscous ethanolic extract of fingerroot rhizome were dissolved in ethanol 96% and used as an active substance. Occlusive ointment preparations were made with the following formula: 3% ethanolic extract of fingerroot rhizome, 92% yellow soft petrolatum, and 5% liquid paraffin. Bases that containing yellow soft petrolatum and liquid paraffin both melted in a water bath.

The melted base was poured into the ethanolic extract in the mortar, then stirred homogeneously until form semisolid mass. Oil/water cream preparations were made with the following formula: 3% ethanolic extract of fingerroot rhizome, 25% yellow soft petrolatum, 10% liquid paraffin, 4% cetostearyl alcohol, 1% cetomacrogol 1000, and distilled water ad 100%. Oil phases that consisting of liquid paraffin, yellow soft petrolatum, and cetostearyl alcohol were heated to a temperature of 70°C, and the water phases consisting of cetomacrogol 1000 and distilled water were heated to a temperature of 70° C. At the same temperature, the both phases immediately poured into a mortar, then stirring to form semisolid mass. Once cool, the base added to the ethanolic extract, and mixed until homogeneous.

Experimental animals

Healthy young adult male New Zealand albino rabbits were obtained from rabbit husbandry in Lembang, Indonesia. The rabbits were divided randomly into 3 groups of 3 rabbits each. Each rabbit that weighted between 1.5-2.5 kg (8 weeks old) was housed individually (one rabbit per cage). The animals were fed with standard pellet diet, fresh vegetables (carrot, cabbage), and tap water. The study complied the rules of animal handling and experimentation of School of Pharmacy, Bandung Institute of Technology. Throughout the experiments, all animals received human care according to the criteria outlined in the "Institutional Animal Care and Use Committee Guidebook" [14].

Experimentally induced skin infection

Prior to testing, acclimatization of rabbits was conducted in the laboratory for 1 week. Experimental rabbits were shaved at the back without abrading the skin. The hair over both side of back for each rabbit was clipped short with hair scissors, then completely removed with an electrical hair remover. This depilation was carried out several days before the rabbits were inoculated by the test bacteria. After the hair had been shaved, selection the site of infection was done in one region each in the right and left on the back of rabbits with the distance of each region was \pm 5 cm. By using 70% ethanol to disinfect the inoculation area (two regions), waiting five minutes until the evaporation of ethanol. A 0.1 mL suspension of *S. aureus* bacteria aged 18-24 hours with 25% transmittance at λ 530 nm (containing 10^8 CFU/mL of bacteria) in MHB solution was injected intracutaneously into each region of rabbits by a tuberculin syringe and a 23.5 gauge needles. Rabbits that had been inoculated by bacteria were then left for 24 hours. Application of topical preparations were made after 24 hours infected.

Topical application of skin infection

In each rabbit, one region on the right back served as test (application of cream or ointment of 3% ethanolic extract of fingerroot rhizome, or ointment of oxytetracycline HCl 3%), while the other region on the left back served as positive control (without treatment). Skin infections in group 1 animal were topically treated once daily with 0.5 g ointment of 3% ethanolic extract of fingerroot rhizome. Skin infections in group 2 were topically treated once daily with 0.5 g cream of 3% ethanolic extract of fingerroot rhizome. Skin infections in group 3 were topically treated once daily with 0.5 g ointment of oxytetracycline HCl 3% as a reference standard. To avoid contamination and infection by other bacteria, the infection site was dressed with sterile gauze. Furthermore, observation and treatment with the test preparations were conducted daily until the skin infection healed (30 days long).

Estimation of skin infection healing

Rabbits were examined daily for the development of macroscopic skin lesions. The observed parameters were diameter of erythema, edema thickness, and diameter of pus. The parameters were measured manually by calipers and calculated in millimeters. Observations included healing skin infection characterized by reduced erythema, edema, and pus in the rabbits. Evaluation of parameters were graded into the score as following below.

Erythema score: 0 = no erythema; 1 = very mild erythema (diameter \leq 10.00 mm); 2 = mild erythema (diameter between 10.01 to 20.00 mm); 3 = moderate erythema (diameter between 20.01 to 30.00 mm); 4 = severe erythema (diameter between 30.01 to 40.00 mm); 5 = very severe erythema (diameter > 40.00 mm).

Edema score: 0 = no edema; 1 = very mild edema (thickness \leq 0.10 mm); 2 = mild edema (thickness between 0.11 to 0.20 mm); 3 = moderate edema (thickness between 0.21 to 0.30 mm); 4 = severe edema (thickness between 0.31 to 0.40 mm); 5 = very severe edema (thickness > 0.40 mm).

Pus score: 0 = no pus; 1 = very mild pus (diameter \leq 10.00 mm); 2 = mild pus (diameter between 10.01 to 20.00 mm); 3 = moderate pus (diameter between 20.01 to 30.00 mm); 4 = severe pus (diameter between 30.01 to 40.00 mm); 5 = very severe pus (diameter > 40.00 mm).

Evaluation the safety of topical preparations

The safety of topical preparations was examined by determining the primary irritation index on the back's skin and ocular irritation index on the eyes of rabbits.

Acute dermal irritation test / primary irritation test

In this test, at least three healthy albino rabbits were used. Before the test, hair should be removed by closely clipping the dorsal area of the trunk of the rabbits without abrading the skin. Rabbits were allowed to stand for 24 hours before used. A total of 0.5 g of ointment and cream preparations that containing of 3% ethanolic extract of fingerroot rhizome were applied to a small area (approximately 6 cm²) of skin on the back and covered with a gauze patch, which is held in place with non-irritating tape (micropore). In each rabbit, one region on the right back used as control (not given the test preparations), while the other region on the left back served as test. Skin exposed for 4 hours of test preparations. After 4 hours of exposure, the test preparations were removed from the skin using water. All animals were examined for signs of erythema and edema, and the response scored at 1, 24, 48, and 72 hours after patch removal. Dermal reactions were graded and recorded according to the grades in OECD [15].

Ocular irritation test

Animals at least three albino rabbits were used. Ointment and cream preparations of not more than 100 mg were respectively placed in the conjunctival sac of one eye of each animal. The lids are then gently held together for about one second in order to prevent loss of the material. The other eye, which remains untreated, serves as control. At 24 hours, a washout may be used if considered appropriate. Observations were done after 1, 24, 48, and 72 hours after application of the material. Furthermore, assessment of the response occurs by calculating the score of the cornea, iris, conjunctiva, and chemosis [16].

Statistical analysis

The data obtained were analyzed using the Statistical package for the Social Sciences (SPSS) version 18. All values are reported as

mean \pm SEM (Standard Error Mean) and the statistical significance of differences among groups were assessed using one-way ANOVA with post-hoc Tukey LSD (Least Significance Difference). Value of $P < 0.05$ was considered significantly different.

RESULTS

Phytochemical screening of rhizome ethanolic extract

Preliminary phytochemical screening of rhizome ethanolic extract of fingerroot showed the presence of flavonoids and steroid/triterpenoids.

Determination the susceptibility of bacteria

In vitro antibacterial activity of rhizome ethanolic extract of fingerroot was investigated in terms of minimum inhibitory concentration (MIC) and minimum bactericidal concentration (MBC) compared with commercially available standard antibiotic (Tetracycline HCl). MIC and MBC of rhizome ethanolic extract against *S. aureus* were 64 and 256 $\mu\text{g}/\text{mL}$, respectively. The MIC and MBC for tetracycline HCl against *S. aureus* were 0.5 and 16 $\mu\text{g}/\text{mL}$, respectively.

In situ antibacterial activity of topical preparations

In situ antibacterial activity test of topical preparations of rhizome ethanolic extract of fingerroot had been done on rabbits to complete *in vitro* antibacterial activity test against *S. aureus*. Skin infection in rabbits induced by injecting *S. aureus* intracutaneously (local) as much as 0.1 mL to the back's skin of rabbits that have been sheared. In this study, each topical preparations using three rabbits.

Each rabbit was injected on the right (positive control, no treatment) and left (treated with topical preparation) back. In this test, only used two test sites of infection of each rabbit. Test preparations were given 24 hours after injection. Parameters observed were diameter of erythema (reddening), edema thickness, and diameter of pus. The observation of these parameters had been conducted for 30 days. The results obtained were made in the form of score of total parameters, then processed by one way analysis of variance (ANOVA) followed by LSD.

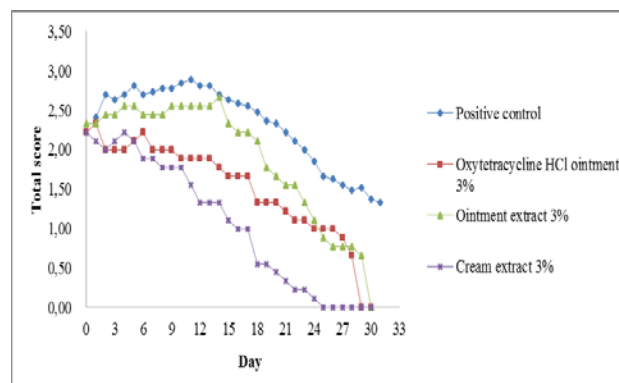


Fig. 1: It shows effect of topical application on decrease the total score of skin infection in rabbits for 30 days

Table 1: It shows total score of topical preparations on skin infection in rabbits that significantly different

Day	Total Score (Score of diameter erythema + edema thickness + diameter of pus)			
	Positive control	Oxytetracycline HCl ointment 3%	Ointment extract 3%	Cream extract 3%
0	2.41 \pm 1.12	2.22 \pm 1.30	2.33 \pm 1.22	2.22 \pm 1.20
4	2.81 \pm 1.04	2.00 \pm 0.50*	2.56 \pm 1.01	2.22 \pm 0.83
6	2.74 \pm 1.02	2.22 \pm 0.83	2.44 \pm 1.01	1.89 \pm 1.05*
23	1.85 \pm 1.03	1.11 \pm 0.93	1.33 \pm 1.00	0.22 \pm 0.44**
25	1.63 \pm 1.04	1.00 \pm 0.87	0.89 \pm 0.78*	0.00 \pm 0.00*

Note: Values expressed as means \pm SEM of 3 experimental animals in each group, Day 0 = observation after 24 hours of infection, before the treatment with topical preparations, * = Significantly different ($P < 0.05$) with positive control, ** = Significantly different ($P < 0.05$) with oxytetracycline HCl ointment 3%.

Fig. 1 demonstrated that oxytetracycline HCl ointment 3%, cream and ointment of 3% ethanolic extract of *Kaempferia pandurata* rhizomes had lower total score than positive control.

They could decrease the total score of skin infection. Low total score means that they had the low score of erythema, edema, and pus. Table 1 showed that on day 4 of treatment, the total score of oxytetracycline HCl ointment 3% was lower and significantly different ($P < 0.05$) with positive control. Total score of cream extract 3% was lower and significantly different ($P < 0.05$) with positive control on day 6 of treatment, and significantly different ($P < 0.05$) with 3% oxytetracycline HCl ointment on day 23 of treatment. Ointment of extract 3% had significantly different ($P < 0.05$) with positive control on day 25 of treatment. Based on analysis of the total score of the parameters, oxytetracycline HCl ointment

3% had the most rapid decrease in total parameters in the first 4 days of treatment which indicated by significantly decrease of diameter of erythema, edema thickness, and diameter of pus.










However, after 4 days of treatment with oxytetracycline HCl ointment 3%, the decrease of the total score was relatively constant and slower than cream extract 3%. Cream extract 3% decreased the total parameters quickly. On day 23 of treatment, the total score of cream extract 3% was lower and significantly different ($P < 0.05$) with oxytetracycline HCl ointment 3%. Meanwhile, ointment of extract 3% lessened the total score of skin infection slowly. This suggested that cream of extract 3% has more effective antibacterial activity than ointment of oxytetracycline HCl 3% in overcoming skin infections caused by *S. aureus* in rabbits.

Table 2: It shows effect of topical application on healing time of skin infection in rabbits

Average Healing Time (Days)			
Positive control	Oxytetracycline HCl ointment 3%	Ointment extract 3%	Cream extract 3%
33.11 ± 7.54	18.00 ± 0.00	26.00 ± 2.65	17.00 ± 1.73

Note: Values expressed as means ± SEM of 3 experimental animals in each group

Table 3: It shows healing pattern of skin infection by topical preparations in rabbits

Day	Positive control	Oxytetracycline HCl ointment 3%	Ointment extract 3%	Cream extract 3%
0				
6				
25				

Furthermore, table 3 exhibited that the pattern of skin infections healing by topical preparations include reduction in the intensity and diameter of erythema, thickening and drying of pus accompanied by edema, pus diameter shrinkage, peeling of dried pus, and reduction in the thickness of edema, and eventually erythema, edema, and the pus were gone, and the area around the skin infection fledged that indicating the infection has been cured.

As shown in table 2, the most rapid healing time of skin infection caused by *S. aureus* in rabbits occurred in the region that was given by cream extract 3% compared with oxytetracycline HCl ointment and ointment of extract. Cream of extract 3% significantly enhanced the acceleration of skin infections healing in rabbits.

Acute dermal/primary irritation and ocular irritation test

Acute dermal irritation test on the skin and ocular irritation test on the eyes of rabbits are very important to ensure the safety of topical preparations. This is to establish whether such preparations are irritating or not. Test method refers to the OECD [15,16]. Result of primary irritation test showed that score of Index Irritation Primer (IIP) = 0. This indicated that both the ointment and cream of rhizome ethanolic extract 3% were not irritating the skin of rabbits. Result of ocular irritation test performed that score of Index Irritation Ocular (IIO) = 0. This indicated that both the ointment and cream of rhizome ethanolic extract 3% were not irritating the eyes of rabbits. Ointment and cream extract 3% did not show any irritation on the skin and eyes compared with the control group.

DISCUSSION

The skin serves a first line of defense against a wide range of bacterial invaders. When the integrity of the skin is compromised, its natural defenses weaken and a role for antibacterial agents emerges. The presence of moisture and skin trauma are mostly important factors in the pathophysiology of cutaneous infections [17]. *Staphylococcus aureus* is the main cause of skin and soft tissue infection, including folliculitis, furuncles, carbuncles, impetigo, and skin abscesses. Topical antibiotics can be used to treat localised skin bacterial infections such as impetigo, folliculitis, furunculosis (boils), carbuncles, and other minor skin infections. Topical antibiotic agents are available in a variety of dosage forms mainly as creams, ointments, powders, and dressings. The topical route offers several advantages, including the avoidance of systemic toxicity and side effects, the decreased induction of bacterial resistance, and the high concentration of antibacterial agent at the site of infection [18]. In this study, topical antibacterial preparations were made from ethanolic extract of fingerroot rhizome.

Fingerroot rhizome contain many compounds, ranging from the flavonoid derivatives, chalcone derivatives, esters, terpenes, and terpenoids [3]. These compounds have shown to exhibit great medicinal potential. One of compounds that had been isolated and showed a potent *in vitro* antimicrobial activity against many bacteria was panduratin A [19-23]. Panduratin A, a natural chalcone compound isolated from the rhizomes of fingerroot has been reported to possess *in vitro* antibacterial activity against many bacteria. Panduratin A has also been reported to have strong *in vitro* antimicrobial activity against clinical *Staphylococcus* strains [20].

In this study, topical preparations (ointment and cream) were made with extract concentration of 3%. This concentration was chosen based on the dose of commercially available tetracycline HCl ointment in the market that is 3%. At a dose of 3%, rhizome ethanolic extract of fingerroot had bactericidal activity against *S. aureus* (MBC 256 µg/mL). This is important due to the use of topical antibiotics, the active substance must be bactericidal to avoid development of bacterial resistance. Ointment of oxytetracycline HCl was used as standard topical antibiotic against skin infection. Topical use in the form of ointment 3% (application 1 or 2 times a day) is utilized to treat mild to moderate acne that characterized by inflammatory lesions such as papules and pustules. Tetracycline HCl topical (ointment) is designed to treat minor skin infections caused by *Staphylococcus* and *Streptococcus* [24].

There was one positive control and one test region in each rabbit. Observation of skin infection on the test region (treatment with topical preparations) was compared with positive control (without treatment) in the same rabbit. This is explained by the fact that there is a difference of immune response of each rabbit so it will avoid a high intervariability of rabbits. Rabbits that had been induced by *S. aureus* suffered skin infection 24 hours after injection. Macroscopic manifestations of *S. aureus* skin infections such as boils which indicated by erythema and swelling (edema) that contains pus. The characteristic feature of *S. aureus* skin infections is abscess formation. The basic lesion consists of inflammation and leukocyte infiltration [25]. *S. aureus* is more pathogenic when equipped with enzymes and toxins that can protect itself against host defense. In this study, many factors affected the healing time of skin infections. There were virulence factor of *S. aureus*, immune response of each rabbit, the giving interval of topical application, and stability of topical preparations. Cream of 3% rhizome ethanolic extract of fingerroot had the strongest *in situ* antibacterial activity against skin infection caused by *S. aureus* in rabbits. It was indicated by the most rapid healing time among the other test preparations. There was a difference between skin infections healing time by cream and ointment of extract and ointment of oxytetracycline HCl. Cream would be easier to release the active compounds from its base because the active compounds were not held firmly on the base, while ointment would be more difficult to release the active compounds because of polarity similarities of active compounds and base retained active compounds strongly in the base. This assumption would be valid if the active compounds that have antibacterial activity are lipophilic. Healing time of *S. aureus* skin infections by cream extract 3% was almost comparable with oxytetracycline HCl ointment 3%. As we know that biological activities of plant extract are complex. Hence, the antimicrobial effect may be attributed to the complex pharmacological action of phytoconstituents present in the extract. Extract of fingerroot have many antibacterial compounds that may be acted together to optimize their antimicrobial activities. It is supposed that cream of 3% extract of fingerroot has better penetration and release of the active antibacterial compounds into the skin than oxytetracycline HCl ointment 3%. It is important to note that throughout the period of skin infection treatment, topical preparations of rhizome ethanolic extract of fingerroot did not cause irritation to the animals. Irritation tests on the skin and eyes of rabbits were conducted to ensure the safety of test preparations.

CONCLUSION

Cream and ointment of 3% ethanolic extract of *Kaempferia pandurata* rhizome had *in situ* antibacterial activity against skin infection caused by *S. aureus*. Skin infection treated with cream of

3% ethanolic extract of fingerroot significantly healed earlier than those treated with ointment of oxytetracycline HCl 3% and ointment of extract 3%. Ointment and cream of 3% fingerroot extract did not irritate the skin and eyes of rabbits. Our present documented findings may suggest the development of rhizome ethanolic extract of fingerroot as phytopharmaceuticals to treat minor bacterial skin infection caused by *S. aureus*.

ACKNOWLEDGEMENT

The authors wish to thank to Directorate General of Higher Education (DGHE) Indonesia.

CONFLICT OF INTEREST

Declared None

REFERENCES

1. World Health Organization. Epidemiology and Management of Common Skin Disease in Children in Developing Countries. Discussion Papers on Child Health; 2005. p. 5-12.
2. Danziger LH, Fish DN, Pendland SL. Skin and Soft Tissue Infections. In: Dipiro JT, Talber RL, Yee GC, Matzke GR, Wells BG, Posey LM. Pharmacotherapy: A Pathophysiologic Approach. 7th ed. United States: The McGraw-Hill Companies Inc; 2008. p. 1801-8.
3. Chong TE, Kee LY, Fei CC, Han HC, Ming WS, Ping CT, et al. *Boesenbergia rotunda*: from ethnomedicine to drug discovery. a review. Evid Based Complement Alternat Med 2012;1-25.
4. Chuakul W, Boonpleng A. Ethnomedicinal uses of Thai zingiberaceous plant. J Med 2003;10(1):33-9.
5. Salguero CP. A Thai Herbal. In: Borton L. Traditional Recipes For Health and Harmony. Scotland: Findhorn Press; 2003.
6. Sukandar EY, Sunderam N, Fidrianny I. Antimicrobial activity of *kaempferia pandurata* (Roxb.) rhizome ethanol extract against MRSA, MRCNS, MSSA, *Bacillus subtilis*, and *Salmonella typhi*. Pak J Biol Sci 2014;17(1):49-55.
7. Backer CA, Bakhuijzen VDB, Jr RC. Flora of Java. Vol III. Groningen, The Netherlands: Wolters-Noordhoff NV; 1986. p. 69.
8. Ibrahim H, Nugroho A. *Boesenbergia rotunda* (L.) Mansfeld. In: de Guzman CC, Siemonsma JS, editors. Plant Resources of Southeast Asia. No 13. Leiden, The Netherlands: Spices Backhuys Publisher; 1999. p. 83-5.
9. Sastrapradja S. Ubi-ubian. Proyek Sumber Daya Ekonomi. Bogor: Lembaga Biologi Nasional (LIPI); 1977. p. 82-3.
10. Cronquist A. An Integrated System of Classification of Flowering Plants. New York: Columbia University Press; 1981. p. 8-18.
11. Farnsworth NR. Biological and phytochemical screening of plants. J Pharm Sci 1966;55(3):225-76.
12. Clinical and Laboratory Standards Institute (CLSI). Methods for Dilution Antimicrobial Susceptibility Tests for Bacteria That Grow Aerobically. Approved Standard M07-A8. 8th ed., Wayne, Philadelphia: National Committee for Clinical Laboratory Standards; 2010. p. 15-8.
13. Michael JR, Jeffrey RA. Laboratory Tests to Direct Antimicrobial Pharmacotherapy. In: Dipiro JT, Talber RL, Yee GC, Matzke GR, Wells BG, Posey LM. Pharmacotherapy: A Pathophysiologic Approach. 7th ed. United States: The McGraw-Hill Companies Inc; 2008. p. 1715-25.
14. Office of Laboratory Animal Welfare (OLAW). Institutional Animal Care and Use Committee Guidebook. 2nd ed. National Institutes of Health: Applied Research Ethics National Association (ARENA); 2002.
15. OECD. Acute Dermal Irritation/Corrosion. In: OECD Guideline For The Testing of Chemicals. Paris: OECD; 2002. p. 1-13.
16. OECD. Acute Eye Irritation/Corrosion. In: OECD Guideline For The Testing of Chemicals. Paris: OECD; 2012. p. 1-19.
17. Nicholas AS, Howard PB. Pathophysiology of Dermatologic Diseases. United States: McGraw-Hill Inc; 1984. p. 351-5.
18. Robert AS, Nawar AM. Topical Antibiotics in Dermatology, an Update. GJDF 2010;17(1):1-19.
19. Hwang JK, Rukayadi Y, Han S, Yong D. *In Vitro* antibacterial activity of panduratin a against *enterococci* clinical isolates. Biol Pharm Bull 2010;33(9):1489-93.
20. Hwang JK, Rukayadi Y, Lee K, Han S, Yong D. *In vitro* activities of panduratin a against clinical *staphylococcus* strains. Antimicrob Agents Chemother 2009;53(10):4529-32.

21. Hwang JK, Lee KH, Yanti Rukayadi Y. Activity of panduratin a isolated from *kaempferia pandurata* roxb. against multi-species oral biofilms *in vitro*. J Oral Sci 2009;51(1):87-95.
22. Hwang JK, Park KM, Lee SH, Choo JH, Sohn JH. Antibacterial activity of panduratin a isolated from *kaempferia pandurata* against *porphyromonas gingivalis*. Food Sci Biotechnol 2005;14(2):286-9.
23. Hwang JK, Chung JY, Park JH, Baek NI. Isopanduratin a from *kaempferia pandurata* as an active antibacterial agent against cariogenic *streptococcus mutans*. Int J Antimicrob Agents 2004;23:377-81.
24. Sweetman SC. Martindale The Complete Drug Reference. 36th ed. London: Pharmaceuical Press; 2009. p. 347-50.
25. Lowy FD. *Staphylococcus aureus* Infections. New Engl JMed 1998;526-7.