

ACUTE TOXICITY STUDY OF ARSENICUM ALBUM IN WISTAR ALBINO RATS

MONISHA A.¹, BHUVANESHWARI S.², VELARUL S.³, SATHIYA VINOTHA A. T.^{4*}, UMAMAGESWARI M. S.⁵, VIJAYAMATHY A.⁶, KARTHIKEYAN T. M.⁷

^{1,2,4,5,7}KMCH Institute of Health Sciences and Research, Coimbatore, Tamil Nadu, India. ³Swamy Vivekanandha Medical College and Hospital, Thiruchengode, Namakkal, Tamil Nadu, India. ⁶Karuna Medical College, Palakkad, Kerala, India

*Corresponding author: Sathiya Vinotha A. T.; *Email: drs.vinothaph@gmail.com

Received: 29 Aug 2024, Revised and Accepted: 11 Oct 2024

ABSTRACT

Objective: In India, homeopathic medicines derived from arsenic trioxide, such as Arsenicum album (A. album), are used to treat COVID-19. Many of the Arsenicum album's adverse events during the COVID treatment led to drug discontinuation. Nonetheless, Ayurvedic, Yoga and Naturopathy, Unani, Siddha, and Homoeopathic (AYUSH) medicine prescribes it. Researching Arsenicum album's toxicity is now essential since it will help decide whether or not the drug can be utilized during treatment.

Methods: Acute oral toxicity was performed in Wistar Albino Rats to find out the effects of Arsenicum album in various organs. Rats were divided into three groups: Group A (control), Group B (Arsenicum album 1000µl/100g) and Group C (2000µl/100g). A Single bolus dose of Arsenicum album was given orally and the study period was conducted for 14 d. The rats were subsequently sacrificed on the 15th d and biochemical and histopathological studies were done.

Results: The acute oral toxicity study showed median Lethal dose (LD50) was greater than 2000µl/100g for Arsenicum album. Biochemical analysis showed a significant increase in HDL level in Group C (2000µl/100g) compared to Group A (control) and Group B (1000µl/100g). [P<0.05]. Blood glucose, when compared to Group A (control) is increased in both groups B and C but statistically not significant (p>0.05). When compared to Group A (control) there is no significant change in blood urea level in Groups B and C (p>0.05). Serum creatinine is increased in Groups B and C compared to Group A (control) but statistically not significant (p>0.05). LDL cholesterol is increased in groups B and C compared to Group A (control) but statistically not significant (p>0.05). Macroscopic examination of the organs of Group B and C revealed no abnormalities when compared with the organs of Group A (control). Histopathological analysis showed mild hepatocellular and renal toxicity in Groups B and C with extensive hemorrhages and periportal lymphocytic infiltrates.

Conclusion: Arsenicum album is a homeopathic remedy that causes fibrous healing of lung tissue and it also causes mild hepatocellular and renal toxicity. Further elaborative experimental analysis of chronic toxicity study is needed to support the findings.

Keywords: Arsenicum album, Acute toxicity, Covid, Herbal medicine

© 2024 The Authors. Published by Innovare Academic Sciences Pvt Ltd. This is an open access article under the CC BY license (<https://creativecommons.org/licenses/by/4.0/>) DOI: <https://dx.doi.org/10.22159/ijpps.2024v16i12.52513> Journal homepage: <https://innovareacademics.in/journals/index.php/ijpps>

INTRODUCTION

The use of herbal medicine as a form of healthcare has increased. Nevertheless, even though there are some differences between herbal and conventional pharmaceutical treatments, herbal medicine still needs to be evaluated for efficacy using the traditional trial methodology, even though some specific herbal extracts are useful for treating particular conditions [1]. Homeopathy is based on two main principles [2]. According to the "like cures like" hypothesis, patients with specific symptoms can benefit from taking a homeopathic medication that produces those same symptoms in healthy people. The second principle asserts that after repeated dilution and succussion, homeopathic remedies retain biological action even at concentrations greater than Avogadro's number [3, 4]. It is commonly known that yoga and traditional medicine can be used in public health to prevent Coronavirus Disease-19 (COVID-19) [5].

The most recent pandemic, the new coronavirus, originated in Wuhan, China, and has since spread to sixteen nations, including Thailand, France, the Philippines, Australia, and India. The COVID-19 epidemic claimed many lives as a result of infection [6]. Two recommendations on treatment and prevention strategies for the coronavirus outbreak were issued by the Indian Ministry of AYUSH. One of the recommendations is to use Arsenicum album 30C, a homeopathic medication, as a "prophylactic medicine" to avoid infection [7]. When it comes to animal and bacterial cells, arsenic compounds are mild mutagens. On the other hand, in animal cells, they have been shown to cause clastogenic and aneugenic effects, as well as gene amplification, cellular transformation, DNA cross-links, and DNA strand breakage [8].

The homeopathic process of succussion and dilution is used to create a potentized medicine known as Arsenicum Album of different centesimals (6X, 12X, 30C, 200C) from arsenic trioxide solution. Rats were given a single intraperitoneal dosage of 0.004% arsenic trioxide at a rate of 1 ml/100 g of body weight. The effects of this dose on cytogenetic and biochemical changes were examined. Previous studies have shown that these compounds may be able to effectively mitigate the toxicity that rats experience from arsenic trioxide [9, 10].

Moreover, Arsenicum album (30C) reduced oxidative stress markers and DNA damage while increasing cell viability and antioxidant enzymes in *Saccharomyces cerevisiae* exposed to arsenate. These studies show the antioxidant, anti-inflammatory, anti-cytotoxic, and DNA-repairing properties of Arsenicum album. It may, therefore, be effective in treating a variety of human illnesses [11]. Furthermore, considering its extensive history of usage and medicinal advantages, the Ministry of AYUSH recommended Arsenicum Album as a preventive drug during the COVID-19 Pandemic based on the idea of Genus epidemics among the populace. However, there is evidence that homeopathic medicines have been turned down despite the potential for their pharmacological effect because to inadequate safety profile. Many patients were forced to discontinue taking the medication as a result of the numerous side effects shown in this Arsenicum album during the COVID treatment.

It is still advised in AYUSH medication, nevertheless. Researching Arsenicum album's toxicity is now essential since it will assist decide whether or not the drug may be utilized to treat COVID-19. The acute oral toxicity of Arsenicum album will be evaluated in this

study using wistar albino rats in terms of biochemical markers, gross organ changes, and histological abnormalities.

MATERIALS AND METHODS

Wistar albino rats approximately weighing 150-300 g were purchased from Biogen laboratories, Bangalore. Animals were housed in standard cages with sawdust as bedding and they were fed with a standard diet and water ad libitum. Rats were exposed to a 12 h light/dark cycle at room temperature. The rats were handled in accordance with the standard guidelines for the care and use of laboratory animals (CPCSEA guidelines). Rats were acclimatized to the above-mentioned conditions for one week prior to the toxicity studies. Ethical approval was obtained from the Institutional Animal Ethics Committee (Approval No. 04/IAEC/2022). All the experiments were conducted under the supervision of the veterinarian before commencing the animal study.

Methods

Inclusion and exclusion criteria

Only healthy rats were included in the study. Rats who developed illness during acclimatization were excluded from the study.

Drugs

Arsenicum album 6X was purchased from the local pharmacy. Dose calculation of Study drugs calculated as per advice by Central Council for Research in Homeopathy (CCRH), Ministry of AYUSH, Govt. of India, New Delhi. The drug was administered orally. The Vehicle for administration is De-ionized water Standard dose of 2000 µl/100g was recommended for acute toxicity study (single bolus dose) [12].

Acute oral toxicity

Acute oral toxicity study of Arsenicum album were performed using wistar albino rats according to the Organization for Economic Co-operation and Development (OECD) guidelines 423. A total of 18 female Wister albino rats weighing about 150-300 g were used for the study. The animals were randomly divided into 3 groups (A, B and C) each containing 6 rats (n=6). Blinding was done at the time of allocation and during data handling. All the drugs were administered orally using an appropriate gavage needle. A Sample size of six in each group was decided for a power of 85 percent statistical significance.

Group A-6 Control animals were administered with distilled water 0.5 ml/kg.

Group B-6 animals were administered Arsenicum album 6X 1000µl/100g body weight orally.

Group C-6 animals were administered Arsenicum album 6X 2000µl/100g body weight orally [13].

The rats of all groups were maintained under the same conditions (temperature, humidity, light) with normal food and water to avoid the influence of confounding factors in the study. They were observed individually for the first critical 4 h and thereafter twice daily (every day at 9.00 am and 3.00 pm) during the study period (14 d) for mortality, signs of toxicity (changes in the skin, fur, eyes, mucus membranes, respiratory depression) and behavioral changes (salivation, diarrhea, sleep, coma, lethargy). Further, body weight changes food and water intake were also recorded during the study period. On the 14th d, all the rats were kept fasting overnight. On the 15th d, they are weighed and sacrificed by overdose inhalation of the anesthetic ether. Samples were collected for biochemical analysis (serum glutamic oxaloacetic transaminase, serum glutamate pyruvate transaminase, blood glucose, blood urea nitrogen (BUN), serum creatinine, triglycerides, and LDL, HDL). This was followed by histopathological studies (kidney, liver, brain, ovary, and heart) [14, 15].

Statistical analysis

ANOVA was used to calculate the comparison between groups, followed by Dunnett's multiple comparison tests. $p < 0.05$ was considered statistically significant. All data were represented as mean \pm SEM. Statistical analysis was performed using SPSS version 26.0.

RESULTS

In the acute toxicity study, we observed no significant deviation in behavioral patterns of all the experimental animals for the study period of 14 d. There were no mortality or toxic signs were observed in Arsenicum album-treated groups, which indicates that oral LD50 was found to be greater than 2000µl/100g body weight.

Biochemical parameters

Blood glucose, when compared to Group A (control) is increased in both groups B and C but statistically not significant ($p > 0.05$). When compared to Group A (control), there is no significant change in blood urea level in Groups B and C ($p > 0.05$). Serum creatinine is increased in groups B and C compared to Group A (control) but statistically not significant ($p > 0.05$). LDL cholesterol is increased in groups B and C compared to Group A (control) but statistically not significant ($p > 0.05$). HDL cholesterol is increased significantly in group B and C compared to group A ($p < 0.05$). Serum SGOT and SGPT levels are decreased significantly in groups B and C when compared to group A (Control) ($p < 0.05$). Biochemical parameters studied are shown in table 1.

Table 1: Biochemical parameters of different groups

Biochemical parameter	No. of animals (n) female wistar albino rats	Group A (control)	Group B (1000µl/100g)	Group C (2000µl/100g)
Blood glucose	6	91.15 \pm 17.61	95.00 \pm 5.657	154.6 \pm 20.65
Blood urea	6	47.25 \pm 9.405	47.10 \pm 13.44	43.75 \pm 3.606
S. Creatinine	6	0.295 \pm 0.077	0.75 \pm 0.516	0.34 \pm 0.00
LDL	6	8.10 \pm 5.94	9.15 \pm 1.202	9.15 \pm 0.2121
HDL	6	24.85 \pm 21.00	43.80 \pm 2.12*	45.25 \pm 1.485*
SGOT	6	566.8 \pm 71.77	199.0 \pm 45.75*	320.8 \pm 18.10*
SGPT	6	130.7 \pm 28.50	68.50 \pm 4.950*	63.10 \pm 1.556*

n=6, values are expressed as mean \pm SD, p value is indicated as * $p < 0.05$, ** $p < 0.01$, *** $p < 0.001$

Histopathological study

Light microscopic examination of sections of various organs like the liver, heart, spleen, lung, and kidney of control and treated groups were done and major changes were observed in the lung, kidney and liver. There are no histopathological changes in the heart, ovary, spleen, brain in all the three group.

Histological analysis of the liver sections of group A (Control) Wistar albino rats showed congested sinusoids and focal areas of haemorrhage, group B(1000µl/100g) showed congested hepatic sinusoids with periportal lymphoplasmacytic infiltrate and group C(2000µl/100g) showed severe congestion of hepatic sinusoids with extensive areas of haemorrhage and infarction, with focal periportal lymphocytes (fig. 1).

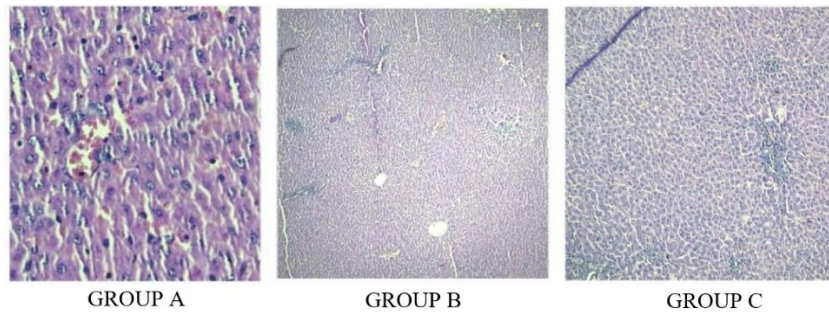


Fig. 1: histopathological slides of the liver of wistar albino rats

Histological analysis of the kidney of Group A (Control) is normal, while Group B (1000µl/100g) showed focal peritubular lymphoplasmacytic

infiltrate and Group C (2000µl/100g) showed extensive areas of hemorrhage and focal peritubular congestion (fig. 2).

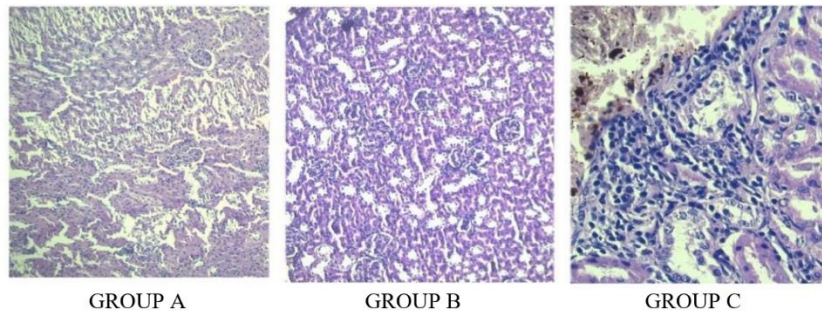


Fig. 2: Histopathological slides of the kidney of wistar albino rats

Histopathological examination of the lung of Group A (Control) showed an increase in alveolar spaces with focal areas showing intraalveolar hemorrhage and increase in alveolar macrophages, widening of alveolar septa with proliferation of lymphocytes and plasma cells while Group B (1000µl/100g) and C (2000µl/100g)

showed extensive areas of intraalveolar increase in peribronchial lymphocytic collections (fig. 3)

Additionally, macroscopic examination of organs of Group B and C revealed no abnormalities in the color or texture when compared with the organs of Group A (control).

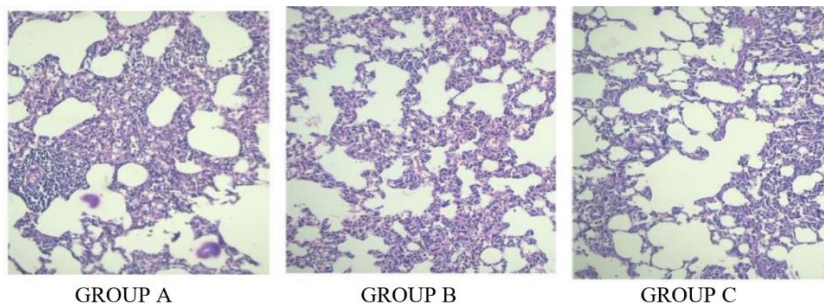


Fig. 3: Histopathological slides of the lung of wistar albino rats

DISCUSSION

Herbal medicines and their formulations have been considered to be safe and effective due to their negligible side effects. This presumption has greatly impacted the population's careless application of these mixtures. These formulations are used for extended periods without adequate dosage monitoring by professionals or knowledge of the potentially harmful implications of such prolonged use [16].

As a result, scientific understanding of oral toxicity is crucial since it will not only help determine the levels that may be utilized in the future but also detect any potential clinical symptoms that the pharmaceuticals under study may cause. Despite the pharmacological advantages of the Arsenicum album, there is a dearth of comprehensive information regarding the acute toxicity of

this medication. Therefore, using Wistar albino rats as an animal model, the current study was designed to assess and concentrate on the acute toxicity of the Arsenicum album. The OECD rules were followed in conducting these investigations [17].

The acute toxicity study serves as the foundation for classification and labeling, and it can offer preliminary insights into the drug's method of harmful action. It also aids in determining the dose of novel compounds in this animal study. The investigation involved giving the treatment groups oral doses of the chosen homeopathic medications up to 2000 µl/100g body weight. We looked at the fact that, up to this point, neither mortality nor appreciable changes in body weight were seen in the therapy groups. According to earlier findings, a person's body weight change is a crucial indicator for researching any harmful consequences on them.

Consequently, we designed the current study to look at how homeopathic medications affect body weight, biochemical analysis, and histopathological analysis. When compared to the normal control group, the study's behavioural parameters, such as eating, walking, and sleeping were also observed, and no abnormalities were discovered. Since the effects of homeopathic medicines on target organs and biochemical changes are typically not detectable in acute toxicity tests, sub-acute toxicity studies are useful for evaluating their impact. In clinical settings, biochemical measures serve as the primary diagnostic markers for analysing any aberrant findings.

In this investigation, biochemical markers such as blood glucose, blood urea, serum creatinine, LDL, HDL, SGOT, and SGPT were examined. The most important sign for researching the stage of diabetes or variations in energy metabolism is blood glucose. When comparing the blood glucose levels of the treatment groups to those of the normal control animals, no discernible alterations were seen, suggesting that Arsenicum album does not affect the metabolism of energy.

Serum liver function tests, of which SGOT and SGPT define the cellular integrity of the liver, provide information about the state of the liver. Since SGOT and SGPT are the main enzymes made mostly by liver cells, any change or abnormality in the liver will cause a rise or reduction in the amount of these enzymes in the serum. In our study, there is a drop in these serum enzymes, which indicates a hepatocellular abnormality. GFR is a measure of kidney function, while creatinine is a measure of glomerular filtration rate. There was no discernible difference in the values of the renal profile measures (blood urea nitrogen and creatinine) when compared to the controls.

Haematoxylin and eosin staining were used to accomplish the gross histology of the various organs. Group C displayed severe congestion of the hepatic sinusoids with extensive areas of haemorrhage and infarction, along with focal periportal lymphocytes. Histological analysis of the liver sections of group A Wistar albino rats revealed congested sinusoids and focal areas of haemorrhage. Group B showed congested hepatic sinusoids with periportal lymphoplasmacytic infiltrate. According to the results above, liver toxicity can be observed at dosages of 1000µl/100g and 2000µl/100g for Arsenicum album.

Group A kidney histologically appears normal, while Group B and Group C showed significant regions of bleeding and focal peritubular congestion accompanied by a focal peritubular lymphoplasmacytic infiltration. Based on the aforementioned results, kidney damage is caused by Arsenicum album at dosages of 1000µl/100g and 2000µl/100g. Group B (1000µl/100g) and C (2000µl/100g) showed extensive areas of intraalveolar haemorrhage increase in peri bronchial lymphocytic collections, while the histopathological examination of Group A's lung revealed an increase in alveolar spaces with focal areas showing intra alveolar hemorrhage and increase in alveolar macrophages, widening of alveolar septa with proliferation of lymphocytes and plasma cells (fig. 3).

The treatment groups' enhanced peribronchial lymphocytic collections suggest that the medication is protecting against lung infections. Every group's brain segment displayed a symmetric pattern in both the left and right hemispheres. Pyramidal cells are visible in the cortical areas. The cardiac myocyte architecture in the heart slice was normal; there was no necrosis, inflammatory or mononuclear cell infiltration. Follicles at different phases of development make up the histology of the ovaries. Regarding the administration of homeopathic drugs, there was no difference in the histology of the ovaries.

Although opinions on the usage of Arsenicum album during the COVID-19 epidemic are divided, the use of Arsenicum album was mostly motivated by fear. Previous research revealed that a higher dilution might be more effective while posing less of a risk [18].

CONCLUSION

Studies on the acute and subacute toxicity of the drug are necessary to assess its safety. Despite being a homeopathic remedy for fibrous lung tissue healing, our investigation into the effects of Arsenicum

album on Wistar albino rats showed that it also causes mild renal and hepatocellular damage. More comprehensive experimental research on the chronic toxicity study is needed to substantiate the findings.

ACKNOWLEDGMENT

Nil

FUNDING

This research was funded by Indian Council of Medical Research (ICMR)

AUTHORS CONTRIBUTIONS

Dr Bhuvaneshwari, Monisha S, Dr Sathiyaa Vinotha, Dr Velarul, Dr Vijayamathy and Dr Umamageswari were involved in conceptualization and methodology, Dr Bhuvaneshwari, Monisha S, Dr Sathiyaa Vinotha, Dr Velarul were involved in formal analysis and writing, Dr Karthikeyan was involved in investigations.

CONFLICTS OF INTERESTS

The authors declared there are no conflicts of interest

REFERENCES

1. Firenzuoli F, Gori L, Crupi A, Neri D. Flavonoids: risks or therapeutic opportunities? *Recenti Prog Med.* 2004 Jul 1;95(7-8):345-51. PMID [15303543](#).
2. Swayn international dictionary of homeopathy. Edinburgh: Churchill Livingstone; 2008.
3. Ernst E. Homeopathy: past present and future. *Br J Clin Pharmacol.* 1997;44(5):435-7. doi: [10.1046/j.1365-2125.1997.t01-1-00611.x](#), PMID [9384459](#).
4. Linde K, Clausius N, Ramirez G, Melchart D, Eitel F, Hedges LV. Are the clinical effects of homeopathy placebo effects? A meta-analysis of placebo-controlled trials. *Lancet.* 1997 Sep 20;350(9081):834-43. doi: [10.1016/s0140-6736\(97\)02293-9](#), PMID [9310601](#).
5. Tillu G, Chaturvedi S, Chopra A, Patwardhan B. Public health approach of ayurveda and yoga for COVID-19 prophylaxis. *J Altern Complement Med.* 2020 May 1;26(5):360-4. doi: [10.1089/acm.2020.0129](#), PMID [32310670](#).
6. Liu SY, Song JC, Mao HD, Zhao JB, Song Q, Expert Group of Heat Stroke Prevention and Treatment of the People's Liberation Army, and People's Liberation Army Professional Committee of Critical Care Medicine. Expert consensus on the diagnosis and treatment of heat stroke in China. *Mil Med Res.* 2020;7(1):1. doi: [10.1186/s40779-019-0229-2](#), PMID [31928528](#).
7. Guan WJ, Ni ZY, HU Y, Liang WH, OU CQ, HE JX. Clinical characteristics of coronavirus disease 2019 in China. *N Engl J Med.* 2020;382(18):1708-20. doi: [10.1056/NEJMoa2002032](#), PMID [32109013](#).
8. Jethani B, Gupta M, Wadhvani P, Thomas R, Balakrishnan T, Mathew G. Clinical characteristics and remedy profiles of patients with COVID-19: a retrospective cohort study. *Homeopathy.* 2021;110(2):86-93. doi: [10.1055/s-0040-1718584](#), PMID [33567460](#).
9. Velu V, Uthandakalaipandian R. Efficacy of microdoses potentized homeopathic drug arsenicum album induced by arsenic trioxide in zebrafish (*Danio rerio*) a FTIR study in gills. *Int J Pharm Pharm Sci.* 2016;9(1):48. doi: [10.22159/ijpps.2017v9i1.15314](#).
10. Samuel S, Kathirvel R, Jayavelu T, Chinnakkannu P. Protein oxidative damage in arsenic induced rat brain: influence of DL-α-lipoic acid. *Toxicol Lett.* 2005;155(1):27-34. doi: [10.1016/j.toxlet.2004.08.001](#), PMID [15585356](#).
11. Ives EC, Couchman IM, Reddy L. Therapeutic effect of arsenicum album on leukocytes. *Int J Mol Sci.* 2012;13(3):3979-87. doi: [10.3390/ijms13033979](#), PMID [22489193](#).
12. Variya BC, Bakrania AK, Madan P, Patel SS. Acute and 28 d repeated dose sub-acute toxicity study of gallic acid in albino mice. *Regul Toxicol Pharmacol.* 2019;101:71-8. doi: [10.1016/j.yrtph.2018.11.010](#).
13. Ekanayake CP, Thammitiyagodage MG, Padumadasa S, Seneviratne B, Padumadasa C, Abeysekera AM. Acute and

- subacute toxicity studies of the ethyl acetate soluble proanthocyanidins of the immature inflorescence of *Cocos nucifera* L. in female wistar rats. *BioMed Res Int*. 2019;2019:8428304. doi: [10.1155/2019/8428304](https://doi.org/10.1155/2019/8428304), PMID [31886260](https://pubmed.ncbi.nlm.nih.gov/31886260/).
14. Al Afifi NA, Alabsi AM, Bakri MM, Ramanathan A. Acute and sub-acute oral toxicity of dracaena cinnabari resin methanol extract in rats. *BMC Complement Altern Med*. 2018;18(1):50. doi: [10.1186/s12906-018-2110-3](https://doi.org/10.1186/s12906-018-2110-3), PMID [29402248](https://pubmed.ncbi.nlm.nih.gov/29402248/).
 15. Bhushan B, Sardana S, Bansal G. Acute and sub-acute toxicity study of *Clerodendrum inerme* *Jasminum mesnyi* hance and *callistemon citrinus*. *J Acute Dis*. 2014;3(4):324-7. doi: [10.1016/S2221-6189\(14\)60069-X](https://doi.org/10.1016/S2221-6189(14)60069-X).
 16. Ben Arye E, Samuels N, Goldstein LH, Mutafoğlu K, Omran S, Schiff E. Potential risks associated with traditional herbal medicine use in cancer care: a study of Middle Eastern oncology health care professionals. *Cancer*. 2016;122(4):598-610. doi: [10.1002/cncr.29796](https://doi.org/10.1002/cncr.29796), PMID [26599199](https://pubmed.ncbi.nlm.nih.gov/26599199/).
 17. Singh S, Kalra P, Karwasra R, Khurana A, Manchanda R, Gupta Y. Safety studies of homoeopathic drugs in acute sub-acute and chronic toxicity in rats. *Indian J Res Homoeopathy*. 2017;11(1):48-57. doi: [10.4103/ijrh.ijrh_68_16](https://doi.org/10.4103/ijrh.ijrh_68_16).
 18. Panigrahy S, Dass D, Pandey SK, Sheena DM. Self medication for prevention and treatment of diseases during COVID-19 pandemic a cross-sectional survey in general population. *Int J Pharm Pharm Sci*. 2024;16(6):33-8. doi: [10.22159/ijpps.2024v16i6.50520](https://doi.org/10.22159/ijpps.2024v16i6.50520).